

Unraveling the role of IL-17 in lichen planus: a comparative investigation of clinical variability and immunopathogenic pathways

Maja Tolušić Levak^{1,2}, Mirta Pauzar³, Vera Plužarić^{1,4}, Nika Franceschi⁵, Biljana Pauzar^{2,6}, Jasmina Rajc⁷, Marija Delaš Aždajić⁵, Martina Mihalj^{1,8} ✉

¹Department of Dermatology and Venereology, Osijek University Hospital, Osijek, Croatia. ²Department of Histology and Embryology, Faculty of Medicine, University of Osijek, Osijek, Croatia. ³Department of Physical Medicine and Rehabilitation, Osijek University Hospital, Osijek, Croatia. ⁴Department of Laboratory Medicine and Pharmacy, Faculty of Medicine, University of Osijek, Osijek, Croatia. ⁵Department of Dermatology and Venereology, Sestre Milosrdnice University Hospital Center, Zagreb, Croatia. ⁶Department of Clinical Cytology, Osijek University Hospital, Osijek, Croatia. ⁷Clinical Department of Pathology and Forensic Medicine, Osijek University Hospital, Osijek, Croatia. ⁸Department of Dermatology and Venereology, Faculty of Medicine, University of Osijek, Osijek, Croatia.

Abstract

Introduction: Lichen planus (LP) is a chronic T cell-mediated inflammatory disease affecting the skin and mucosa. Interleukin-17 (IL-17), a pro-inflammatory cytokine, has been implicated in LP pathogenesis, but its tissue-level expression across clinical variants remains underexplored. This study compares IL-17 expression in healthy skin and LP lesions and assesses variations based on clinical presentation.

Methods: This cross-sectional retrospective study included 20 LP skin samples and 10 healthy controls. The sample collection spanned a period of 10 years. IL-17 expression was assessed via immunohistochemistry and quantified using a modified Q score. Samples were categorized by mucosal involvement and lesion distribution. Statistical analysis was performed with the Mann-Whitney *U* test.

Results: IL-17 was absent in healthy skin but present in all LP samples. IL-17 expression was significantly higher in patients with both skin and oral mucosal involvement compared to those with cutaneous LP ($p = 0.003$). No significant difference was observed between generalized and localized LP.

Conclusions: The results indicate a distinct increase in IL-17 expression in LP lesions, particularly with mucosal involvement, supporting its role in LP pathogenesis. These findings suggest IL-17 as a potential biomarker and therapeutic target, warranting further investigation in larger cohorts.

Keywords: inflammatory dermatoses, lichen planus, interleukin-17, immunoexpression

Received: 21 April 2025 | Returned for modification: 20 May 2025 | Accepted: 24 May 2025

Introduction

Lichen planus (LP) is a chronic T cell-mediated autoimmune inflammatory disease primarily affecting the skin, adnexal structures, and mucosal surfaces (1). This multifactorial condition is thought to arise from a combination of various etiological factors, including viral infections (such as hepatitis C virus, human herpesvirus 6, and human papillomavirus), certain medications, and vaccines. Genetic predisposition plays a significant role, with familial cases representing approximately 10.7% of LP occurrences, predominantly associated with specific human leukocyte antigen (HLA) loci. These findings support the autoantigen theory of pathogenesis (2–6).

LP is thought to arise from a delayed-type hypersensitivity reaction, in which activated T cells release cytokines that recruit inflammatory cells and enhance cytotoxic responses (7). A key mediator in this process is interleukin (IL)-17, a pleiotropic pro-inflammatory cytokine primarily produced by helper T lymphocytes, as well as neutrophils, mast cells, and keratinocytes (7, 8). Elevated levels of IL-17 have been observed in both serum and tissue of individuals with LP, although the relationship between these compartments exhibits distinct patterns (8, 9). Serum IL-17 is thought to reflect systemic immune imbalance, whereas tissue IL-17 contributes to local inflammation through keratinocyte acti-

vation and subsequent chemokine production (8, 10). The IL-23/IL-17 signaling axis is implicated in both systemic and local immune responses, providing a rationale for the use of biologic therapies such as secukinumab, an anti-IL-17A monoclonal antibody, in treatment-resistant cases (9, 11). Whereas serum IL-17 serves as a potential biomarker of systemic immune activity, tissue IL-17 is more directly associated with the local immunopathogenesis of LP (8–12). These distinct yet interconnected pathways represent complementary therapeutic targets.

The objective of this study was to evaluate differences in the tissue expression of IL-17 between healthy skin and LP lesions. Furthermore, the study aimed to compare IL-17 expression in LP tissue samples according to clinical characteristics and lesion distribution.

Methods

The study was conducted as a cross-sectional analysis using retrospective data, approved by the Ethics Committee of the Faculty of Medicine at Josip Juraj Strossmayer University in Osijek (602-04/22-08/02; 2158-61-46-22-98). The sample collection spanned a period of 10 years, ensuring a comprehensive dataset representative of diverse clinical presentations over time.

A total of 20 skin lesion samples from patients with LP and 10

✉ Corresponding author: martina.mihalj@gmail.com

healthy skin samples were included in the study. Inclusion and exclusion criteria were established for sample selection. For the LP group, inclusion criteria comprised age over 18 years, histologically confirmed diagnosis of LP, and absence of other dermatological conditions. Exclusion criteria included age under 18 years, ambiguous histopathological findings, and the presence of any additional dermatological comorbidities. For the healthy control group, inclusion criteria were age over 18 years and the absence of dermatological diseases both clinically and histologically, whereas exclusion criteria included age under 18 years and any diagnosed dermatological disease. All samples were obtained from the archives of the Clinical Institute for Pathology and Forensic Medicine.

Clinical data on LP patients, including demographic details, dermatological status, histopathological findings, and disease history, were collected from the archives of the Institute of Dermatology and Venereology.

The LP samples were categorized based on clinical presentation and lesion distribution. Eight samples were from patients with both cutaneous and oral mucosal involvement, and 12 samples were from patients with cutaneous-only LP. Regarding disease distribution, 10 samples were obtained from patients with generalized LP (affecting three or more body regions), and the remaining 10 samples were from patients with localized LP (involving up to two body regions).

IL-17 protein expression in tissue samples was assessed using immunohistochemical (IHC) analysis of skin samples. IHC analysis was performed on tissue samples fixed in 10% neutral formalin, embedded in paraffin, and sectioned into 3 to 5 µm slices using a microtome. The sections were then mounted on adhesive glass slides, deparaffinized, and rehydrated. To block endogenous peroxidase activity, the sections were treated with 0.3% hydrogen peroxide, followed by epitope exposure (antigen retrieval) using citrate buffer (pH 6.0) and microwave heating for approximately 5 minutes. The primary antibody (IL-17 Primary antibody, Abnova LTD, Cambridge, UK) was applied to the preparations and incubated overnight at 4 °C. After washing with phosphate-buffered saline (pH 7.4), the appropriate secondary antibody was applied. Subsequently, after washing, a streptavidin–horseradish peroxidase (Streptavidin-HRP, Vector Laboratories, Newark, USA)

conjugate was applied, followed by 3,3'-diaminobenzidine solution (DAB Peroxidase Substrate Kit, Vector Laboratories, Newark, USA) to visualize staining. The sections were counterstained with hematoxylin and dehydrated. For quality control, colon cancer tissue was used as a positive control, and skin tissue without primary antibody application served as a negative control. The analysis was performed in the Histology Laboratory of the Faculty of Medicine in Osijek. The preparations obtained were analyzed and photographed with an Olympus® (C-5050) digital camera, connected to an Olympus® (BX-50) microscope, using the QuickPHOTO Pro computer program. The presence, proportion, and signal intensity of IL-17 protein expression was assessed in each sample using histomorphological data. A modified “Quick score” (Q score) method of analyzing immunohistochemical preparations was used for histomorphological analysis (13, 14).

Categorical data were presented as absolute and relative frequencies. The Shapiro–Wilk test was used to assess the normality of numerical data distribution. Due to the nonnormal distribution and small sample size, data were described using the median and interquartile range limits. The Mann–Whitney *U* test was used to compare differences based on lesion localization and mucosal involvement, and results were expressed as the Hodges–Lehmann median difference and the corresponding 95% confidence interval. All *p* values were two-sided and statistical significance was set at alpha = 0.05. A statistical program was used for data analysis, MedCalc® Statistical Software version 20.100 (MedCalc Software Ltd, Ostend, Belgium).

Results

The study analyzed 30 skin samples, of which 10 (33.3%) were healthy skin samples, and twenty (66.7%) were skin affected by LP. No IL-17 expression was detected in the healthy skin samples, whereas all LP samples exhibited IL-17 expression. In the LP group, the median Q score was 4, with a range of 2 to 6 (Table 1). The immunohistochemical signal for IL-17 protein was observed as brown staining in the cytoplasm of keratinocytes and dermal cells (Fig. 1).

Among the 20 LP samples, eight (40%) exhibited both skin and oral mucosal involvement. In this subgroup, the majority of sam-

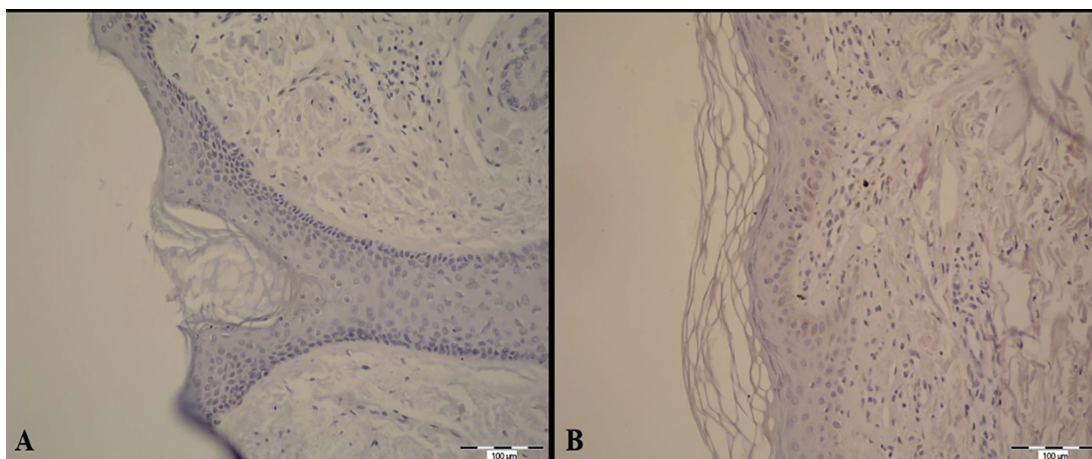


Figure 1 | (A) Interleukin-17 protein expression in healthy skin samples and (B) lichen planus skin samples. Scale bar: 100 µm.

Table 1 | Q score differences between groups.

Q score	Median (interquartile range)		Difference (95% reliability span)	<i>p</i> *
	Healthy skin	Lichen planus		
0		4 (3–5)	4 (3–5)	< 0.001

*Mann–Whitney *U* test.

ples had a Q score of 5 or 6. Conversely, in the samples in which the mucosa was unaffected, the Q score was predominantly 3 or 4 (Fig. 2). IL-17 protein expression was significantly higher in skin samples from patients with both skin and mucosal involvement compared to those with only cutaneous disease (Mann–Whitney *U* test, $p = 0.003$; Table 2). The IL-17 immunohistochemical signal was observed in the cytoplasm of keratinocytes and dermal cells (Fig. 3).

Based on lesion distribution, 10 (50%) patients had a generalized form of LP, and 10 had a localized form. In the generalized LP group, 3 out of 10 (30%) samples had a Q score of 3, and 4 out of 10 (40%) had a Q score of 5. In the localized LP group, 3 out of 10 samples (30%) had a Q score of 3 or 4 (Fig. 4). No statistically significant difference in IL-17 expression was observed concerning the distribution of LP skin lesions (Table 3).

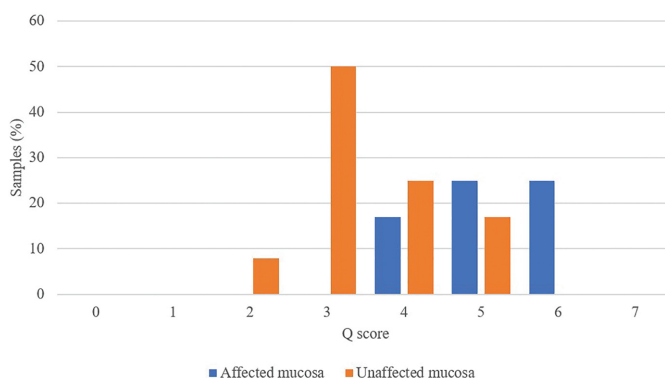


Figure 2 | Distribution of samples according to Q score and mucosal involvement.

Discussion

IL-17 is a pro-inflammatory cytokine predominantly secreted by helper T lymphocytes, although it is also produced in smaller amounts by other immune cells and epithelial cells, including keratinocytes (7, 8, 15). For over a decade, IL-17 inhibitors have been used in the treatment of psoriasis, an autoimmune inflammatory skin disease. Since LP is also classified as an inflammatory skin disorder, recent studies have investigated the role of IL-17 in its pathogenesis, suggesting that it may play a significant role in the disease process. However, its precise contribution to the pathophysiology and etiopathogenesis of LP remains poorly understood.

This study aimed to assess IL-17 expression in healthy skin samples compared to skin affected by LP, as well as to examine

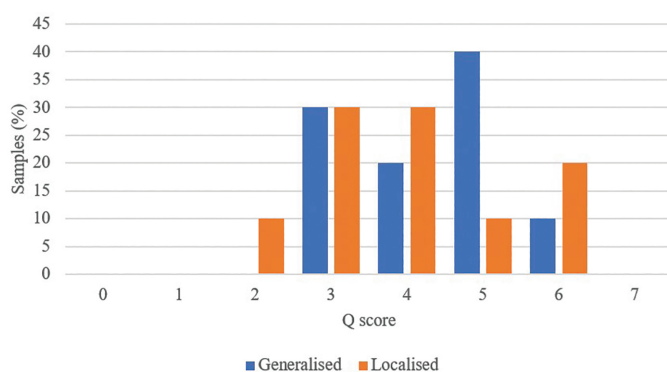


Figure 4 | Distribution of samples according to Q score and distribution of clinical changes.

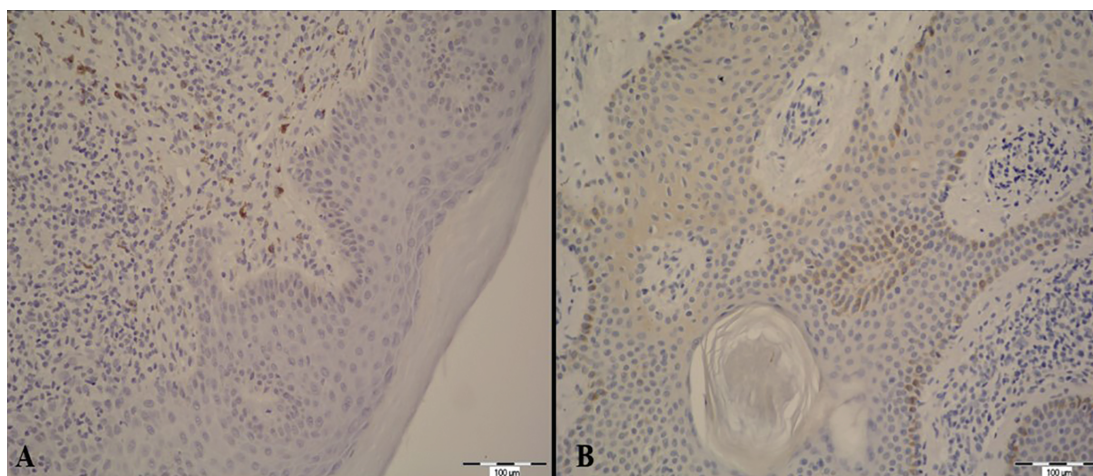


Figure 3 | (A) Interleukin-17 protein expression in skin samples from patients with only skin lesions and (B) skin samples from patients with lesions on both skin and oral mucosa. Scale bar: 100 µm.

Table 2 | Q score differences between lichen planus samples, depending on mucosal involvement.

	Median (interquartile range)		Difference (95% reliability span)	<i>p</i> *
	Affected mucosa (n = 8)	Unaffected mucosa (n = 12)		
Q score	5 (3–6)	3 (3–4)	–2 (–3 to –1)	0.003

*Mann–Whitney *U* test.

Table 3 | Expression of interleukin-17 concerning the distribution of lichen planus skin lesions.

	Median (interquartile range)		Difference (95% reliability span)	<i>p</i> *
	Generalized (n = 8)	Localized (n = 12)		
Q score	4.5 (3–5)	4 (3–5)	0 (–2 to 1)	0.56

*Mann–Whitney *U* test.

potential differences in IL-17 expression across various clinical forms and lesion distributions. The results showed that IL-17 was absent in healthy skin but was present in all LP samples. A statistically significant difference in IL-17 expression was observed between patients with both cutaneous and oral mucosal involvement versus those with cutaneous-only lesions. This finding is partially consistent with studies by Mahmoud et al. and Husein-ElAhmed and Steinhoff (15, 16), which also noted increased IL-17 expression in patients with both skin and mucosal lesions.

In the study by Mahmoud et al., no statistically significant difference in IL-17 expression was observed in skin samples between patients with cutaneous-only lesions and those with both skin and mucosal involvement. However, serum IL-17 levels were notably higher in patients with both skin and mucosal lesions compared to those with only cutaneous involvement (15). Similarly, a meta-analysis by Husein-ElAhmed and Steinhoff reviewed available studies to date and found that most studies reported higher IL-17 expression in tissue samples from patients with both skin and mucosal lesions compared to those with cutaneous-only disease (16). When comparing IL-17 expression in skin samples from patients with localized and generalized forms, no statistically significant difference was observed.

This result aligns with findings from Żychowska et al., who also reported no statistically significant differences in IL-17 expression in both tissue and serum samples of LP patients with different

clinical distribution of skin lesions (8)

Although the sample size in this study was relatively small, the findings align with previous research in the field. Due to the retrospective design of the study and the nature of available archived samples, serum IL-17 levels could not be assessed. As a result, it was not possible to correlate tissue expression of IL-17 with systemic immune activity. Future prospective studies with larger cohorts and simultaneous analysis of serum and tissue samples are warranted to provide a more comprehensive understanding of IL-17's role in the pathogenesis of LP. A more refined understanding of IL-17's involvement in the etiopathogenesis of LP may facilitate the development of future clinical trials investigating the therapeutic potential of IL-17 inhibitors already approved for use in other inflammatory dermatoses. To date, only one large clinical trial (Prelude), sponsored by the manufacturer, has evaluated the efficacy of the IL-17 inhibitor secukinumab in patients with LP, reporting promising results (17).

Conclusions

Independently conducted large-scale clinical trials are warranted to further assess the efficacy and safety of IL-17 inhibition in LP. Expanding the range of available treatment options could ultimately lead to more effective therapies for patients with severe or treatment-refractory forms.

References

- Bolognia JL, Schaffer JV, Cerroni L. *Dermatology*. 4th ed. London: Elsevier Health Sciences; 2017.
- Tziotziou C, Lee JYW, Brier T, Saito R, Hsu CK, Bhargava K, et al. Lichen planus and lichenoid dermatoses: clinical overview and molecular basis. *J Am Acad Dermatol*. 2018;79:789–804.
- Cassol-Spanemberg J, Blanco-Carrión A, Rodríguez-de Rivera-Campillo ME, Estrugo-Devesa A, Jané-Salas E, López-López J. Cutaneous, genital and oral lichen planus: a descriptive study of 274 patients. *Med Oral Patol Oral Cir Bucal*. 2019;24:e1–e7.
- Lodi G, Pellicano R, Carrozzo M. Hepatitis C virus infection and lichen planus: a systematic review with meta-analysis. *Oral Dis*. 2010;16:601–12.
- Boch K, Langan EA, Kridin K, Zillikens D, Ludwig RJ, Bieber K. Lichen planus. *Front Med (Lausanne)*. 2021;8:737813.
- Qian H, Jiao L, Fan Z, Wang L, Liu B, Miao G. Analysis of immunologic function changes in lichen planus after clinical treatment. *Med Sci Monit*. 2018;24:8716–21.
- Bechara R, McGeachy MJ, Gaffen SL. The metabolism-modulating activity of IL-17 signaling in health and disease. *J Exp Med*. 2021;218:e20202065.
- Żychowska M, Batycka-Baran A, Baran W. Increased serum level and high tissue immunoeexpression of interleukin 17 in cutaneous lichen planus: a novel therapeutic target for recalcitrant cases? *Dis Markers*. 2020;2020:6521274.
- Agha-Hosseini F, Moosavi MS, Bahrami H. A systematic review of interleukin-17 in oral lichen planus: from etiopathogenesis to treatment. *Clin Med Res*. 2023;21:201–15.
- Otlewska-Szpotowicz A, Baran W, Woźniak Z, Szepietowski J, Batycka-Baran A. Increased expression of psoriasis (S100A7) and interleukin 17 (IL-17) in lesional skin in lichen planopilaris. *Adv Dermatol Allergol*. 2024;41:364–71.
- Jahan A, Asaduzzaman ATM, Tarafder S, Uddin MJ. Association of serum IL-23 and IL-17A level with lichen planus: a case-control study *JBAD* 2024;04:45–52.
- Shaker O, Hassan AS. Possible role of interleukin-17 in the pathogenesis of lichen planus. *Br J Dermatol*. 2012;166:1367–8.
- Tolušić Levak M, Mihalj M, Koprivčić I, Lovrić I, Novak S, Bijelić N, et al. Differential expression of TFF genes and proteins in breast tumors. *Acta Clin Croat*. 2018;57:264–77.
- Detre S, Saclani Jotti G, Dowsett M. A “quickscore” method for immunohistochemical semiquantitation: validation for oestrogen receptor in breast carcinomas. *J Clin Pathol*. 1995;48:876–8.
- Mahmoud SB, Anwar MK, Shaker OG, El Sharkawy DA. Possible relation between vitamin D and interleukin-17 in the pathogenesis of lichen planus. *Dermatology*. 2021;237:896–901.
- Husein-ElAhmed H, Steinhoff M. Potential role of interleukin-17 in the pathogenesis of oral lichen planus: a systematic review with META-analysis. *J Eur Acad Dermatol Venereol*. 2022;36:1735–44.
- Passeron T, Reinhardt M, Ehst B, Weiss J, Sluzevich J, Sticherling M, et al. Secukinumab in adult patients with lichen planus: efficacy and safety results from the randomized placebo-controlled proof-of-concept PRELUDE study. *Br J Dermatol*. 2024;191:680–90.