

# Pbserum Specific Acne Scars®: a cutting-edge approach utilizing triple enzymatic synergy combined with microneedling for post-acne scar repair

Melania Batistella<sup>1,2</sup>, Erick Santaella<sup>3</sup>, Sandra Oliveira<sup>4</sup>, Claudia Maan<sup>5,6</sup>, Valeria Kopytina<sup>7</sup>, Jorge López Berroa<sup>7</sup>✉

<sup>1</sup>Me to Me Clinic, Fuggi, Italy. <sup>2</sup>Sapienza University of Rome, Rome, Italy. <sup>3</sup>ERSA Medical Aesthetics, Monterrey, Mexico. <sup>4</sup>Private Clinic (Clínica Dr. Sandra de Oliveira), Madrid, Spain. <sup>5</sup>Cosmetic Medicine Clinic (Clínica de Medicina Estética), Madrid, Spain. <sup>6</sup>MG Clinic, Madrid, Spain. <sup>7</sup>Proteos Biotech Laboratories, Madrid, Spain.

## Abstract

**Introduction:** The integration of active ingredients into scientifically backed formulations is an innovative approach to remodeling post-acne atrophic scars, stimulating regenerative processes. Microneedling, a minimally invasive procedure, promotes collagen production and enhances skin penetration of cosmeceutical products such as Pbserum Specific Acne Scars®, which combines collagenases G and H with hyaluronate r-lyase and other ingredients, including allantoin, zinc sulfate, vitamin A, vitamin B<sub>3</sub>, niacinamide, and melatonin. These components modulate inflammation, fibrosis, oxidative stress, and aging. This study assesses the efficacy and safety of treatment for ameliorating atrophic acne scars.

**Methods:** Twenty-nine patients were treated with Pbserum Specific Acne Scars® applied by microneedling for 4 months in four sessions on the middle or lower third of the face and/or periocular area. The scar size (according to EvaFace® analysis), deep skin hydration (measured with a Moisturemeter® D device), severity (assessed using the *échelle d'évaluation clinique des cicatrices d'acne* and Goodman and Baron scales), clinical efficacy (evaluated using Global Aesthetic Improvement Scale), quality of life (measured using Facial Acne Scar Quality of Life questionnaire), and subject satisfaction were analyzed.

**Results:** Significant improvements were observed in all parameters evaluated, especially after four applications, demonstrating clinical efficacy. Patient satisfaction levels were notably high.

**Conclusions:** The treatment significantly improved skin texture and scar appearance after four applications over a period of 4 months.

**Keywords:** post-acne atrophic scars, collagenase, lyase, microneedling

Received: 23 March 2025 | Returned for modification: 30 April 2025 | Accepted: 30 May 2025

## Introduction

Post-acne atrophic scars are a prevalent and challenging dermatological concern that significantly impacts patients' quality of life, self-esteem, and psychological and emotional wellbeing. The significance of addressing acne scars is underscored by the emotional distress often associated with visible scarring, which can contribute to anxiety, depression, and social withdrawal (1, 2). Therefore, effective treatment is not merely a cosmetic concern but also a crucial aspect of mental healthcare.

Despite substantial advances in dermatological science, these scars remain a persistent reminder of past inflammatory acne and pose a therapeutic challenge due to the complexity of their pathophysiology. Inflammation of affected pilosebaceous units leads to the extravasation of follicular material into the dermis (3). This inflammatory response triggers oxidative stress by increasing reactive oxygen species (ROS) levels, leading to the activation of the nuclear factor kappa-light-chain-enhancer of activated B cells (NF-κB) signaling cascade. This pathway upregulates downstream target genes, including pro-inflammatory cytokines, C-reactive protein (CRP), adhesion molecules, inducible nitric oxide synthase (iNOS), cyclooxygenase-2 (COX-2), fibrinogen, and tissue factor. These molecules and cytokines recruit immune cells such as neutrophils, monocytes, and macrophages, as well as platelets, further amplifying the inflammatory response, disrupting the healing process, and promoting scar formation (4).

Characterized by permanent depressions in the skin surface caused by collagen degradation, post-acne atrophic scars can vary widely in depth, morphology, and distribution, requiring tailored and effective treatment approaches. Current treatment modalities, including chemical peels, microneedling, silicone gels, cryotherapy, laser therapy, and soft tissue augmentation, have shown promising results; however, limitations such as inconsistent outcomes, patient variability, and potential side effects underscore the need for continued innovation (1). As the understanding of scar biology evolves, there is a growing recognition of the importance of regenerative medicine, targeted therapies, and minimally invasive techniques in advancing scar management.

Microneedling-applied cosmetic products have gained prominence as a therapeutic approach for treating post-acne atrophic scars, harnessing the skin's natural healing process to improve appearance and texture. Microneedling is a minimally invasive technique that employs fine needles to create controlled micro-injuries in the epidermis, stimulating collagen and elastin production while enhancing the absorption of topical agents (5). It generates microscopic aqueous pores through which drugs diffuse to the dermal microcirculation (6). Furthermore, the controlled micro-injury stimulates the release of growth factors and cytokines, which play vital roles in healing, further enhancing the overall appearance and texture of the skin (7). Microneedling has demonstrated efficacy in improving various types of atrophic acne scars, including ice pick, rolling, and boxcar scars, showing enhanced outcomes

✉ Corresponding author: jorge.lopez@proteosbiotech.com

when combined with bioactive compounds (8–10).

The depth of needle penetration is crucial and should vary depending on the treatment area and the specific skin condition being addressed. In the delicate periocular region, shallower needle depths are typically employed, whereas for other facial regions, such as the cheeks or areas with thicker skin, deeper needle penetrations may be appropriate. This allows the administration of the desired product in the epidermis without touching the vascular bed, thus reducing the pain and adverse effects associated with other treatments such as filling the area with hyaluronic acid or laser (11).

As a result, microneedling has emerged as a notable intervention, with various clinical studies reporting significant improvements in scar appearance across diverse skin types (2). Integrating this technique with the synergistic action of bioactive compounds that promote the reduction of fibrotic tissue, modulate inflammation, or exert anti-oxidant properties can further improve the outcomes.

The reduction of fibrotic tissue can be achieved by degrading damaged collagen fibers within the extracellular matrix (ECM). Enzymes such as collagenases G and H target and degrade this damaged collagen, playing a vital role in facilitating cell migration and the development of new tissue. Hyaluronate lyase acts on hyaluronic acid, another key component of the ECM, breaking it down to support the healing process (12, 13).

This article explores a novel approach for treating post-acne atrophic scars, the cosmeceutical product Pbserum Specific Acne Scars®, based on enzymes and other compounds directed to reduce inflammation and oxidative stress, applied through the microneedling technique. This approach integrates recent advancements in dermatology and biotechnology to address unmet needs in this domain.

This study evaluates the efficacy and safety of this treatment on the improvement of appearance and reduction in size of atrophic acne scars. It contributes to the ongoing effort to enhance outcomes for individuals affected by acne scars, providing an innovative tool to regenerate the skin and improve the appearance of this condition, reducing adverse effects and pain compared to other techniques.

## Methods

### Study design

An open-label, before-and-after clinical study was conducted to evaluate the effects of the product Pbserum Specific Acne Scars® when administered via the microneedling technique.

### Product characteristics

Pbserum Specific Acne Scars® (Proteos Biotech, S.L., Albacete, Spain) is a cosmetic product for microneedling administration, not yet marketed, based on a combination of collagenases G and H (from *Clostridium histolyticum*, patented as PB220, Proteos Biotech, S.L., Albacete, Spain) and hyaluronate r-lyase (patented as PB72K, Proteos Biotech, S.L., Albacete, Spain) enzymes. Additional active ingredients include allantoin, zinc sulfate, vitamin A, vitamin B3, niacinamide, and melatonin.

The product is presented in vials (one vial of lyophilized powder and one vial of solution for reconstitution) and is administered reconstituted with a Dermapen 4® microneedling pen device

(DermapenWorld, Belrose, Australia), with a circular head of 16 microneedles at a depth of 1 mm depth on the middle and lower third of the face, and 0.5 mm in the peri-orbicular area, allowing treatment only in the epidermis. Each box contains four vials of lyophilized powder and four vials of solution for reconstitution. The reconstituted vial has a final volume of 5 ml.

### Participant demographics and clinical procedure

Twenty-nine patients were subjected to treatment with the product for 4 months (38 patients initially enrolled, with nine dropouts). All dropouts were due to personal reasons, scheduling conflicts, or lack of interest, and they were unrelated to adverse events or the treatment itself.

Baseline measurements were recorded on day 0 (Do), followed by the first application of the product on the same day. The second to fourth treatment sessions were performed 30, 60, and 90 days after the first session (D30, D60, and D90). At days 67 and 90 + 30 (D60 + 7 and D120)—1 week and 1 month after the third and fourth applications, respectively—skin measures were taken (Supplementary Fig. 1). Therefore, application was performed in four separate sessions, on the middle and/or lower third of the face and/or periocular area, separated by  $30 \pm 6$  days (Do, D30, D60, and D90).

No concomitant treatments were prescribed together with Pbserum Specific Acne Scars® application. Both the research team and the patient were aware of the product content. The study was carried out at Zurko Research S.L., Cosmetic Medicine Clinic (*Clínica de Medicina Estética*), and MG Clinic (Madrid, Spain).

All information and data collected from each subject during the research were kept strictly confidential. Inclusion of patients in the research was voluntary. Good clinical practice guidelines (ICH E6(R2) GCP) and appropriate procedures were followed at all times to ensure compliance with LOPD 2018 and Patient Autonomy Law 41/2002, Organic Law 1/1982 (on Civil Protection of the Right to Honor, Personal and Family Privacy, and Self-Image), the General Data Protection Regulation (Regulation (EU) 2016/679 of the European Parliament and of the Council, of 27 April 2016), and Organic Law 3/2018, of 5 December (on the Protection of Personal Data and Guarantee of Digital Rights). Before inclusion in the study, patients received a subject information sheet, which explained the clinical study and its procedures following GCP standards (ICH 2016 R2). Then, an informed consent form was signed by every participant.

Inclusion criteria comprised patients of both sexes 18 to 55 years old with atrophic scars on the middle and/or lower third of the face and/or periocular area and with skin types I, II, III, or IV on the Fitzpatrick scale. An adequate level of understanding of the clinical study and voluntarily signing the informed consent form was also required. Exclusion criteria included pregnancy and breastfeeding.

### Application protocol

Before the product application session, the surface of the microneedling device was disinfected with 96% alcohol and a gauze pad, and the treatment area was cleaned with a cleansing gel, also removing any makeup or tinted cream. Thereafter, topical anesthetic cream was applied for 20 minutes with the area covered with plastic wrap. After removing the anesthetic cream with gauze pads, the area was disinfected with 1% chlorhexidine.

The lyophilized powder of the product was then reconstituted,

shaking until a homogeneous solution was achieved, with no visible granules or powder residue.

To proceed with the treatment, a new head was attached to the microneedling device and adjusted to a depth of 1 mm for the middle and lower third of the face, and to 0.5 mm for the periocular area, based on published recommendations (11).

The Dermapen® speed was set at level 3. To avoid accidental entry of the product into the eyes, gauze was placed over the eyes for the entire duration of the procedure.

The entire content of the reconstituted vial (5 ml) was applied in two rounds during the same session following the same mesh-pattern application, using 2.5 ml on each side, with 1.25 ml for each round. A gentle massage was performed after the final round of application.

Ten minutes after completing the treatment, the treated area was cleaned with saline solution, applying sunscreen with SPF 50+.

### Clinical measurements

The reduction in size of atrophic scars was measured with EvaFace® (EOTECH, Marcoussis, France) at the experimental time points (D0, D67, and D120). Deep skin hydration was measured with a Moisturemeter® D device (Delfin Technologies Ltd., Kuopio, Finland).

Two different quantitative scales were used to assess the severity of the scars. The *échelle d'évaluation clinique des cicatrices d'acne* (ECCA) scale assigns numerical values to each type of scar based on its size and depth, and the area affected. It consists of six items designed to easily and quickly assess the severity of acne scars with a global score (14). Goodman and Baron also developed a quantitative scale for post-acne atrophic scars using a scoring system based on their type and extent (15).

The values on the Goodman and Baron quantitative scale and ECCA scale (14) were analyzed at baseline (D0), 7 days after the third application (D67), and 30 days after the fourth application (D120). Other variables assessed 30 days after the fourth application (D120) were the clinical efficacy parameter of the Global Aesthetic Improvement Scale (GAIS) (16) and the subjective satisfaction survey of the patient (Supplementary Appendix 1). Finally, the Facial Acne Scar Quality of Life questionnaire (FASQoL; Supplementary Appendix 2) was completed at the beginning (D0) and end of the study (D120).

### Statistical analysis

Descriptive statistical analyses were performed on quantitative variables—including reduction in atrophic scar dimensions, deep skin hydration, the Goodman and Baron numerical scale, and the ECCA numerical scale—across the experimental time points (D0, D67, and D120). These analyses involved calculating the mean, standard deviation, and absolute variation from baseline (D0).

For nominal variables (FASQoL questionnaire, GAIS scale, and subjective satisfaction survey), data exhibiting a normal distribution were analyzed using linear mixed effects models where applicable; otherwise, a paired Student's *t*-test was employed to assess the treatment effect. In instances in which the data did not follow a normal distribution, the Wilcoxon signed-rank test for paired samples was utilized. A significance level of 0.05 (95% confidence interval) was established for all analyses. All statistical computations were conducted using GraphPad software version 8 (Insight

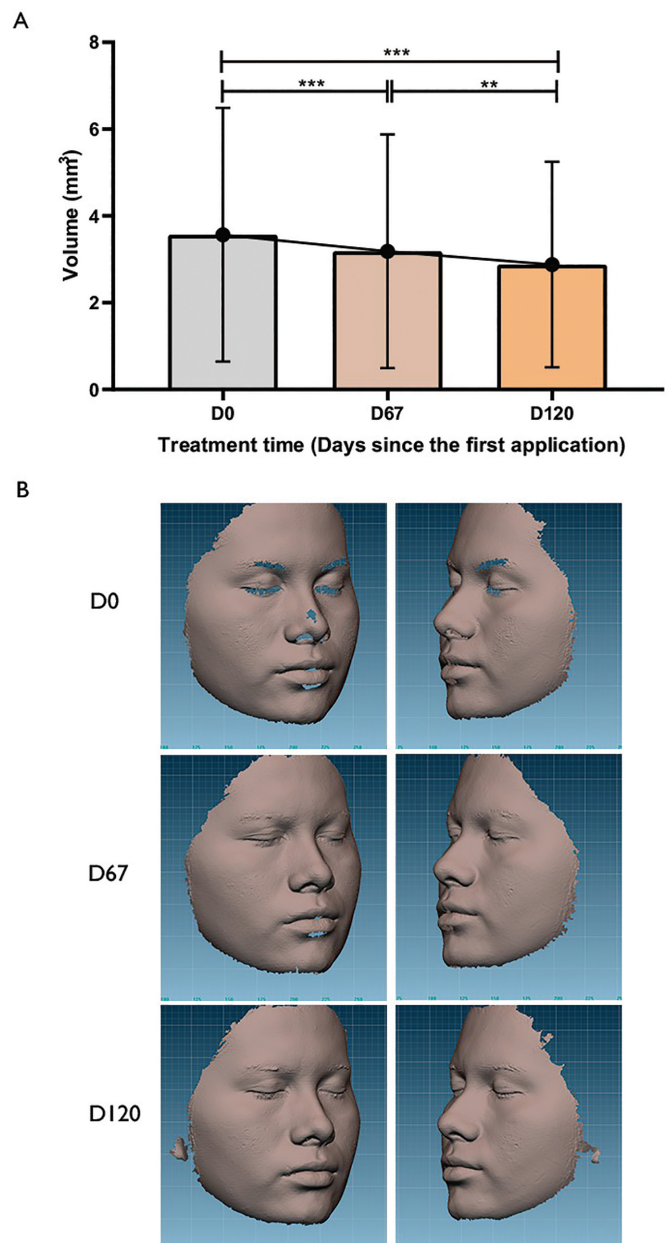
partners, New York, USA) and R software within the RStudio environment (R version 4.3.1).

## Results

The results were analyzed based on various complementary parameters, detailed below.

### Atrophic scar size

According to the EvaFace® analysis, after three applications of the product (D67), atrophic scar size significantly improves an average of 11% in relation to baseline ( $p = 0.0002$ ). This difference increases after four applications (D120), with a significant improvement of 19% of average in relation to baseline ( $p < 0.0001$ ). In fact, a significant improvement can also be observed between D67

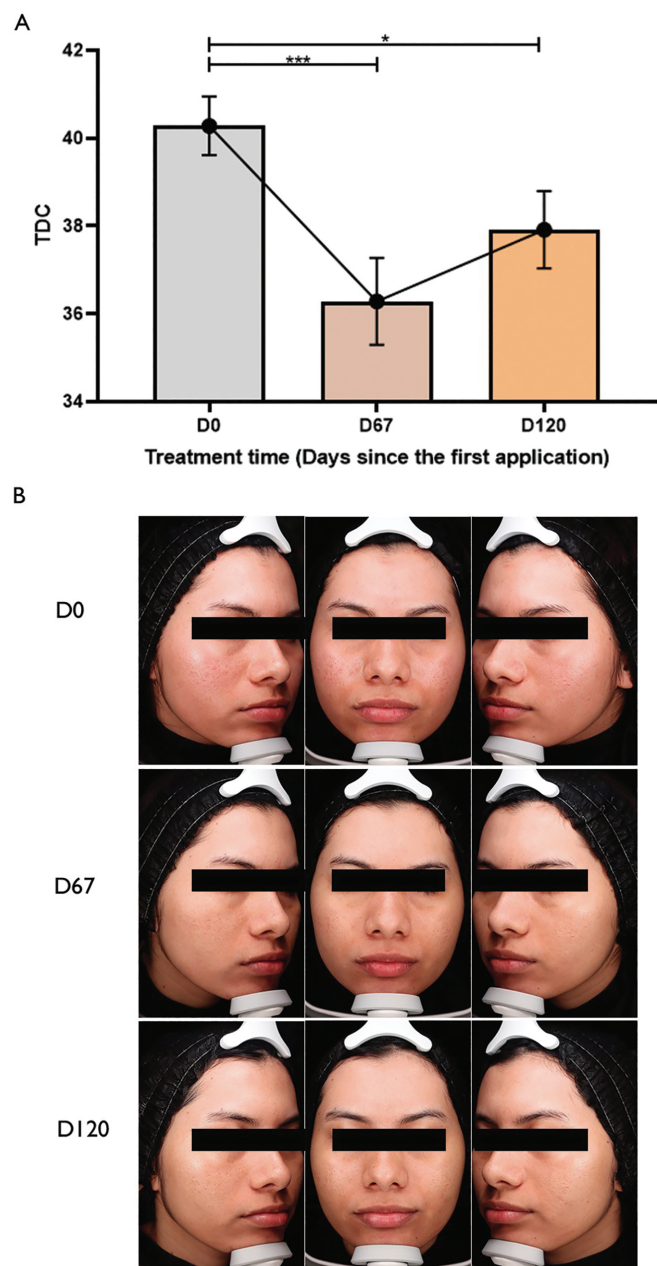


**Figure 1** | Evaluation of atrophic scars size with EvaFace®: (A) average volume, mm<sup>3</sup> ± SD at different experimental times (D0, D67, and D120;  $n = 29$ ). Percentage of absolute reduction with respect to D0 is 11% for D67 and 19% for D120 (data not shown). The Wilcoxon matched-pairs signed rank test shows significant differences among days of treatment (\*\* $p < 0.001$ ; \*\*\* $p < 0.0001$ ); (B) images taken with the EvaFace® system from a representative patient. D = day, SD = standard deviation.

and D120 ( $p = 0.0014$ ; Fig. 1). Moreover, 83% of patients showed atrophic scar size improvement at D67 and 97% at D120 (data not shown).

### Deep skin hydration

After three applications of the product (D67), deep skin hydration, measured with a Moisturemeter® D device, significantly decreases an average of 10% in relation to baseline ( $p = 0.0006$ ). After four applications of the product (D120), this parameter significantly decreases an average of 6% in relation to baseline ( $p = 0.038$ ; Fig. 2). In addition, 24% of patients showed deep skin hydration improvement at D67 and 38% at D120.



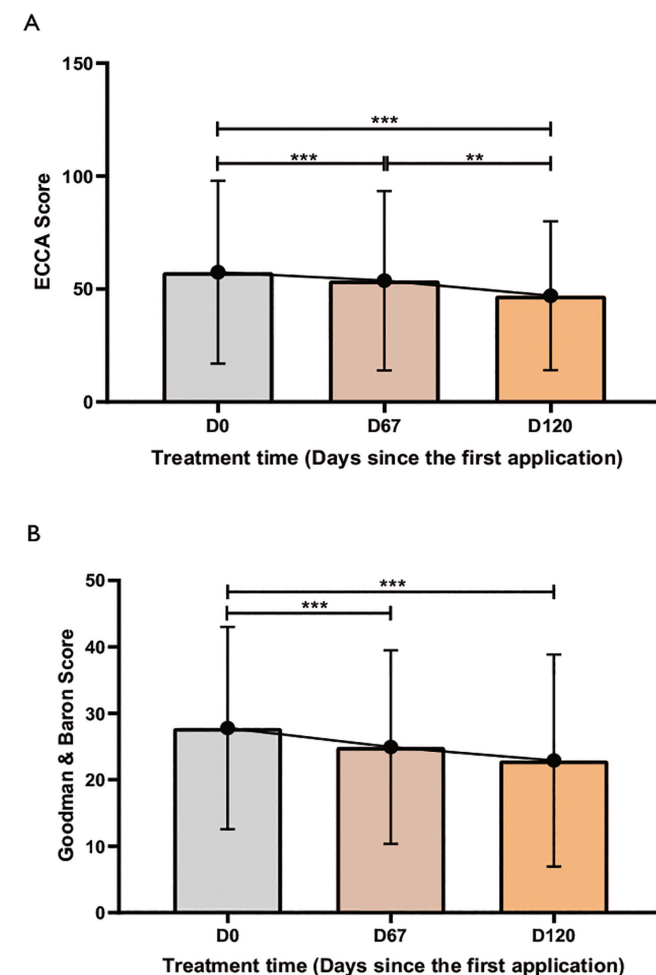
**Figure 2 |** Evaluation of deep skin hydration: (A) average measurements for TDC ± SEM obtained with Moisturemeter® D at different experimental times (D0, D67, and D120;  $n = 29$ ). Percentage of absolute reduction with respect to D0 is 10% for D67 and 6% for D120 (data not shown); a  $t$ -test showed significant differences among days of treatment ( $***p < 0.0001$ ;  $*p < 0.05$ ); (B) images taken with the VISIA® (Canfield, Scarborough, Maine, US) system from a representative patient. SEM = standard error of the mean, TDC = tissue dielectric constant, D = day.

### ECCA scale for atrophic scars

After three applications of the product (D67), the parameter on the ECCA scale significantly improves an average of 4% in relation to baseline ( $p < 0.0001$ ). Moreover, after four applications (D120), it significantly improves an average of 23% in relation to baseline ( $p < 0.0001$ ; Fig. 3A). Whereas 14% of patients showed improvement in the ECCA score at D67, the percentage increased to 69% at D120 (data not shown).

### Quantitative Goodman and Baron scale for atrophic scars

After three applications of the product (D67), the parameter on the quantitative Goodman and Baron scale for atrophic scars improved by an average of 6% in relation to baseline ( $p < 0.0001$ ; Fig. 3B). At this timepoint, 28% of patients showed an improvement in the Goodman and Baron score. After four applications of the product (D120), the improvement increased to an average of 32% compared to baseline ( $p < 0.0001$ ; Fig. 3B). At this timepoint, 86% of patients showed improvement.



**Figure 3 |** Quantitative evaluation of post-acne scars: (A) average measurements for the ECCA scale ± SD at different experimental times (D0, D67, and D120;  $n = 29$ ). Percentage of absolute reduction with respect to D0 is 4% for D67 and 23% for D120 (data not shown); (B) average measurements for the Goodman and Baron scale ± SD at different experimental times (D0, D67, and D120;  $n = 29$ ). Percentage of absolute reduction with respect to D0 is 6% for D67 and 32% for D120 (data not shown). A Wilcoxon matched-pairs signed rank test showed significant differences among days of treatment ( $**p < 0.001$ ;  $***p < 0.0001$ ). ECCA = échelle d'évaluation clinique des cicatrices d'acne, SD = standard deviation, D = day.

### GAIS Improvement Scale

The results for GAIS showed that 58.62% of the patients experienced progress categorized as “much improved” (17 patients), and the remaining patients demonstrated outcomes classified as “improved” (12 patients). Notably, no patients were classified under the categories of “no change,” “worse,” or “much worse.”

### FASQoL questionnaire

The FASQoL questionnaire was employed to analyze the impact of atrophic acne scars on patients’ daily life (Supplementary Appendix 2). After four applications of the product, patients felt that their quality of life had improved in every aspect evaluated, as follows: feeling less self-conscious around people because of the pits or holes on their face; feeling more attractive despite the marks; being less bothered by the pits or holes; worrying less about whether the marks or holes might go away; feeling less sadness related to the pits or holes; experiencing fewer negative comments from others about their appearance; being more comfortable going out with friends or family without avoiding social situations; feeling less compelled to hide the marks or holes; noticing an improvement in how the marks or holes affected their relationships with others, such as friends, family, or partners; and reporting fewer negative impacts on their participation in work or school due to the marks or holes on their face.

### Satisfaction questionnaire

Patients were asked about their experience with the treatment (Supplementary Appendix 1). During the product application, 6.90% of them experienced an absence of discomfort, 31.03% slight discomfort, 48.28% moderate discomfort, and 13.79% severe discomfort.

In addition, patients were asked to rate their perception of the product’s fragrance; 17.24% of them considered it very pleasant, 17.24% considered it somewhat pleasant, 62.07% were indifferent, and 3.45% considered it very unpleasant. When the patients were asked whether they would recommend this treatment to other patients, 86.21% answered that they would recommend it.

Patients were also asked whether they were satisfied with the final result, and 75.86% of the patients answered positively. In fact, 89.66% of the patients would opt for this treatment over another if the price were affordable.

Regarding the improvement achieved, 79.31% of the patients agreed that it was significant. Moreover, 100% of the patients did not notice any adverse effect during the study.

### Adverse effects

No serious adverse events and no product deficiencies were registered during the investigation. Although 29 patients experienced erythema and petechiae, all of the reported adverse events fall within the expected range associated with the microneedling technique.

### Discussion

The increasing prevalence of acne and its lasting effects has led to a growing interest in effective treatment modalities. Treating atrophic acne scars presents a significant challenge for dermatolo-

gists. Various treatment options have been developed to improve the appearance of acne scars, ranging from topical treatments such as retinoids and hydroquinone to professional procedures such as chemical peels, dermabrasion, subcision, and laser methods (17). Although topical treatments can provide modest improvements, professional interventions are often required for more significant results. However, each technique has its own set of limitations, and the overall results are often not fully satisfactory when considering the cost, time investment, and potential complications. For instance, fractional laser treatment is associated with intense pain and a lengthy recovery period, and it is not suitable for active acne due to the risk of post-inflammatory hyperpigmentation (18).

In recent years, the emergence of recombinant enzymatic therapies has added new dimensions to the treatment of skin conditions, including atrophic acne scars. Unlike traditional methods, recombinant enzymes have shown promising results by specifically targeting the ECM, promoting tissue remodeling with minimal invasiveness. Products such as Pbserum Smartker Equilibrium Professional® and Extreme Firmness Professional® (19, 20), which combine keratinase and collagenase, have demonstrated significant efficacy in improving skin tone, firmness, and elasticity after only 28 days of topical application, without adverse effects. These products primarily address signs of cutaneous aging, but the underlying enzymatic mechanisms overlap with those required to remodel fibrotic scar tissue (19, 20).

Controversies in acne scar treatment often revolve around the efficacy and safety of the methods available, as well as the importance of provider expertise in achieving optimal outcomes. Although it requires multiple sessions to achieve improvement, microneedling is minimally invasive and generally well tolerated by the patient, resulting in a very attractive approach for the treatment of this condition (11). In addition to the intrinsic improvement in acne scars induced by the microneedling technique, the use of specific products that promote the reduction of scar tissue and its replacement with tissue containing fewer fibrotic components can further enhance the outcomes (9, 12).

Although these enzyme-based treatments have been applied successfully to conditions such as sagging skin, hyperpigmentation, and hypertrophic scars, the integration of these enzymatic components within a microneedling delivery system, as presented in this study, offers an enhanced modality. Microneedling increases transdermal penetration and potentiates the localized action of these enzymes, likely contributing to the improvements observed across clinical scales and patient-reported outcomes in our trial (6). The microneedling technique can be applied using various tools. This study employs the Dermapen® device because recent evidence supports its efficacy and good results compared to other techniques. The clinical efficacy of dermaroller versus Dermapen® has been recently analyzed in the management of post-acne atrophic scars (21). The results showed that dermaroller sessions are quicker because they can cover a larger area of skin in less time. However, they tend to cause more discomfort and bleeding during the procedure compared to the Dermapen®. In addition, post-treatment effects such as redness (erythema) and swelling (edema) are generally more pronounced following the use of a dermaroller than with a Dermapen® (21).

Therefore, this study incorporates the use of a microneedling-applied product composed of collagenase (G and H) and hyaluronate lyase enzymes, and other active agents such as allantoin, zinc sulfate, vitamin A, vitamin B3, niacinamide, and melatonin.

The properties of collagenases G and H to improve scarring are

well known. These enzymes specifically break down damaged collagen fibers in the ECM, promoting cellular migration and new tissue formation (12). Recombinant collagenases such as PB220 provide more complete collagenolysis than their human analogues by breaking multiple points of the triple helix, promoting not only degradation of dysfunctional collagen but also stimulation of fibroblast activity and neof ormation of functional ECM components (22). Moreover, hyaluronate lyase degrades hyaluronic acid, another major component of the ECM (13).

Allantoin has recently been used in multiple products to improve scar appearance (23–25). Allantoin has demonstrated wound-healing properties, along with anti-irritation, hydration, keratolytic effects, necrotic tissue recovery, and epithelializing benefits (26). Zinc is a molecular signal for immune cells, required for the differentiation and generation of T helper cells (4). Moreover, several studies point to zinc, vitamins A and B<sub>3</sub>, and niacinamide as potential enhancers of scar reduction (27). The complex and multifaceted nature of acne pathophysiology presents numerous opportunities for vitamins and minerals to intervene in the inflammatory cascade. Beyond their traditional roles as essential dietary components, vitamins and minerals contribute to processes such as keratinocyte growth and differentiation, regulation of lipid synthesis in sebocytes, suppression of pro-inflammatory cytokines, matrix metalloproteinases, and antimicrobial peptides, while also functioning as antioxidants (28). In addition, melatonin has been successfully utilized in various human trials to counteract oxidative stress, reduce inflammation, prevent cellular apoptosis, and promote the restoration of tissue function (29).

Various techniques and systems are available to evaluate the severity of post-acne scars, including qualitative, quantitative, and objective instrumental methods. These tools allow for standardized diagnosis and assessment of treatment effectiveness. Therefore, this study encompasses various types of techniques for detailed and comprehensive evaluation of the treatment under investigation.

Regarding the instrumental methods, this study employs Eva-Face®, VISIA®, and Moisturemeter® D technologies, which show significant improvements in the size of atrophic scars and deep skin hydration over time.

Regarding quantitative measurements, the treatment demonstrated an improvement in the severity of acne scars analyzed with the ECCA scale after four applications, over 120 days from the start of the treatment. Moreover, using the Goodman and Baron quantitative scale, the treatment showed improvement compared to baseline as early as the third application, with further enhancement observed after the fourth application, confirming the results obtained with the ECCA scale.

In addition, the GAIS qualitative technique is used to assess overall aesthetic improvement after a treatment, including interventions for post-acne scars (16). Although it is not specifically designed for acne scars, it is frequently used in clinical studies and dermatological procedures because it measures the general perception of aesthetic results. For this reason, it has been included in this study as a complementary technique to assess the success of the microneedling-applied Pbserum Specific Acne Scars® treatment. The aesthetic outcomes of the product in this study were evaluated as “much improved” or “improved,” reflecting a positive perception of its effectiveness.

Moreover, after four applications of the product, patients reported improvements in every quality-of-life aspect evaluated. Despite experiencing varying levels of discomfort during the treat-

ment, a high percentage of patients expressed satisfaction with the final results, stating they would recommend the treatment and opt for it again. Importantly, no adverse events occurred beyond those within the expected range associated with the microneedling technique, further confirming the safety of the product tested.

It is widely accepted nowadays that the efficacy of acne scar treatments can vary based on the modality used, with certain combinations proving more effective. For example, a study indicated that a combination of microneedling and chemical peeling produced better effects in treating atrophic post-acne scars than both techniques separately (30). Therefore, the combination of microneedling and active compounds present in the Pbserum Specific Acne Scars® product presented in this work is a promising approach.

### Limitations of the study

The majority of patients treated were white, and this study was conducted in only one country (Spain). The response to treatments can vary based on skin type. For example, individuals with darker skin tones face a higher risk of complications such as hyperpigmentation from aggressive treatments such as deep chemical peels and certain laser therapies (31, 32). Therefore, the inclusion of other groups and geographical areas in future studies would expand the understanding of the efficacy of this approach.

The demographic characteristics of patients significantly influence treatment experiences and outcomes. For instance, females tend to report a higher psychological impact from acne scarring compared to males, particularly regarding personal relationships and body image disturbances (33). Adolescents are particularly vulnerable because they undergo critical developmental changes that make them more susceptible to psychosocial stressors associated with acne and its scarring (33). Although this study includes patients 18 to 55 years old, a detailed analysis of the treatment response by age group would be valuable for future studies.

### Conclusions

In conclusion, the product shows significant improvements in reducing atrophic scar size, especially after four applications of the product. Participants' satisfaction is high, although a significant proportion experienced some degree of discomfort during application. The majority of the patients would recommend the treatment and would opt for it if the price were affordable, highlighting the positive perception of the users on the efficacy of the product and the absence of adverse effects. This tool opens a new path by incorporating recent developments in dermatology and biotechnology to tackle unresolved challenges in the field of acne scars, an approach that is expected to positively impact patients' quality of life.

### Conflicts of interest

Valeria Kopytina and Jorge López Berroa are employees of Proteos Biotech.

### Acknowledgments

The authors would like to thank Guadalupe T. González-Mateo, Rubén Lopez-Aladid, Eudald Casals, and Javier Carrero from Premium Research, S.L., for their writing support.

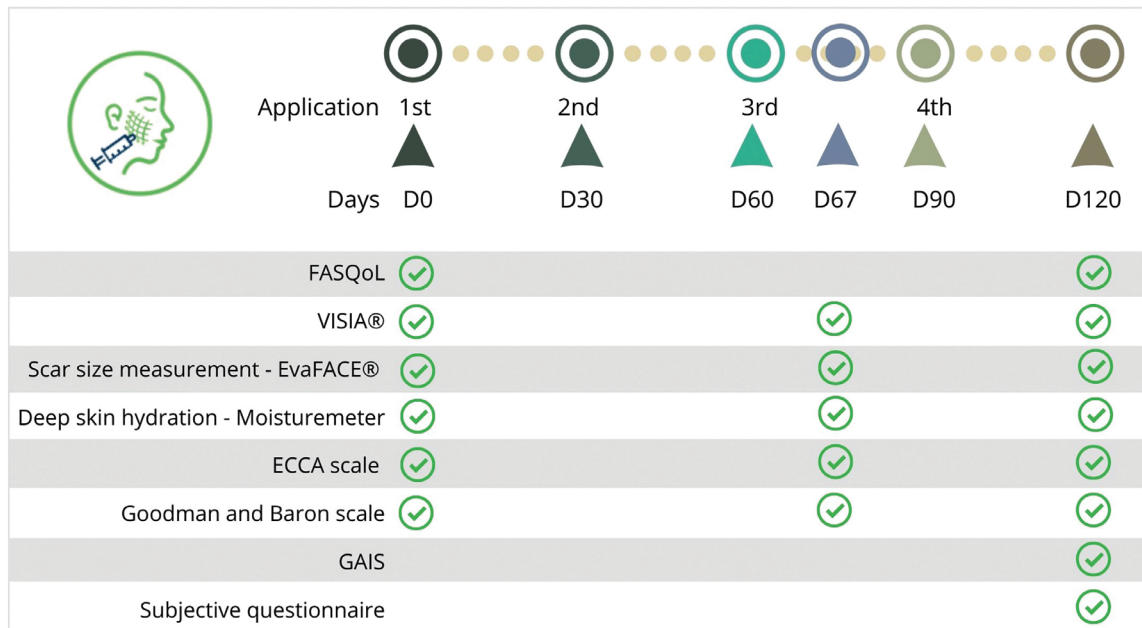
## Funding

No funding sources were received. Proteos Biotech supplied the product for the study.

## References

- Yadav MK, Soni P, Ghiya BC, Mehta RD, Arora A, Jangir VK, et al. Efficacy of autologous platelet rich plasma with subcision vs platelet rich plasma with microneedling in atrophic acne scars: a single-center, prospective, intra-individual split-face comparative study. *J Cutan Aesthet Surg*. 2024;17:184–8.
- Mägeruşan Şoimiţa E, Hancu G, Rusu A. Current understanding of microneedling procedures for acne skin: a narrative review. *Cosmetics*. 2024;11:193.
- Levy LL, Zeichner JA. Management of acne scarring, part II. *Am J Clin Dermatol*. 2012;13:331–40.
- Prasad AS. Zinc is an antioxidant and anti-inflammatory agent: its role in human health. *Front Nutr*. 2014;1:14.
- Hamed R, Abu Nahia BJ, Alkilani AZ, Al-Adhami Y, Obaidat R. Recent advances in microneedling-assisted cosmetic applications. *Cosmetics*. 2024;11:51.
- Larrañeta E, Lutton REM, Woolfson AD, Donnelly RF. Microneedle arrays as transdermal and intradermal drug delivery systems: materials science, manufacture and commercial development. *Mater Sci Eng R Rep*. 2016;104:1–32.
- Zduńska K, Kołodziejczak A, Rotsztein H. Is skin microneedling a good alternative method of various skin defects removal. *Dermatol Ther*. 2018;31:e12714.
- Ismail SA, Khella NAH, Abou-Taleb DAE. Which is more effective in atrophic acne scars treatment microneedling alone or platelet rich plasma alone or combined both therapeutic modalities? *Dermatol Ther*. 2022;35:e15925.
- Sadeghzadeh-Bazargan A, Pashaei A, Ghassemi M, Dehghani A, Shafiei M, Goodarzi A. Evaluation and comparison of the efficacy and safety of the combination of topical phenytoin and microneedling with microneedling alone in the treatment of atrophic acne scars: a controlled blinded randomized clinical trial. *Skin Res Technol*. 2024;30:e13766.
- Nanco-Meléndez C, Yagnam-Díaz M, Muñoz-Cáceres M, Contador-González J, Gubelin-Harcha W, Chicau-Carmona F, et al. Evaluation of ultrasound changes with the use of microneedling versus fractional CO<sub>2</sub> laser in atrophic acne scars. *Dermatol Pract Concept*. 2024;14:e2024168.
- Alqam ML, Maldonado JA. Microneedling for medical and aesthetic purposes: current indications and new advances. *CDT*. 2023;9:1–11.
- Ghofrani A, Hassannejad Z, Ghofrani A, Hassannejad Z. Collagen-based therapies for accelerated wound healing [Internet]. *IntechOpen*; 2024 [cited 2024 Nov 12]. Available from: <https://www.intechopen.com/online-first/89478>.
- Li F, Xu D. Functional role of R462 in the degradation of hyaluronan catalyzed by hyaluronate lyase from *Streptococcus pneumoniae*. *J Mol Model*. 2015;21:196.
- Dreno B, Khammari A, Orain N, Noray C, Mérial-Kieny C, Méry S, et al. ECCA grading scale: an original validated acne scar grading scale for clinical practice in dermatology. *Dermatology*. 2007;214:46–51.
- Goodman GJ, Baron JA. Postacne scarring—a quantitative global scarring grading system. *J Cosmet Dermatol*. 2006;5:48–52.
- ePROVIDE – Mapi Research Trust [Internet]. 2023 [cited 2024 Dec 15]. GAIS | Global Aesthetic Improvement Scale described in ePROVIDE. Available from: <https://eprovide.mapi-trust.org/instruments/global-aesthetic-improvement-scale>.
- Lio P, Sodha D. Acne scarring as a therapeutic endpoint: a review. *J Integr Dermatol*. 2023.
- Kim J. Topographic computer analysis for acne scar treatment on face accompanying biopsy study after dermal injection of hydrotoxin mixture. *J Cosmet Dermatol*. 2021;20:75–83.
- Arenas D, Svitlana K, Eloy Soto A, López Berroa J, Marín Rivera D. Efficacy and tolerance evaluation of Pbserum Smartker Equilibrium Professional. *LAJCSMT*. 2024;6:167–73.
- López Berroa J, Arenas Escribano D, Beltrán Arredondo B, Reyes N, López Gehrke I, Castelanich D. Evaluation of Pbserum Extreme Firmness' efficacy on the skin firmness and elasticity. *LAJCSMT*. 2024;6:56–63.
- El-Domyati M, Fathi MME, Abdel-Aziz RTA. Atrophic facial acne scars; bilateral comparison of two microneedle devices. *J Cosmet Laser Ther*. 2024;26:129–35.
- Boca AN, Gehrke IL, Lloreda C, Rustamzada S, Berroa JL. Recombinant enzymatic products in dermatology. *Surg Cosmet Dermatol*. 2024;16:1–5.
- Han HS, Park JW, Shin SH, Yoo KH, Sohn YS, Kim BJ. Single-center, assessor-blind study to evaluate the efficacy and safety of DA-5520 topical gel in patients with acne scars: a pilot study. *J Cosmet Dermatol*. 2022;21:3888–95.
- Campanati A, Ceccarelli G, Brisigotti V, Molinelli E, Martina E, Talevi D, et al. Effects of in vivo application of an overnight patch containing Allium cepa, allantoin, and pentaglycan on hypertrophic scars and keloids: clinical, videocapillaroscopic, and ultrasonographic study. *Dermatol Ther*. 2021;34:e14665.
- Conti V, Corbi G, Iannaccone T, Corrado B, Giugliano L, Lembo S, et al. Effectiveness and tolerability of a patch containing onion extract and allantoin for cesarean section scars. *Front Pharmacol*. 2020;11:569514.
- Araújo LU, Grabe-Guimarães A, Mosqueira VCF, Carneiro CM, Silva-Barcellos NM. Profile of wound healing process induced by allantoin. *Acta Cir Bras*. 2010;25:460–1.
- Cannizzaro MV, Dattola A, Garofalo V, Del Duca E, Bianchi L. Reducing the oral isotretinoin skin side effects: efficacy of 8% omega-ceramides, hydrophilic sugars, 5% niacinamide cream compound in acne patients. *G Ital Dermatol Venereol*. 2018;153:161–4.
- Marson JW, Baldwin HE. Vitamins and minerals in the treatment of acne vulgaris. In: Rupani RN, Lio PA, editors. *Integrative dermatology: practical applications in acne and rosacea*. Cham: Springer International Publishing; 2021.
- Reiter RJ, Mayo JC, Tan DX, Sainz RM, Alatorre-Jimenez M, Qin L. Melatonin as an antioxidant: under promises but over delivers. *J Pineal Res*. 2016;61:253–78.
- Pakla-Misiur A, Grochowicz M, Lesiak A, Bednarski IA. Double-blind, randomized controlled trial comparing the use of microneedling alone versus chemical peeling alone versus a combination of microneedling and chemical peeling in the treatment of atrophic post-acne scars. An assessment of clinical effectiveness and patients' quality-of-life. *Postepy Dermatol Alergol*. 2021;38:629–35.
- Sadick NS, Cardona A. Laser treatment for facial acne scars: a review. *J Cosmet Laser Ther*. 2018;20:424–35.
- Alexis AF, Coley MK, Nijhawan RI, Luke JD, Shah SK, Argobi YA, et al. Nonablative fractional laser resurfacing for acne scarring in patients with Fitzpatrick skin phototypes IV–VI. *Dermatol Surg*. 2016;42:392–402.
- Zhou C, Vempati A, Tam C, Khong J, Vasilev R, Tam K, et al. Beyond the surface: a deeper look at the psychosocial impacts of acne scarring. *CCID*. 2023;16:731–8.

Supplement



**Supplementary Figure 1** | Timeline of the study. Baseline measurements and first application of the product took place at day 0 (D0). The second to fourth treatment sessions were performed 30, 60, and 90 days after the first application (D30, D60, and D90). At days 67 and 90 + 30 (D60 + 7 and D90 + 30), 1 week and 1 month after the third and fourth applications, respectively, skin measurements were also taken. ECCA = échelle d'évaluation clinique des cicatrices d'acne, FASQoL = Facial Acne Scar Quality of Life questionnaire, GAIS = Global Aesthetic Improvement Scale.

**Supplementary Appendix 1** | Patient Subjective Evaluation Form: Satisfaction Questionnaire. Apart from these questions, patients were also asked whether they were satisfied with the final result (75.86% answered positively) and whether they would opt for this treatment over another if the price were affordable (89.66% answered positively). Data are shown as percentages of patients. All responses are self-reported and non-interventional.

Question	Very unsatisfied / unpleasant	Somewhat unsatisfied / unpleasant	Indifferent	Somewhat satisfied	Very satisfied / pleasant
Level of discomfort during the application	13.79	48.28	0.00	31.03	6.90
Skin texture immediately after each session	0.00	3.45	37.93	41.38	17.24
Skin texture 4 weeks after treatment	3.45	6.90	13.79	48.28	27.59
Scar size/volume reduction	0.00	17.24	17.24	44.83	20.69
Fragrance perception	3.00	0.00	62.07	17.24	17.24
Skin hydration	0.00	10.34	24.14	37.93	27.59
Skin smoothness	3.45	10.34	10.34	55.17	20.69
More even skin tone	0.00	10.34	27.59	44.83	17.24
Overall skin quality	0.00	6.90	13.79	55.17	24.14
Overall improvement of treated area	0.00	17.24	3.45	48.28	31.03

**Supplementary Appendix 2** | Facial Acne Scar Quality of Life questionnaire (FASQoL). When completing this questionnaire, patients were instructed not to consider active acne lesions (e.g., pimples, blackheads), scabs formed from acne lesions, or flat red or pigmented marks. Each question relates to the past 7 days and evaluates emotional and social aspects influenced by the presence of acne scars. Patients were asked to select the response that best reflects their experience. Data are shown as percentages of patients. All responses are self-reported and non-interventional. D = day.

Question	Not at all		A little		Somewhat		A lot		Extremely	
	D0	D120	D0	D120	D0	D120	D0	D120	D0	D120
Have you felt self-conscious around people because of the indentations or holes on your face?	13.8	48.3	31.0	34.5	31.0	17.2	17.2	0.0	17.0	0.0
Have you felt less attractive because of the indentations or holes on your face?	13.8	27.6	20.7	37.9	17.2	27.6	37.9	6.9	10.0	0.0
Have you felt bothered by the indentations or holes on your face?	24.1	41.4	20.7	31.0	24.1	27.6	24.1	0.0	6.9	0.0
Have you been worried that the marks or holes on your face might not go away?	13.8	17.2	20.7	37.9	17.2	31.0	24.1	13.8	24.0	0.0
Have you felt sad because of the indentations or holes on your face?	10.3	48.3	31.0	20.7	24.1	27.6	27.6	3.5	6.9	0.0
Have you been upset by negative comments from others about the marks or holes on your face?	51.7	69.0	20.7	17.2	6.9	13.8	13.8	0.0	6.9	0.0
Have the marks or holes on your face made you avoid going out with friends or family?	58.6	72.4	3.5	17.2	24.1	10.3	10.3	0.0	3.5	0.0
Have you felt bothered by having to hide the marks or holes on your face?	24.1	37.9	31.0	34.5	20.7	24.1	10.3	0.0	14.0	3.5
Have the marks or holes on your face affected your relationships with others (e.g., friends, family, romantic partners)?	51.7	55.2	20.7	20.7	10.3	20.7	13.8	0.0	3.5	3.5
Have the marks or holes on your face affected your participation in work or school?	62.1	75.9	17.2	13.8	13.8	10.3	3.5	0.0	3.5	0.0