

Nail psoriasis or trachyonychia? Can dermoscopy differentiate them?

Ahu Yorulmaz¹✉

¹Department of Dermatology, Ankara Bilkent City Hospital, Ankara, Turkey.

Abstract

Trachyonychia is a disease of the nail matrix that can present as either opaque or shiny trachyonychia. Although it is often idiopathic, it can be associated with conditions such as alopecia areata (AA), psoriasis, and lichen planus. Isolated nail psoriasis (NP) can mimic trachyonychia, making diagnosis challenging. Dermoscopy, a non-invasive imaging technique, has proven useful in identifying NP features. This report presents two cases: one with isolated psoriatic trachyonychia and another with AA-associated trachyonychia. In both cases, jagged erythema and teardrop-shaped spots on the lunula were observed, with the latter being described for the first time in trachyonychia literature. These findings suggest a potential link between inflammation and nail matrix pathology, warranting further investigation.

Keywords: nail psoriasis, trachyonychia, dermoscopy

Received: 13 December 2024 | Returned for modification: 17 January 2025 | Accepted: 27 January 2025

Introduction

Trachyonychia is a disease of the nail matrix. It appears as either opaque trachyonychia (rough, longitudinally ridged nails) or shiny trachyonychia (many superficial pits) (1). Although trachyonychia is generally idiopathic with no identifiable cause (2), it may be associated with a variety of diseases, including alopecia areata (AA), atopic dermatitis, psoriasis, and lichen planus (1, 3). Further nail findings are observed when the underlying cause is a disease that already affects the nail unit, such as nail psoriasis (NP) (1). NP has a wide range of clinical presentations, from complete nail plate destruction of all nails to localized pits on a few fingernails. Both types of trachyonychia are common patterns seen in NP. Isolated NP is a rare entity that poses a diagnostic challenge, not only because it lacks cutaneous manifestations of psoriasis, but also because its presentations may be indistinguishable from those of other nail diseases, such as trachyonychia (4). Dermoscopy is a non-invasive, highly practical imaging method that allows in vivo evaluation of the nail unit (5). Several studies have explored dermoscopic features of NP (6, 7). It has been suggested that dermoscopy may serve as a key tool in the evaluation of patients with NP, providing diagnostic information, even in the absence of cutaneous lesions (5). Here, two cases of trachyonychia are presented: one with isolated psoriatic trachyonychia and the other with AA-associated trachyonychia. This report discusses new dermoscopic features observed in these patients. In both cases, jagged erythema and teardrop-shaped spots were observed on the lunula. This report describes teardrop-shaped spots on the lunula for the first time in the literature in patients with trachyonychia.

Case reports

The first case, a 37-year-old female with a 6-year history of nail changes consistent with NP presented with nail lesions, consisting of thick nail plates, rough nails, longitudinal ridging, scaling, subungual hyperkeratosis, pitting, splinter hemorrhages, and distal onycholysis with an erythematous border. Arthritis was not found.

The second case, a 4-year-old male with a 1-year history of AA

hair loss and nail changes presented with trauma-related features (subungual and splinter hemorrhages), koilonychia, rough nails, longitudinal ridging, and cuticle hyperkeratosis. The nails were thin, and there were simultaneous Beau's lines on all nails. Multiple alopecic patches consistent with AA were found on the scalp.

In both patients, the typical appearance of trachyonychia was obvious (Fig. 1). Dermoscopically, longitudinal erythema, ridging, jagged erythema, and teardrop-shaped spots were observed on the lunula in both patients. The NP patient exhibited distal onycholysis with an erythematous border, a hallmark feature of NP, along with mottled lunula, pits with erythema, and white nail bed spots—distinct characteristics of NP. Cuticle hyperkeratosis was only observed in the patient with AA-associated trachyonychia (Fig. 2). Both patients were treated with topical corticosteroids.

Discussion

A recently published report highlighted the therapeutic effect of diphenylcyclopropenone on trachyonychia in a patient with alopecia universalis, noting the presence of jagged erythema on the lunula (8). The observation of both teardrop-shaped spots and jagged erythema on the lunula in the two cases presented suggests a common pathological process affecting the nail matrix in these patients. It is well established that NP and trachyonychia are disorders of the nail matrix (1, 3, 4). However, it remains unclear why these specific features have not been previously reported in NP. Dermoscopic evaluation of NP has been extensively studied, including in patients with psoriatic trachyonychia (5–7), yet no reports have documented these findings. In contrast, the literature on the dermoscopy of trachyonychia is extremely limited. The only existing study on trachyonychia dermoscopy identified characteristic findings such as an opaque appearance, longitudinal ridging, hypertrophic cuticles, and a red lunula (9). Additionally, Starace et al. conducted a retrospective analysis of 122 patients with trachyonychia, describing rough nails, pitting, koilonychia, hyperkeratosis, and an erythematous border as key dermoscopic features (3). Whether the newly described features in this report are characteristic of trachyonychia remains uncertain.

✉ Corresponding author: ahuyor@gmail.com

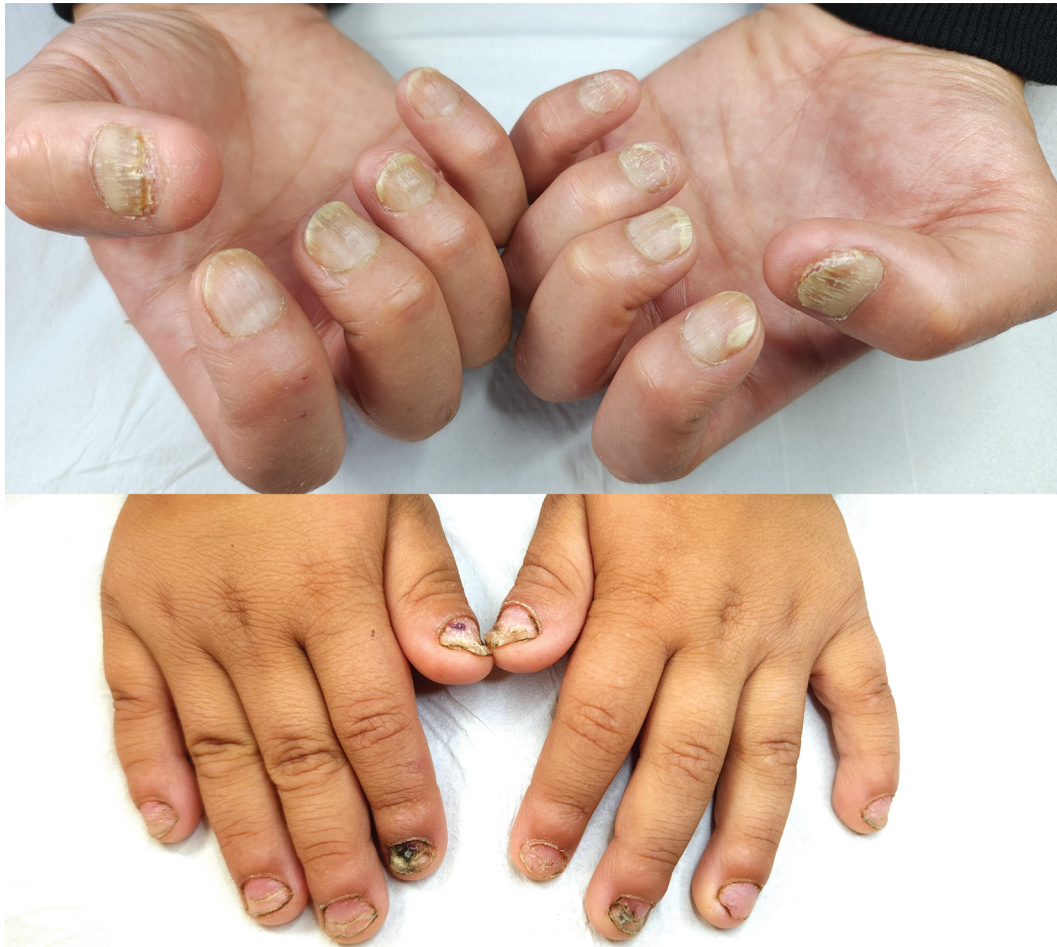

Figure 1 | Top: clinical image of the patient with psoriatic trachyonychia, showing distal onycholysis with an erythematous border on the left index fingernail—a diagnostic feature of nail psoriasis (NP). Bottom: clinical image of the patient with alopecia areata (AA)-related trachyonychia, displaying nail thinning and koilonychia, both characteristic of trachyonychia. Trauma-related features, including subungual and splinter hemorrhages, are also visible. Additionally, cuticle hyperkeratosis, a common feature of trachyonychia, and simultaneous Beau's lines on all nails are noted.

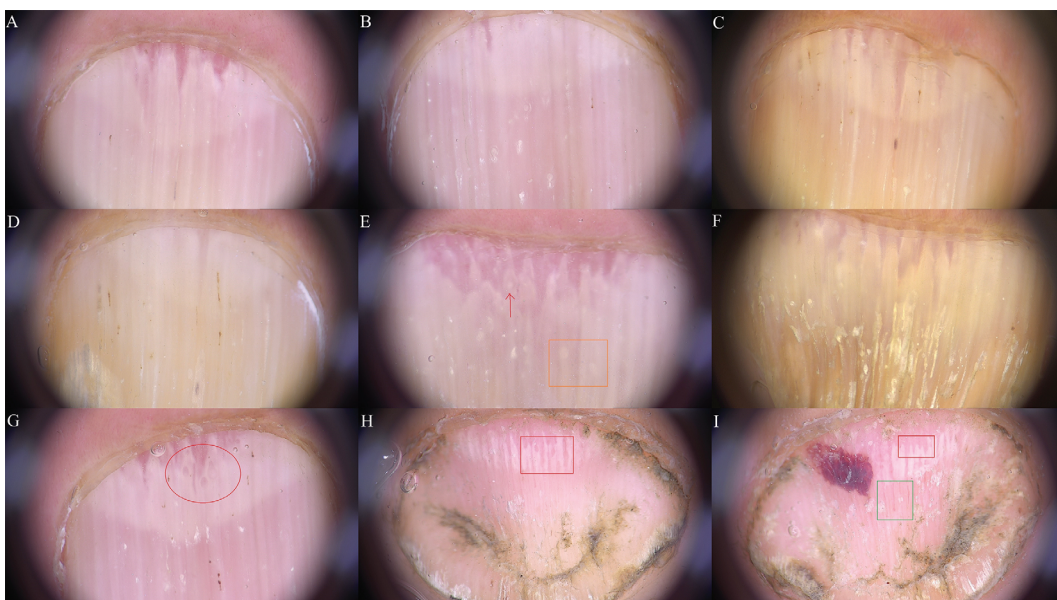


Figure 2 | A–G: dermoscopic images of the nails of the patient with nail psoriasis (NP); typical dermoscopic features of NP are present, including longitudinal erythema of the nail bed, splinter hemorrhages, and pitting; H and I: dermoscopic images of the nails of the patient with alopecia areata (AA)-related trachyonychia. A: jagged erythema on the lunula; B: note erythema around the pits, which is a unique feature of NP; there are more than 10 pits, and 10 pits in one nail is regarded as proof of NP; C: jagged erythema on the lunula; D: distal onycholysis with an erythematous border is a specific feature of NP; E: white spots and the lunula (red arrow) and nail bed (orange square); F: longitudinal ridging is the main feature of trachyonychia; the nail is thick and ridged; G: teardrop-shaped spots on the lunula have not been previously described in NP (red circle); H: teardrop-shaped spots on the lunula in the patient with AA-related trachyonychia (red rectangle); note cuticle hyperkeratosis, which is a common feature of trachyonychia; I: jagged erythema on the lunula (red rectangle); note that the nail is thinned and ridged, and there is subungual hemorrhage; there are dilated nail bed capillaries with a peripheral halo, some of which are in a continuum with jagged erythema on the lunula (green square).

Conclusions

This report discusses new dermoscopic features observed in patients with trachyonychia. In both cases, jagged erythema and teardrop-shaped spots were observed on the lunula. This report describes teardrop-shaped spots on the lunula for the first time in the trachyonychia literature. Red spots on the lunula are known to occur because of matrix blood vessel dilatation caused by an inflammatory process that affects the nail matrix (4). It is proposed that teardrop-shaped spots and jagged erythema differently represent red lunula in trachyonychia. The shape they have may

be related to the location and severity of the inflammation. Trachyonychia is most commonly characterized by focal spongiotic inflammation of the nail matrix (1). However, the exact pathological process causing the red lunula is unknown. Do other pathological processes, such as inflammatory angiogenesis, which is associated with NP (6), contribute to the development of trachyonychia? Why is red lunula only seen in some patients? Red lunula indicates a highly active disease in NP (4). Is it associated with the severity of trachyonychia? These and other questions will be addressed in subsequent reports.

References

1. Haber JS, Chairatchaneeboon M, Rubin AI. Trachyonychia: review and update on clinical aspects, histology, and therapy. *Skin Appendage Disord.* 2017;2:109–15.
2. Yorulmaz A. Idiopathic trachyonychia (twenty-nail-dystrophy). *J Cutan Med Surg.* 2022;26:436.
3. Starace M, Alessandrini A, Bruni F, Piraccini BM. Trachyonychia: a retrospective study of 122 patients in a period of 30 years. *J Eur Acad Dermatol Venereol.* 2020;34:880–4.
4. Haneke E. Nail psoriasis: clinical features, pathogenesis, differential diagnoses, and management. *Psoriasis.* 2017;7:51–63.
5. Yorulmaz A. Dermoscopy: the ultimate tool for diagnosis of nail psoriasis? A review of the diagnostic utility of dermoscopy in nail psoriasis. *Acta Dermatovenerol Alp Pannonica Adriat.* 2023;32:11–5.
6. Yorulmaz A, Aksoy GG. Dermoscopic features of nail psoriasis: revisited. *Skin Appendage Disord.* 2022;8:389–98.
7. Yorulmaz A. Onychoscopy in palmoplantar psoriasis: a comparative study of nonpustular palmoplantar psoriasis and palmoplantar pustulosis. *Dermatol Pract Concept.* 2024;14:e2024227.
8. Yorulmaz A. Diphenylcyclopropenone alleviates trachyonychia in alopecia universalis. *Int J Dermatol.* 2024;63:1615–7.
9. Jo G, Park JS, Yu DA, Ohn J, Sheu SL, Mun JH. Onychoscopy of trachyonychia: an analysis of 30 patients and comparison with onychomycosis. *Br J Dermatol.* 2018;179:491–3.