



OPEN ACCESS

# CARE-radiology statement explanation and elaboration: reporting guideline for radiological case reports

Mengshu Wang,<sup>1,2</sup> Xufei Luo,<sup>1,3</sup> Xiaojuan Xiao,<sup>4</sup> Linlin Zhang,<sup>5</sup> Qi Wang,<sup>6,7</sup> Shiyu Wang,<sup>8</sup> Ximing Wang,<sup>9</sup> Huadan Xue,<sup>10</sup> Longjiang Zhang,<sup>11</sup> Yaolong Chen ,<sup>1,3,12,13,14</sup> Junqiang Lei,<sup>2,15,16</sup> Tomaž Štupnik,<sup>17</sup> Marco Scarci,<sup>18</sup> Alfonso Fiorelli ,<sup>19</sup> Tanel Laisaar,<sup>20,21</sup> Robert Fruscio,<sup>22</sup> Hussein Elkhayat,<sup>23</sup> Nuria M. Novoa ,<sup>24,25</sup> Fabio Davoli,<sup>26</sup> Ryuichi Waseda ,<sup>27</sup> Janne Estill,<sup>1,28</sup> Susan L Norris,<sup>29</sup> David S Riley,<sup>30</sup> Jinhui Tian ,<sup>1,12</sup>

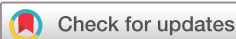10.1136/bmjebm-2023-112695

► Additional supplemental material is published online only. To view, please visit the journal online (<https://doi.org/10.1136/bmjebm-2023-112695>).

For numbered affiliations see end of article.

Correspondence to: Dr Jinhui Tian; [tjh996@163.com](mailto:tjh996@163.com)

MW and XL contributed equally.



© Author(s) (or their employer(s)) 2024. Re-use permitted under CC BY-NC. No commercial re-use. See rights and permissions. Published by BMJ.

**To cite:** Wang M, Luo X, Xiao X, et al. *BMJ Evidence-Based Medicine* 2024;**29**:399–408.

## Abstract

Despite the increasing number of radiological case reports, the majority lack a standardised methodology of writing and reporting. We therefore develop a reporting guideline for radiological case reports based on the CARE REport (CARE) statement. We established a multidisciplinary group of experts, comprising 40 radiologists, methodologists, journal editors and researchers, to develop a reporting guideline for radiological case reports according to the methodology recommended by the Enhancing the QUALity and Transparency Of health Research network. The Delphi panel was requested to evaluate the significance of a list of elements for potential inclusion in a guideline for reporting mediation analyses. By reviewing the reporting guidelines and through discussion, we initially drafted 46 potential items. Following a Delphi survey and discussion, the final CARE-radiology checklist is comprised of 38 items in 16 domains. CARE-radiology is a comprehensive reporting guideline for radiological case reports developed using a rigorous methodology. We hope that compliance with CARE-radiology will help in the future to improve the completeness and quality of case reports in radiology.

## Introduction

Case reports describe in detail the symptoms, signs, diagnosis, treatment and follow-up of individual patient(s), thus providing helpful information on the identification of adverse and beneficial effects, the recognition of new diseases, unusual forms of common diseases and the presentation of rare diseases.<sup>1,2</sup> Despite their intrinsic methodological limitations, such as the absence of control groups and small sample sizes, case reports can provide a snapshot of complex clinical scenarios and identify potential associations between various factors. For instance, a case report described

## WHAT IS ALREADY KNOWN ON THIS TOPIC

- ⇒ CASE REport (CARE) is a reporting guideline for case reports, comprising 13 items.
- ⇒ There are various extended versions of CARE, such as for surgical case reports and case reports on behavioural interventions, but there is currently no reporting guideline available for radiological case reports.

## WHAT THIS STUDY ADDS

- ⇒ We formed a multidisciplinary team of experts from 11 countries around the world to participate in the development and subsequent implementation of CARE-radiology.
- ⇒ The CARE-radiology checklist comprises 38 items across 16 domains.

## HOW THIS STUDY MIGHT AFFECT RESEARCH, PRACTICE OR POLICY

- ⇒ The CARE-radiology checklist provides the minimum lists of information for health researchers to use while writing manuscripts on radiological case reports.
- ⇒ We hope that CARE-radiology can assist radiologists and researchers in enhancing the writing and reporting of radiological case reports.

the presentation of acute respiratory distress syndrome following the administration of the COVID-19 vaccine.<sup>3</sup> Furthermore, case reports can be integrated into evidence syntheses.<sup>4</sup> Radiological case reports focus primarily on imaging and the diagnosis of rare and special clinical cases and can reinforce or suggest studies with more robust

designs, such as randomised controlled trials. In recent years, the number of published radiological case reports has been gradually increasing, especially after COVID-19 became a significant public health concern; case reports provided important information on diagnosis, transmission and clinical presentation early in the COVID-19 pandemic.<sup>5</sup>

Despite the increasing number of radiological case reports, the majority lack a standardised methodology of writing and reporting. A reporting guideline provides a minimum list of information that should be included in scientific articles and other published work. This helps to ensure the publication is comprehensive, the processes and methods are transparent and the information and conclusions are reliable and valid.<sup>6</sup> A consensus-based reporting guideline for case reports was published in 2013—the CAsE REport (CARE) statement.<sup>7</sup> However, a study using the CARE statement to evaluate the quality of radiological case reports published in five leading Chinese journals showed that the overall mean reporting rate of the CARE items among the 161 included studies was 33.5%.<sup>8</sup> The reporting rates for items related to the abstract (16.8%), timeline (24.8%), outcomes (32.9%), patient perspective (0%) and informed consent (0%) were low, suggesting that there is considerable room for improvement in the reporting of this type of case reports. In addition, one study also found that some items in the CARE statement do not apply to radiological case reports.<sup>8</sup> Regarding item 7 (timeline), in radiological case reports, the diagnosis is often based on a snapshot of diagnostic findings captured at a specific time point. Temporal sequencing issues are typically only briefly addressed in the section introducing the medical history, unless follow-up results are included in the report. Similarly, item 9 (type of intervention) is often not applicable because radiological case reports do not generally encompass specific interventions. Although the CARE checklist is applicable for case reports in any field of medicine, in some specific situations, the main checklist alone may not cover all essential aspects. Therefore, several extensions have been developed, such as CARE Guidelines for Therapeutic Massage and Bodywork Publications and Homeopathic Clinical Case Reports.<sup>9 10</sup>

To improve adherence to reporting guidelines in radiology and optimise the reporting quality of radiological case reports, this study aims to develop a reporting tool for case reports in radiology, which complements the CARE tool. We expect that diagnostic imaging specialists, other healthcare providers,

researchers, journal editors and other stakeholders will all benefit from CARE-radiology.

### Methods

The development process of CARE-radiology consisted of four key steps: preparatory work, drafting the preliminary checklist, a Delphi survey, and publication and implementation (figure 1). We chose the Delphi method because it allows to gather diverse opinions and ideas from a group of participants and provides a means for exchanging information and receiving feedback through group discussions. We registered CARE-radiology on the Enhancing the QUALity and Transparency Of health Research (EQUATOR) network on 6 December 2021 and adhered to its recommended methods.<sup>6</sup> A detailed protocol has been published elsewhere.<sup>11</sup>

**Step 1:** The preparatory work included the following tasks: (1) establishing the core working group, consensus group and external review group, (2) a review of available reporting guidelines for case reports and (3) evaluation of the quality of radiological case reports using CARE.<sup>7</sup> The aim of step 1 was to establish the initial item pool for CARE-radiology. The core working group consisted of three researchers: MW, a radiologist and the primary executor of the project; XL, a methodological expert in guidelines/reporting standards, primarily addressing methodological issues in the formulation of reporting standards; and JT, the grant holder and principal investigator. The members of the consensus group were primarily recruited by the Editorial Office of the *Chinese Journal of Radiology*. The Editorial Office provided a list of 50 experts from various universities and hospitals worldwide, from which we ultimately selected 28 experts for the consensus group. The experts were required to hold at least a MD or PhD degree and be radiologists or professionals in other related fields, such as thoracic surgery or cardiothoracic surgery. The external reviewers were contacted through the A Marvelous Experience (AME) Reporting Guideline Collaborative Group. AME provided a list of 15 experts from around the world. We selected 12 experts who were engaged in work related to imaging and radiological diagnosis but did not participate in the Delphi voting process. We also included a patient in the development process to gather her perspectives and suggestions regarding the CARE-radiology checklist. 16 reporting guidelines for case reports were identified in our review, and items extracted from them formed the initial pool.<sup>7 9 10 12-24</sup> The core working group evaluated the quality of

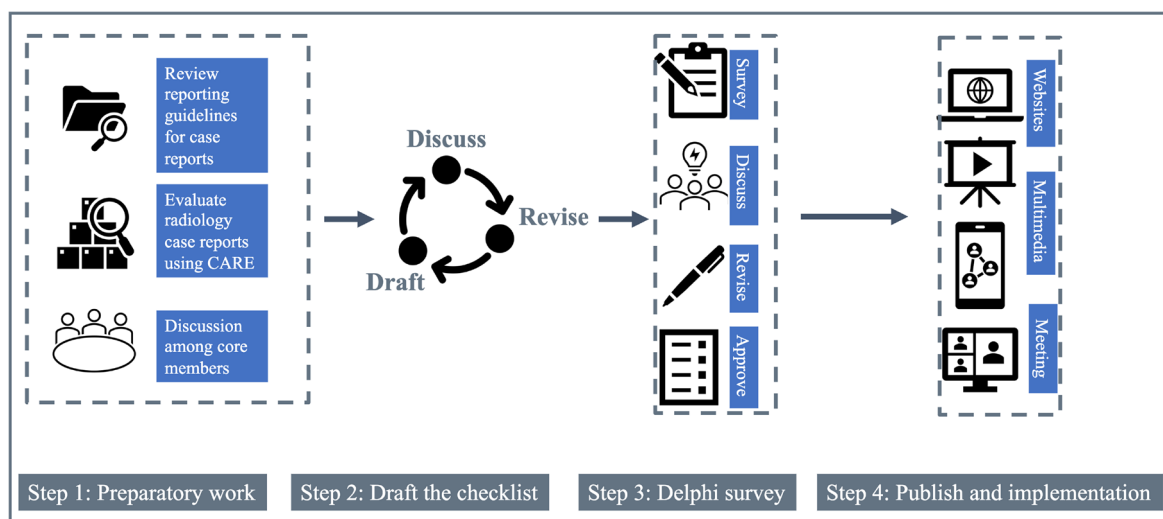


Figure 1 Methods for CARE-radiology development. CARE, CAsE REport.

radiological case reports published in radiology journals indexed in the Chinese Science Citation Database and MEDLINE database. See online supplemental appendix 1 for the preliminary item pool.

**Step 2:** The core working group members discussed the initial items and conducted two rounds of the discussion-revision-refinement process to formulate the questionnaire for the first round of the Delphi survey.

**Step 3:** The Delphi questionnaire was distributed to consensus group experts on 6 July 2022 via email, with feedback collected through 20 July 2022. Consensus was reached for all items in the first round of the Delphi survey based on the thresholds set in the protocol.<sup>11</sup> Subsequently, we held an online meeting via Tencent Meeting on 19 September 2022, to discuss the specific wording of the items. After discussion and revision, the core working group responded to all suggestions from the Delphi experts and returned the final checklist for their review and approval. The survey participants used a 9-point Likert scale (1 = strongly disagree and 9 = strongly agree) to show their agreement with each item in the survey. Items with a mean score below 7 after two rounds of survey were chosen for discussion in the consensus meeting or removed.

**Step 4:** The core working group invited 12 external experts in radiology and reporting guidelines to review the proposed reporting checklist. After publication, we plan to disseminate CARE-radiology through the EQUATOR network, seminars and academic conferences, among other venues. We will seek feedback from researchers, methodologists, journal editors and other users and update the checklist as necessary. In addition, we also plan to evaluate CARE-radiology's usability and satisfaction with the checklist.

CARE-radiology statement covers all imaging modalities, including ultrasound, radiation-based techniques such as x-rays, CT scans and MRI. We recommend using CARE-radiology for any case reports involving the use of any imaging technology.

## Results

### Participants

A total of 28 experts participated in the Delphi survey. 10 (35.7%) were senior researchers and/or practising diagnostic imaging physicians with at least 10 years in service, 18 (64.3%) were female, 21 (75.0%) were radiologists, 4 (14.3%) were reporting guideline methodologists and 3 (10.7%) were journal editors from the *Chinese Journal of Radiology* and *PeerJ*. All participants had experience publishing and reviewing case reports or participating in methodological studies related to reporting guidelines. The demographic information of experts who participated in the survey are presented in online supplemental appendix 2.

### Delphi survey

The initial Delphi survey contained 46 items in 16 domains, with mean scores ranging from 6.36 to 8.86 out of 9, including 3 items with mean scores below 7.00, 14 with mean scores between 7.00 and 8.00 and 29 with mean scores above 8.00. We merged items 2b and 2c into 2b; 4a and 4b into 4; 5a, 5b, 5c, 5d and 5e into 5a; and 10a, 10b and 10c into 10; removed the original items 9c, 9d and 13; and finally added a new item related to the artificial intelligence (AI) (9f). In addition, a total of 63 suggestions were collected from 16 experts and 3 suggestions from the patient representative. All suggestions and responses are presented in online supplemental appendix 3.

### CARE-radiology checklist

After the Delphi survey and discussion, the final checklist contained of 38 items in 16 domains. The final checklist is shown in table 1.

## Explanation and elaboration

### Title

1a. The diagnosis or phenomenon of focus should appear in the title.

1b. The diagnostic method(s) should be included in the title, such as CT and MRI.

1c. The words 'case report' should be included in the title.

**Explanation:** The title enables the reader to quickly identify the main content and design of the study. Radiology case reports should highlight the type of diagnostic method (e.g., CT and MRI) and reflect the study type (case report) in the title.

**Example:** *Case report: incidental finding of COVID-19 infection after positron emission tomography/CT imaging in a patient with a diagnosis of histoplasmosis and recurring fever.*<sup>25</sup>

### Keywords

2a. Keywords (3–6) that identify the study as a case report, along with the relevant diagnoses and diagnostic test or approach, should be presented.

2b. Keywords should avoid general and plural terms and multiple concepts; Medical Subject Headings (MeSH) terms or International Classification of Diseases 11th Revision disease categories are suggested; only use abbreviations firmly established in the field.

**Explanation:** Keywords should accurately reflect the main content and topic of the article. Keywords for radiology case reports should include 'case report', as well as the relevant disease name, pathological diagnosis or symptoms, and the method of diagnosis. Keywords should generally be MeSH or easily understood words. Abbreviations are not recommended unless they are widely recognised.

**Example:** 'Keywords: Case report; Delayed graft function; Diffusion-weighted magnetic resonance imaging; Kidney transplantation; Renal vein thrombosis'.<sup>26</sup>

### Abstract

3a. The abstract should describe what is unique about this patient and what it adds to the scientific literature.

3b. The abstract should outline the main imaging features of the patient and the diagnostic and prognostic value of any new technologies.

3c. The abstract should detail one or more 'take-away' lessons from the case report.

**Explanation:** The abstract is a concise summary of the main content of the full text. Abstracts for radiology case reports can be either structured or unstructured according to journal specifications. They generally need to describe the specific details of the case, the main imaging features and what lessons can be learnt by the reader. Items 3a and 3c are similar to those found in the reporting checklists for general case reports.

**Example:** *The key (CT) finding of the disease is bilateral extensive ground-glass opacification (GGO) with a peripheral or posterior distribution, mainly involving the lower lobes. In this case report, we present a pneumothorax and subcutaneous emphysema case in a patient with COVID-19. To the best of the authors' knowledge, it is the first illustrated case of pneumothorax accompanying COVID-19 pneumonia.*<sup>27</sup>

**Table 1** The CARE-radiology checklist

Domain	Item no.	Item	Where item is reported*
Title	1a	The diagnosis or phenomenon of focus should appear in the title	
	1b	The diagnostic method(s) should be included in the title, such as CT and MRI	
	1c	The words 'case report' should be included in the title.]	
Keywords	2a	Keywords (3–6) should be presented that identify the study as a case report, along with the relevant diagnoses and diagnostic test or approach	
	2b	Keywords should avoid general and plural terms and multiple concepts; Medical Subject Headings terms or International Classification of Diseases 11th Revision disease categories are suggested; only use abbreviations firmly established in the field	
Abstract	3a	The abstract should describe what is unique about this patient and what it adds to the scientific literature	
	3b	The abstract should outline the main imaging features of the patient and the diagnostic and prognostic value of any new technologies	
	3c	The abstract should detail one or more 'take-away' lessons from the case report	
Introduction	4	The introduction should outline the context for the case report and provide a brief background, such as the epidemiology or characteristics of the disease. It should also briefly summarise why this case is unique	
Patient information	5a	The relevant demographic and physical characteristics of the patient should be reported	
	5b	The primary symptoms of the patient as well as their medical and family history should be reported	
Clinical course	6a	The course of the disease and any treatments that may alter the imaging presentation should be reported. If the patient has multiple imaging examinations, the time point of each imaging examination should be presented	
	6b	The timelines of the disease course and imaging examinations should be reported	
Diagnostic assessment	7a	Diagnostic methods (physical examination, pertinent laboratory testing and other imaging) should be reported	
	7b	Diagnostic challenges should be reported, when applicable	
	7c	Diagnostic reasoning including any differential diagnoses should be reported	
	7d	Surgical and pathological diagnosis results should be presented when applicable	
	7e	If the diagnosis is beyond the scope of radiologists, diagnoses made by other medical providers should be reported, along with how the radiologists validated such diagnoses	
	7f	The report should describe relevant prognostic characteristics, such as tumour staging and genotype	
Imaging findings	8	The report should describe the essential imaging findings, including the typical features and key image identification points	
Image details	9a	Patient identifiers (names and hospital name) should be removed to ensure anonymity	
	9b	The report should indicate the contrast agent and details of the equipment, parameters, software and settings used to acquire the image(s)	
	9c	The resolution and any magnification of the image(s) or any modifications/enhancements (eg, adjustments for brightness, colour balance, magnification, image smoothing and staining) should be described in the text or legend	
	9d	Markers/labels should be used to identify the key features in the image(s), and they should be defined in the legend or as a footnote, if such information is indicated	
	9e	The specialists' profession, years of work experience and whether they have been trained should be reported	
	9f	If authors used AI tools for image interpretation or analysis, a disclosure and details of the use of AI-related tools should be provided	
Follow-up and outcomes	10	The clinician-assessed and patient-assessed outcomes as well as important adverse and unanticipated events from the imaging procedure or from any treatments should be reported, if such information is known	
Discussion	11 a	The rationale for the authors' conclusions should be provided	
	11b	A discussion of the relevant medical literature should be provided	
	11 c	The strengths and limitations of the authors' approach to this patient should be provided	
	11d	The applicability of the case to other persons, populations, settings, etc should be discussed	
	11e	The implications for practice, education and research should be described	
Conclusions	12	The key messages or lessons should be presented	
Patient perspective	13	The patient's perspective on the examination(s) they received should be reported, if such information are available	

Continued

Table 1 Continued

Domain	Item no.	Item	Where item is reported*
Informed consent and ethics	14 a	Patients' informed consent for the imaging procedure and the case report publication should be reported	
	14b	Ethics approval for publication of the case report should be reported	
Funding	15	Sources of funding, other support (such as supply of instruments and equipment) and the role of funders should be reported	
Conflict of interest	16	A summary of any conflicts of interest of all authors should be provided	

\*In this column, the user indicates where the information relating to that item are found in the publication. If the information are not found, indicate 'Not reported'.

Here, we report the clinical case of a 12-year-old girl presenting with flu-like symptoms, cough, anosmia, ageusia, breathing difficulties and patchy GGO on Tomodensitométrie chest scan who turned out to be COVID 229E infected. This case draws attention to the risk of false COVID-19 diagnosis when over-relying on CT scan imaging.<sup>28</sup>

### Introduction

The introduction should outline the context for the case report and provide a brief background, such as the epidemiology or characteristics of the disease. It should also briefly summarise why this case is unique.

**Explanation:** This section should provide an overview of the disease, such as the epidemiology and clinical or other characteristics. The introduction for radiological case reports closely resembles that found in other types of case reports. Given journal space limitations, an appropriate shortening of the introduction section may be considered according to the instructions for authors.

**Example:** COVID-19 is a disease caused by SARS CoV-2. The incubation period of the disease varies from 2 to 14 days (median 5 days). Although the disease is asymptomatic in some patients, it may progress to pneumonia, respiratory failure and even death at the end of the first week in some cases.<sup>3</sup>

A previous study showed that the patient had an epidemiological history, and CT scans showed typical COVID-19 pneumonia lesions in the lungs. From initial diagnosis to patient recovery, CT scans showed significant morphological changes in the lesions, but no literature has reported small cavities in the lungs on chest CTs as a sign of COVID-19.<sup>29</sup>

### Patient information

5a. The relevant demographic and physical characteristics of the patient should be reported.

5b. The primary symptoms of the patient as well as their medical and family history should be reported.

**Explanation:** Detailed information about the case address the disease, its severity and the diagnostic tests performed, enabling the reader to have a clear picture of this index case and its potential applicability to other cases. Such information may include age, sex, geographic location of the patient, ethnicity, occupation, body weight, body mass index or height of the patient. A radiology case report also requires a detailed description of the patient's complaints, symptoms and medication history. Other details may be needed depending on the specific case, such as the patient's occupation, menstrual history, birth history or genetic information.

**Example:** His main clinical manifestation was lower abdominal distension with no clear cause, which had started 15 years prior. The patient is married and has two children, both of whom are

healthy. His mother privately reported a notable and concerning history of duodenal enlargement.<sup>30</sup>

### Clinical course

6a. The course of the disease and any treatments that may alter the imaging presentation should be reported. If the patient has multiple imaging examinations, the time point of each imaging examination should be presented.

6b. The timelines of the disease course and imaging examinations should be reported.

**Explanation:** A detailed description of the patient's clinical course and disease progression allows the reader to contextualise all diagnostic procedures and results. Tables or graphical formats are often helpful in presenting the clinical course and diagnostic test results and their relationship to pathology and outcomes. For radiological case reports, a detailed account of the lineage of imaging examinations and treatment helps the reader understand the pathology stage and whether it can be attributed to treatment.

**Example:** On 15 February 2016, CT (figure 1A, B) and contrast-enhanced computed tomography (figure 2A,B) of the patient's upper abdomen revealed a mirror-image dextrocardia and inversion of all abdominal viscera and a space-occupying lesion in the pancreas tail, which was considered a benign neoplasm and suspected solid pseudopapillary tumour.<sup>31</sup>

Figure 1 Timeline representing the course of COVID-19 in the reported patient.<sup>32</sup>

### Diagnostic assessment

7a. Diagnostic methods (physical examination, pertinent laboratory testing and other imaging) should be reported.

7b. Diagnostic challenges should be reported, when applicable.

7c. Diagnostic reasoning including any differential diagnoses should be reported.

7d. Surgical and pathological diagnosis results should be presented when applicable.

7e. If the diagnosis is beyond the scope of radiologists, diagnoses made by other medical providers should be reported, along with how the radiologists validated such diagnoses.

7f. The report should describe relevant prognostic characteristics, such as tumour staging and genotype.

**Explanation:** Diagnostic assessment is one of the essential components of the radiology case report, and accurate reporting of this component is a prerequisite for assessing diagnostic accuracy. The case report's authors should describe the diagnostic approach, including physical examinations (eg, important specialty examinations and whole-body examinations) and relevant laboratory tests, along with the differential diagnoses that were considered. In addition, any challenges encountered in the diagnostic process and how they were addressed should be included (eg, inability to

complete certain tests for cultural or economic reasons, or lack of patient consent). If available, surgical and pathological diagnoses should be presented, including staging and genetic typing. Additional details should be provided if a non-author institution made important diagnoses (eg, surgical or pathological).

**Example:** *The physical examination revealed tenderness and swelling in the right inguinal area. The laboratory tests revealed leucocytosis (11.39×10<sup>3</sup>/μL), elevated C reactive protein (35.4 mg/L) and leucocyturia; however, the urine culture showed a negative result. Due to the progression of localised right inguinal pain, the emergency doctor arranged a CT scan to rule out incarcerated inguinal hernia.*<sup>33</sup>

*The entire tissue mass was sent for pathological examination, and the findings were identical to those seen in 2005; the diagnosis of recurrent CGCG was thus confirmed. The brown tumour of hyperparathyroid disease was excluded because normal levels of parathyroid hormone, plasma phosphate, calcium and total protein were detected.*<sup>34</sup>

*Preoperative cervical biopsy revealed high-grade squamous intraepithelial lesions and focal infiltration (depth of approximately 1 mm). The preoperative clinical diagnosis was stage IIA2 cervical cancer.*<sup>35</sup>

### Imaging findings

8. The report should describe the essential imaging findings, including typical features and key image identification points.

**Explanation:** Imaging presentation should be highlighted in the radiological case report, and typical imaging features should be reported prominently, along with key diagnostic differential points. Exemplary images should be presented, accompanied by markers and descriptions of key identification points and findings. Videos and animations of the imaging findings can be helpful to explain the case and imaging findings.

**Example:** *Chest CT revealed a left-sided pleural effusion with multiple nodules in both lungs.*<sup>36</sup>

*MRI brain and orbit was performed, showing an ill-defined heterogeneous soft tissue signal intensity (hypointense on T1-weighted imaging), polypoidal mucosal thickening involving left maxillary and ethmoid sinuses. A breach was seen in the posterior portion of the left lamina papyracea with altered signal intensity involving the conal and extraconal inferomedial portions of the left orbit. There was displacement of the adjacent medial and inferior rectus. Retrobulbar soft tissue fat stranding and oedema with resultant displacement of the left eyeball anteriorly leading to proptosis were observed. It was also found to be closely abutting the left optic nerve.*<sup>37</sup>

### Image details

9a. Patient identifiers (names and hospital names) should be removed to ensure anonymity.

9b. The report should indicate the contrast agent and details of the equipment, parameters, software and settings used to acquire the image(s).

9c. The resolution and any magnification of the image(s) or any modifications/enhancements (eg, adjustments for brightness, colour balance, magnification, image smoothing and staining) should be described in the text or legend.

9d. Markers/labels should be used to identify the key features in the image(s), and they should be defined in the legend or as a footnote, if such information are indicated.

9e. The specialists' profession, years of work experience and whether they have been trained should be reported.

9f. If authors used AI tools for image interpretation or analysis, detailed disclosure of AI-related tools and specifics should be provided.

**Explanation:** The presentation of key diagnostic images is essential to an optimal imaging case report while protecting patient privacy. To facilitate the reader's understanding of the image, information on any contrast agents used, the diagnostic equipment, parameters of equipment or software, analysis software and various settings should be provided. The image resolution, magnification and any image processing such as adjustments to brightness or colour balance should be described in the text or footnotes. If available, the diagnosing physician's years of experience and whether they have received specialised training should also be reported, as these factors can correlate with diagnostic accuracy.<sup>38 39</sup>

**Example:** *(a) Chest CT on admission showing multiple ground-glass opacities in bilateral lungs, mainly in the subpleural areas. (b) CT image 3 days later showing marked progression of multiple ground-glass opacities in the subpleural areas. (c, d) High-resolution CT images at the same period of a and b, respectively, showing nodular ground-glass opacities in the subpleural areas in the upper lobe of the left lung, which progressed significantly within 3 days.*<sup>40</sup>

*All CT examinations were obtained using the Philips iCT 256 or iQon Spectral CT systems. Data were acquired using a 128×0.625 mm or 64×0.625 mm detector configuration with dual sampling and a rotation time of 0.33 s (120 kVp 72 mAs).*<sup>41</sup>

*H&E staining and immunohistochemical staining. (A) H&E staining; (B) Myeloperoxidase staining; (C) C-Kit staining; (D) Ki67 staining; (E) Ten-Eleven-Translocation 2 staining; (F) 5-hydroxymethylcytosine staining; ×400.*<sup>42</sup>

*ChatGPT was used in writing this case report.*<sup>43</sup>

### Follow-up and outcomes

The clinician-assessed and patient-assessed outcomes as well as important adverse and unanticipated events resulting from the imaging procedure or any treatments should be reported, if this information is known.

**Explanation:** Although we are focusing on imaging case reports, the patient's outcomes should ideally be reported, as they relate to specific treatments or interventions. Also report other diagnostic evaluations performed during the patient's follow-up and any adverse events.

**Example:** *The patient still had fever after 1 week of anti-infective treatment, and the inflammatory indices did not decrease significantly compared with before.*<sup>44</sup>

*Two weeks after the primary procedure, the patient was discharged with an improved clinical condition. There was a short readmittance following a wound infection.*<sup>45</sup>

### Discussion

11a. The rationale for the authors' conclusions should be provided.

11b. A discussion of the relevant medical literature should be provided.

11c. The strengths and limitations of the authors' approach to this patient should be provided.

11d. The applicability of the case to other persons, populations, settings, etc should be discussed.

11e. The implications for practice, education and research should be described.

**Explanation:** The discussion section should provide a brief overview of the results, along with a comparison to relevant, previously published cases. The authors should explain why the

case report is unique and how it differs from similar cases reported in literature. In addition, the discussion should include an opinion regarding the potential extrapolation of the results to other patients and settings. Also, the significance and value of the case for future research and practice should be provided. A discussion of the strengths and limitations of the case report can also impart lessons for subsequent investigators.

**Example:** *The large polycystic part of the tumour was a major characteristic of the present case. We speculated that the cystic components of extrauterine endometrial stromal sarcoma (EESS) might tend to be larger than those in uterine endometrial stromal sarcoma (ESS), given the lower pressure from the surrounding tissues in the uterine myometrium. However, very few studies have focused on this issue. Khan et al reported two EESS cases (the grade was low in one patient but undescribed for the other), in which CT imaging showed large tumours occupying the right lobe of the liver, most of which had large cystic components in both cases. Kim et al reviewed 16 EESS cases, including the 2 cases reported by Khan et al; macroscopically, 4 EESS cases contained cystic parts, but the grade was unknown in 3 of them. In a review of low-grade EESS by Xie et al, two out of nine included cystic parts macroscopically; however, information about the size of the cystic components was unavailable. For uterine low-grade ESS (LGESS), although cystic change is frequent (up to 70%), cystic components tend to be small, as seen in the study by Park et al, in which the mean size of the 10 LGESS cases (including seven cystic components) was 2.8 cm (range, 1.3–4.5 cm). EESS may therefore be characterised by a tendency to exhibit a larger cystic component compared with uterine ESS. To confirm this, further investigation with a larger number of patients is needed.*<sup>46</sup>

*It should be noted that the abnormal focal accumulation of radiotracer with limited cancer specificity in PET/CT examination in organs or tissues in patients with cancer should not be unambiguously taken as a metastatic lesion, and sometimes, more diagnostic tests may need to be performed.*<sup>47</sup>

*This differentiation of lipomas from other lesions of the internal auditory canal has implications for therapeutic management.*<sup>48</sup>

### Conclusions

12. The key messages or lessons should be presented.

**Explanation:** The conclusion section of the radiological case report should be very brief, including the case's key diagnostic imaging and differential diagnostic features and the significance or value of any new techniques or methods. Given the length constraints of case reports, it is often necessary to merge the discussion and conclusion sections into a single section.

**Example:** *This case demonstrated the advantage of 18F-fluorodeoxyglucose (FDG) PET/CT in the evaluation of disease activity in kaposiform hemangioendothelioma and highlighted the possibility of using 18F-FDG PET/CT to guide therapy and prognostication.*<sup>49</sup>

### Patient perspective

13. The patient's perspective on the examination(s) they received should be reported if such information are available.

**Explanation:** The patient's perspective or feelings about the diagnosis and treatment can help to enhance or optimise the diagnostic tests or processes and identify problems in diagnosis and treatment. Patients may have invaluable perspectives on the diagnostic process and treatment course.

**Example:** *I am a very active person and enjoy playing tennis and gardening. My symptoms prior to coming to George Washington (GW) Center for Integrative Medicine prevented me from participating in the leisure activities that I enjoy. The quality of*

*my sleep and my overall quality of life were not good. After coming to the GW Center for Integrative Medicine, all of my symptoms improved and I experienced a drastic improvement in my quality of life.*<sup>50</sup>

### Informed consent and ethics

14a. Patients' informed consent for the imaging procedure and the case report publication should be reported.

14b. Ethics approval for publication of the case report should be reported.

**Explanation:** Informed patient consent and ethics approval by the relevant institutional body are essential components of research involving human subjects, including imaging case reports. It is important to note that patient consent to treatment and participation in research is not the same as consent for publication: both must be obtained.

**Example:** *The authors have obtained the patient's consent.*<sup>51</sup>

*Ethics approval and consent to participate: the patient gave a written consent for publication.*<sup>52</sup>

### Funding

Sources of funding, other support (such as the supply of instruments and equipment) and the role of the funders should be reported.

**Explanation:** The funding sources for the case study and any closely related research should be reported, just as in clinical research, systematic reviews and clinical practice guidelines.

**Example:** *Funding: The authors disclosed receipt of the following financial support for the research, authorship and/or publication of this article. This work was supported by the Guizhou Provincial Science and Technology Projects, Qian Ke He Foundation-ZK (2022) General 253, the Doctor Foundation of Guizhou Provincial People's Hospital (GZSYBS[2019]02) and the Science and Technology Fund Projects of Guizhou Health Commission (gzwkj2023-210).*<sup>52</sup>

**FUNDING:** *Alimera Sciences Ltd funded the Rapid Service Fees.*<sup>53</sup>

### Conflicts of interest

A summary of any conflicts of interest of all authors should be provided.

**Explanation:** Conflicts of interest can generally be categorised as financial and non-financial interests. Conflicts of interest should be reported in detail in radiological case reports, particularly regarding the use of imaging equipment, facilities and contrast materials.

**Example:** *Competing interests: none declared.*<sup>51</sup>

*The authors declare that the research was conducted in the absence of any commercial or financial relationships that could be construed as a potential conflict of interest.*<sup>54</sup>

### Discussion

As the number of radiology case reports increases, there is a need to standardise their reporting. CARE-radiology is the first radiology-oriented case reporting guideline developed using the methodology recommended by the EQUATOR collaborative network involving a multidisciplinary panel of experts. It is essential to note that CARE-radiology is a standard for reporting radiological case studies and is not intended to be a quality assessment tool for radiological case reports. It should also be noted that although CARE-radiology can guide the writing of radiological case reports, it should always be used together with the journal's instructions for authors.

When drafting radiology case reports, we recommend following CARE-radiology rather than CARE because CARE-radiology is tailored to this specific type of case report and covers the diagnostic methods and image-related content in more detail. CARE-radiology presents the minimum and most important criteria for writing; authors are free to provide additional information that they consider important, without restriction. The order of items in CARE-radiology is based on typical reporting practices: authors can make appropriate adjustments according to their context and journal specifications.

CARE-radiology was established according to the principles of developing international reporting guidelines,<sup>6</sup> with a systematic review of the current relevant literature, along with explanations and examples to facilitate better understanding by readers. However, it also has some limitations. First, some potential domains (eg, authorship) or items (eg, limitations on the number of authors) have not been included in CARE-radiology due to the lack of consensus at present. They will be considered in future updates. Second, due to the COVID-19 pandemic, no face-to-face meetings were held, and all discussions and consensus meetings were conducted by email or online, potentially limiting the sharing of perspectives and ideas.

We believe that CARE-radiology can improve the quality of radiological case reports in the future. In subsequent stages, we will work to achieve the following: (1) enhance the influence of CARE-radiology and promote its dissemination and implementation through academic conferences and publications, (2) actively seek the endorsement of CARE-radiology by journals, (3) translate the CARE-radiology checklist into multiple languages for dissemination, (4) evaluate and monitor the impact of CARE-radiology and actively collect opinions and suggestions on its use to inform updates and (5) conduct a prospective study on the impact of CARE-radiology on the quality of radiological case reports.

## Conclusion

CARE-radiology is a reporting guideline for radiological case reports developed using a rigorous methodology. We hope it will help to improve the quality of radiological case reports in the future.

### Author affiliations

- <sup>1</sup>Evidence-Based Medicine Center, School of Basic Medical Sciences, Lanzhou University, Lanzhou, China
- <sup>2</sup>Department of Radiology, The First Hospital of Lanzhou University, Lanzhou, China
- <sup>3</sup>Research Unit of Evidence-Based Evaluation and Guidelines, Chinese Academy of Medical Sciences (2021RU017), School of Basic Medical Sciences, Lanzhou University, Lanzhou, China
- <sup>4</sup>Department of Radiology, The Eighth Affiliated Hospital, Sun Yat-Sen University, Guangzhou, Shenzhen, China
- <sup>5</sup>Editorial Office of Chinese Journal of Radiology, Beijing, China
- <sup>6</sup>Health Research Methods, Evidence, and Impact (HEI), McMaster University, Hamilton, ON, Canada
- <sup>7</sup>McMaster Health Forum, McMaster University, Hamilton, ON, Canada
- <sup>8</sup>Department of Radiology, Zhongshan Hospital, Fudan University, Shanghai, China
- <sup>9</sup>Department of Radiology, Shandong Provincial Hospital Affiliated to Shandong First Medical University, Jinan, China
- <sup>10</sup>Department of Radiology, Translational Medicine Center, Peking Union Medical College Hospital, Chinese Academy of Medical Sciences and Peking Union Medical College, Beijing, China
- <sup>11</sup>Department of Radiology, Jinling Hospital, Medical School of Nanjing University, General Hospital of Eastern Theater Command, Nanjing, China
- <sup>12</sup>Key Laboratory of Evidence Based Medicine of Gansu Province, Lanzhou, China

- <sup>13</sup>Institute of Health Data Science, Lanzhou University, Lanzhou, China
- <sup>14</sup>World Health Organization Collaboration Center for Guideline Implementation and Knowledge Translation, Lanzhou, China
- <sup>15</sup>Intelligent Imaging Medical Engineering Research Center of Gansu Province, Lanzhou, China
- <sup>16</sup>Accurate Image Collaborative Innovation International Science and Technology Cooperation Base of Gansu Province, Lanzhou, China
- <sup>17</sup>Medical Faculty, University of Ljubljana, Ljubljana, Slovenia
- <sup>18</sup>Department of Cardiothoracic Surgery, Imperial College Healthcare NHS Trust, London, UK
- <sup>19</sup>Thoracic Surgery Unit, University of Campania “Luigi Vanvitelli”, Naples, Italy
- <sup>20</sup>Department of Thoracic Surgery and Lung Transplantation, Lung Clinic, Tartu University Hospital, Tartu, Estonia
- <sup>21</sup>Lung Clinic, Institute of Clinical Medicine, Medical Faculty, University of Tartu, Tartu, Estonia
- <sup>22</sup>Clinic of Obstetrics and Gynecology, University of Milan-Bicocca, IRCCS San Gerardo, Monza, Italy
- <sup>23</sup>Cardiothoracic Surgery Department, Faculty of Medicine, Assiut University, Assiut, Egypt
- <sup>24</sup>Thoracic Surgery, Puerta de Hierro University Hospital-Majadahonda, Madrid, Spain
- <sup>25</sup>Biomedical Institute of Salamanca, Salamanca, Spain
- <sup>26</sup>General & Thoracic Surgery Unit, IRCCS Istituto Ortopedico Rizzoli, Bologna, Italy
- <sup>27</sup>Department of General Thoracic, Breast and Pediatric Surgery, Fukuoka University, Fukuoka, Japan
- <sup>28</sup>Institute of Global Health, University of Geneva, Geneva, Switzerland
- <sup>29</sup>Oregon Health & Science University, Portland, Oregon, USA
- <sup>30</sup>University of New Mexico Medical School, Santa Fe, New Mexico, USA

X Hussein Elkhayat @ikhayat

**Acknowledgements** The authors appreciate the academic support from the A Marvelous Experience (AME) Reporting Guideline Collaborative Group. We also thank the experts who participated in the Delphi survey, the patient who provided suggestions for the checklist and A Kassem for the help with language polishing. We would also like to express our gratitude to the following members of CARE-radiology group for their participation in the Delphi survey: Alfonso Fiorelli (University of Campania “Luigi Vanvitelli”), Bing Lv (Fuwai Hospital), David S Riley (University of New Mexico Medical School), Dexin Yu (Qilu Hospital of Shandong University), Fabio Davoli (Santa Maria delle Croci Teaching Hospital), Hairui Xiong (Shenzhen Children’s Hospital), Hongyue Tao (Huashan Hospital, Fudan University), Huadan Xue (Peking Union Medical College Hospital), Huanjun Wang (The First Affiliated Hospital, Sun Yat-sen University), Hussein Elkhayat (Assiut University), Janne Estill (University of Geneva), Jinzhui Tian (Lanzhou University), Junfang Xian (Beijing Tongren Hospital), Junqiang Lei (The First Hospital of Lanzhou University), Lei Xu (Beijing Anzhen Hospital), Li Fan (Shanghai Changzheng Hospital), Liangru Ke (Sun Yat-sen University Cancer Center), Liming Xia (Tongji Hospital, Tongji Medical College of Huazhong University of Science and Technology), Ling Hu (Editorial Office of Chinese Journal of Radiology), Linlin Zhang (Editorial Office of Chinese Journal of Radiology), Longjiang Zhang (Jinling Hospital, Medical School of Nanjing University), Marco Scarci (Imperial College Healthcare NHS Trust), Mengshu Wang (Lanzhou University), Nuria M Novoa (Puerta de Hierro Majadahonda University Hospital), Qi Wang (McMaster University), Robert Fruscio (University of Milan-Bicocca), Ryuichi Waseda (Fukuoka University), Shiyu Wang (Zhongshan Hospital, Fudan University), Shu Yang (Chengdu University of TCM), Susan L Norris (Oregon Health & Science University), Tanel Laisaar (Tartu University

Hospital), Tomaž Štupnik (University of Ljubljana), Xiaojuan Shi (Editorial Office of Chinese Journal of Radiology), Xiaojuan Xiao (The Eighth Affiliated Sun Yat-sen University), Ximing Wang (Shandong Provincial Hospital Affiliated to Shandong First Medical University), Xin Lou (Chinese PLA General Hospital), Xinyue Yang (Zhujiang Hospital of Southern Medical University), Xufei Luo (Lanzhou University), Yanfang Ma (Hong Kong Baptist University), Yao Wang (Yunnan Cancer Hospital), Yaolong Chen (Lanzhou University), Yi Dai (Peking University Shenzhen Hospital), Yibo Tang (Zhongshan Hospital, Fudan University), Yinghui Jin (Zhongnan Hospital of Wuhan University) and Yun Zhang (West China Hospital, Sichuan University).

**Contributors** Study concepts/study design: MW, XL and JT. Guarantors of the integrity of the entire study: JT, SLN and DSR. Developed the search strategies and conducted the literature review: MW, XL, XX, LZ, QW and SW. Delphi material preparation: MW, XL, YC and JL. Delphi survey: XX, LZ, QW, SW, XW, HX, LZ, YC, JL, TS, MS, AF, TL, RF, HE, NN, FD, RW, JE and JT. Manuscript drafting or manuscript revision for important intellectual content: all authors. Manuscript editing: all authors. Approval of the final version of the submitted manuscript: all authors. Guarantor of the overall content: JT.

**Funding** This work was funded by the Fundamental Research Funds for the Central Universities, Lanzhou University, China (lzujbky-2021-ey13). The funding institution played no role in the study design, data collection and analysis, writing of the article or the decision to submit it for publication.

**Competing interests** None declared.

**Patient and public involvement** Patients and/or the public were not involved in the design, or conduct, or reporting, or dissemination plans of this research.

**Patient consent for publication** Not applicable.

**Ethics approval** This study involved human participants, who were solely involved in the survey phase. Ethical approval was obtained from the Ethical Review Committee of the Institute of Health Data Science, Lanzhou University (HDS-202207-01). Participants gave informed consent to participate in the study before taking part.

**Provenance and peer review** Not commissioned; externally peer reviewed.

**Data availability statement** Data are available upon reasonable request.

**Supplemental material** This content has been supplied by the author(s). It has not been vetted by BMJ Publishing Group Limited (BMJ) and may not have been peer-reviewed. Any opinions or recommendations discussed are solely those of the author(s) and are not endorsed by BMJ. BMJ disclaims all liability and responsibility arising from any reliance placed on the content. Where the content includes any translated material, BMJ does not warrant the accuracy and reliability of the translations (including but not limited to local regulations, clinical guidelines, terminology, drug names and drug dosages), and is not responsible for any error and/or omissions arising from translation and adaptation or otherwise.

**Open access** This is an open access article distributed in accordance with the Creative Commons Attribution Non Commercial (CC BY-NC 4.0) license, which permits others to distribute, remix, adapt, build upon this work non-commercially, and license their derivative works on different terms, provided

the original work is properly cited, appropriate credit is given, any changes made indicated, and the use is non-commercial. See: <http://creativecommons.org/licenses/by-nc/4.0/>.

#### ORCID iDs

Yaolong Chen <http://orcid.org/0000-0002-9841-5233>  
Alfonso Fiorelli <http://orcid.org/0000-0002-0628-613X>  
Nuria M. Novoa <http://orcid.org/0000-0003-0124-6347>  
Ryuichi Waseda <http://orcid.org/0000-0002-6326-4295>  
Jinhui Tian <http://orcid.org/0000-0001-5613-5041>

#### References

- 1 Nakamura T, Igarashi H, Ito T, *et al*. Important of case-reports/series, in rare diseases: using neuroendocrine tumors as an example. *World J Clin Cases* 2014;2:608–13.
- 2 Guidelines to writing a clinical case report. *Heart Views* 2017;18:104.
- 3 Sahin Tutak A, Söylemez F, Konuk HB, *et al*. A patient presenting with ARDS after COVID-19 vaccination: a COVID-19 case report. *J Infect Public Health* 2021;14:1395–7.
- 4 Nissen T, Wynn R. The clinical case report: a review of its merits and limitations. *BMC Res Notes* 2014;7:264.
- 5 Scaffidi MA, Gimpaya N, Li J, *et al*. Completeness of reporting for COVID-19 case reports, January to April 2020: a meta-epidemiologic study. *CMAJ Open* 2021;9:E295–301.
- 6 Moher D, Schulz KF, Simera I, *et al*. Guidance for developers of health research reporting guidelines. *PLoS Med* 2010;7:e1000217.
- 7 Gagnier JJ, Kienle G, Altman DG, *et al*. The CARE guidelines: consensus-based clinical case reporting guideline development. *J Med Case Rep* 2013;7:223.
- 8 Wang M, Luo X, Xiao X, *et al*. Assessment study on the quality of diagnostic radiographic case reports published in imaging journals of the Chinese science citation database. *Chinese J Radiol* 2022;56:898–904.
- 9 Munk PhD, LMT N, Boulanger PhD, CMT K. Adaptation of the CARE guidelines for therapeutic massage and bodywork publications: efforts to improve the impact of case reports. *IJTM* 2014;7:32–40.
- 10 van Haselen RA. Homeopathic clinical case reports: development of a supplement (HOM-CASE) to the CARE clinical case reporting guideline. *Complement Ther Med* 2016;25:78–85.
- 11 Wang M, Zhu Y, Luo X, *et al*. Protocol for developing the reporting guidelines for radiological case reports. *Ann Transl Med* 2022;10:107.
- 12 Agha RA, Franchi T, Sohrabi C, *et al*. The SCARE 2020 guideline: updating consensus surgical case report (SCARE) guidelines. *Int J Surg* 2020;84:226–30.
- 13 Lavergne V, Ouellet G, Bouchard J, *et al*. Guidelines for reporting case studies on extracorporeal treatments in poisonings: methodology. *Semin Dial* 2014;27:407–14.
- 14 Nagendrababu V, Chong BS, McCabe P, *et al*. PRICE 2020 guidelines for reporting case reports in endodontics: a consensus-based development. *Int Endod J* 2020;53:619–26.
- 15 Shelton CL, Klein AA, Bailey CR, *et al*. The anaesthesia case report (ACRE) checklist: a tool to promote high-quality reporting of cases in peri-operative practice. *Anaesthesia* 2021;76:1077–81.
- 16 Tate RL, Perdices M, Rosenkoetter U, *et al*. The single-case reporting guideline in behavioural interventions (SCRIBE) 2016 statement. *J Clin Epidemiol* 2016;73:142–52.
- 17 Fu S-F, Cheng C-W, Zhang L, *et al*. Consensus-based recommendations for case report in Chinese medicine (CARC). *Chin J Integr Med* 2016;22:73–9.
- 18 Green BN, Johnson CD. How to write a case report for publication. *J Chiropr Med* 2006;5:72–82.
- 19 Berling I, Hatten BW, Hoffman RS, *et al*. Guidelines for reporting case studies and series on drug-induced QT interval prolongation and its complications following acute overdose. *Clinical Toxicology* 2020;58:20–8.
- 20 Rodgers M, Thomas S, Harden M, *et al*. *Developing a methodological framework for organisational case studies: a rapid review and consensus development process*. Southampton (UK): NIHR Journals Library, 2016: 3–9.
- 21 Virues-Ortega J, Moreno-Rodriguez R. Guidelines for clinical case reports in behavioral clinical psychology. *Int J Clin Health Psychol* 2008;8:765–77.

- 22 Cohen H. How to write a patient case report. *Am J Health Syst Pharm* 2006;63:1888–92.
- 23 Sorinola O, Olufowobi O, Coomarasamy A, *et al.* Instructions to authors for case reporting are limited: a review of a core journal list. *BMC Med Educ* 2004;4:4.
- 24 Bannas P. Instructions for radiological case reports. Anleitung Zum Schreiben Eines Radiologischen Fallberichts. *Rofo* 2017;189:333–8.
- 25 Stasiak CES, Nigri DH, Cardoso FR, *et al.* Case report: incidental finding of COVID-19 infection after positron emission tomography/CT imaging in a patient with a diagnosis of Histoplasmosis and recurring fever. *Am J Trop Med Hyg* 2021;104:1651–4.
- 26 Misra P, Kirpalani A, Leung G, *et al.* The role of thrombectomy and diffusion-weighted imaging with MRI in post-transplant renal vein thrombosis: a case report. *BMC Nephrol* 2017;18:224.
- 27 Ucpinar BA, Sahin C, Yanc U. Spontaneous pneumothorax and subcutaneous emphysema in COVID-19 patient: case report. *J Infect Public Health* 2020;13:887–9.
- 28 Tran TA, Cezar R, Frandon J, *et al.* CT scan does not make a diagnosis of COVID-19: a cautionary case report. *Int J Infect Dis* 2020;100:182–3.
- 29 Chen J, Peng S, Zhang B, *et al.* n.d. An uncommon manifestation of COVID-19 pneumonia on CT scan with small cavities in the lungs: A case report. *Medicine*;99:e21240.
- 30 Li N, Song Y-M, Zhang X-D, *et al.* Pseudoileus caused by primary visceral myopathy in a Han Chinese patient with a rare Myh11 Mutation: a case report. *World J Clin Cases* 2022;10:12623–30.
- 31 Xiang D, He J, Fan Z, *et al.* Situs Inversus totalis with solid pseudopapillary pancreatic tumor: a case report and review of literature. *Medicine (Baltimore)* 2018;97:e0205.
- 32 Prattes J, Valentin T, Hoenigl M, *et al.* Invasive pulmonary Aspergillosis complicating COVID-19 in the ICU - a case report. *Med Mycol Case Rep* 2021;31:2–5.
- 33 Chen C-W, Lee C-H, Huang T-Y, *et al.* Vaginitis: a rare diagnosis mimicking inguinal hernia: a case report. *BMC Urol* 2019;19:27.
- 34 Jadu FM, Pharoah MJ, Lee L, *et al.* Central giant cell granuloma of the mandibular condyle: a case report and review of the literature. *Dentomaxillofac Radiol* 2011;40:60–4.
- 35 Huang S, He F. Cervical cancer invading the uterine corpus and sigmoid colon: a case report. *Case Rep Womens Health* 2022;36:e00455.
- 36 Basja AT, Atmaja MHS. CT imaging of malignant peritoneal mesothelioma: a case report. *Radiol Case Rep* 2022;17:1256–60.
- 37 Maini A, Tomar G, Khanna D, *et al.* Sino-orbital mucormycosis in a COVID-19 patient: a case report. *Int J Surg Case Rep* 2021;82:105957.
- 38 Bosmans JM, Luyckx E, Broeckx BJ, *et al.* Radiologists as co-authors in case reports: does their involvement make a difference *Acta Radiol* 2020;61:338–43.
- 39 Nair A, Sreaton NJ, Holemans JA, *et al.* The impact of trained radiographers as concurrent readers on performance and reading time of experienced radiologists in the UK lung cancer screening (UKLS) trial. *Eur Radiol* 2018;28:226–34.
- 40 Zhang X, Song W, Liu X, *et al.* CT image of novel coronavirus pneumonia: a case report. *Jpn J Radiol* 2020;38:407–8.
- 41 Schachner ER, Spieler B. Three-dimensional (3d) lung segmentation for diagnosis of COVID-19 and the communication of disease impact to the public. *BMJ Case Rep* 2020;13:e236943.
- 42 Pan Y, Tao Y, Fu C, *et al.* Assessment of PET/CT in multifocal myeloid Sarcomas with loss of Tet2: a case report and literature review. *Int J Clin Exp Pathol* 2015;8:13630–4.
- 43 Jansz J, Tran HW, Sweiss NJ. Pitfalls in the diagnosis and management of an unusual presentation of clinically amyopathic dermatomyositis: a case report written with the assistance of ChatGpt. *Cureus* 2023;15:e41879.
- 44 Zhang X, Hu Y, Tian C, *et al.* Disseminated Cryptococcosis mimicking malignant lymphoma on 18F-FDG PET/CT: A case report. *Medicine* 2022;101:e31374.
- 45 Bakia JM, Ovaere S, Dijkman FP, *et al.* The dangers of the bread clip - CT imaging and management: a case report. *Acta Chir Belg* 2017;117:264–6.
- 46 Suzuki S, Kurokawa R, Tsuruga T, *et al.* CT, MRI, and FDG-PET imaging findings of low-grade extrauterine endometrial stromal sarcoma arising from the mesentery: a case report. *Radiol Case Rep* 2021;16:2774–9.
- 47 Cegla P, Spychala A, Marszalek A, *et al.* Atypical spleen tuberculosis in a melanoma patient accidentally detected during a 18F-FDG PET/CT study: case report. *Mol Clin Oncol* 2018;8:89–92.
- 48 Filli L, Huber A, Husain NA-H. Symptomatic lipoma of the internal auditory canal: CT and MRI findings. *Neuroradiol J* 2014;27:479–81.
- 49 Qiu Y, Chen Z, Yang Q, *et al.* n.d. Case report: a rare case of retroperitoneal kaposiform hemangioendothelioma with spinal involvement without abnormal platelet count in 18F-FDG PET/CT. *Front Med*;9.
- 50 Kogan M, Castillo CC, Barber MS. Chronic rhinosinusitis and irritable bowel syndrome: a case report. *Integr Med (Encinitas)* 2016;15:44–54.
- 51 Singh N, Fratesi J. Chest CT imaging of an early Canadian case of COVID-19 in a 28-year-old man. *CMAJ* 2020;192:E455.
- 52 Spaltenstein M, Humbert F, Vu D-L, *et al.* A case report of CT-diagnosed renal infarct secondary to Syphilitic Aortitis. *BMC Infect Dis* 2017;17:520.
- 53 Meira J, Madeira C, Falcão-Reis F, *et al.* Sustained control from recurring non-infectious Uveitic macular edema with 0.19 mg fluocinolone acetonide intravitreal implant - a case report. *Ophthalmol Ther* 2019;8:635–41.
- 54 Pizzo F, Di Nora A, Di Mari A, *et al.* Case report: incidence and prognostic value of brain MRI lesions and elevated cerebrospinal fluid protein in children with Guillain-Barré syndrome. *Front Neurol* 2022;13:885897.