



## Appendiceal neuroendocrine tumors in children and adolescents: The European Cooperative Study Group for Pediatric Rare Tumors (EXPeRT) diagnostic and therapeutic recommendations

Calogero Virgone, MD, PhD<sup>a,b,\*</sup>, Jelena Roganovic, MD, PhD<sup>c</sup>, Guido Rindi, MD, PhD<sup>d,e,f</sup>, Michaela Kuhlen, MD<sup>g</sup>, Jan Jamsek, MD<sup>h</sup>, Paraskevi Panagopoulou, MD<sup>i</sup>, Viera Bajciová, MD<sup>j</sup>, Tal Ben-Ami, MD<sup>k</sup>, Martine F. Raphael, MD<sup>l</sup>, Guido Seitz, MD<sup>m,n</sup>, Patrizia Dall'Igna, MD<sup>a,b</sup>, Sheila C.E.J. Terwisscha van Scheltinga, MD, PhD<sup>o</sup>, Miranda P. Dierselhuis, MD, PhD<sup>o</sup>, Ramon R. Gorter, MD, PhD<sup>p</sup>, Said Bachiri, MD, PhD<sup>p</sup>, Ulrich-Frank Pape, MD, PhD<sup>q</sup>, Florent Guérin, MD, PhD<sup>r</sup>, Ines B. Brecht, MD<sup>s</sup>, Brice Fresneau, MD, PhD<sup>t,u</sup>, Daniel Orbach, MD<sup>v</sup>, Antje Redlich, MD<sup>x</sup>

<sup>a</sup> Department of Women's and Children's Health, University of Padua, Padua, Italy

<sup>b</sup> Pediatric Surgery, University Hospital of Padua, Padua, Italy

<sup>c</sup> Department of Hematology and Oncology, Children's Hospital Zagreb, Zagreb, Croatia

<sup>d</sup> Section of Anatomic Pathology, Department of Life Sciences and Public Health, Università Cattolica del Sacro Cuore, Rome, Italy

<sup>e</sup> Anatomic Pathology Unit, Department of Woman and Child Health Sciences and Public Health, Fondazione Policlinico Universitario Agostino Gemelli – IRCCS, Rome, Italy

<sup>f</sup> ENETS Center of Excellence, Fondazione Policlinico Universitario A. Gemelli IRCCS-Università Cattolica del Sacro Cuore, Rome, Italy

<sup>g</sup> Pediatrics and Adolescent Medicine, University of Augsburg, Augsburg, Germany

<sup>h</sup> Department of Nuclear Medicine, University Medical Centre Ljubljana, Ljubljana, Slovenia

<sup>i</sup> Fourth Pediatric Department, Papageorgiou General Hospital, Medical School, Aristotle University of Thessaloniki, Thessaloniki, Greece

<sup>j</sup> Department of Pediatric Oncology, Children's University Hospital, Brno, Czech Republic

<sup>k</sup> Pediatric Hematology-Oncology Unit, Kaplan Medical Center, Rehovot, Israel

<sup>l</sup> Department of Pediatric Oncology, Emma Children's Hospital, Amsterdam UMC Location University of Amsterdam, Amsterdam, the Netherlands

<sup>m</sup> Department of Pediatric Urology, University Hospital Giessen-Marburg, Phillips University, Marburg, Germany

<sup>n</sup> Department of Pediatric Surgery, University Hospital Giessen-Marburg, Giessen, Germany

<sup>o</sup> Princess Máxima Center for Pediatric Oncology, Utrecht, the Netherlands

<sup>p</sup> Department of Pediatric Surgery, Emma Children's Hospital, Amsterdam UMC location University of Amsterdam, Amsterdam, the Netherlands

<sup>q</sup> Department of Internal Medicine and Gastroenterology, Asklepios Klinik St. Georg, Asklepios Tumorzentrum, Hamburg, Germany

<sup>r</sup> Department of Pediatric Surgery, Université Paris-Saclay, Assistance Publique Hôpitaux de Paris (AP-HP), Bicêtre Hospital, Le Kremlin-Bicêtre, France

<sup>s</sup> Pediatric Oncology and Hematology, University Children's Hospital, Tuebingen, Germany

<sup>t</sup> Gustave Roussy Cancer Center, Department of Children and Adolescents Oncology, Paris-Saclay University, Villejuif, France

<sup>u</sup> Paris-Saclay University, Paris-Sud University, Paris, France

<sup>v</sup> SIREDO Oncology Center (Care, Innovation and Research for Children, Adolescents and Young Adults with Cancer), Institut Curie, PSL University, Paris, France

<sup>x</sup> Pediatric Oncology Department, Otto von Guericke University Children's Hospital, Magdeburg, Germany

### ARTICLE INFO

#### Article history:

Accepted 2 May 2025

Available online 31 May 2025

### ABSTRACT

Neuroendocrine tumors of the appendix, formerly known as carcinoid tumors, represent a rare entity. They are slow-growing tumors, characterized by an indolent clinical course. In pediatric patients, the 5-year overall survival is estimated to be 100% and the event-free survival slightly less than 100%, with only one reported case of local relapse to date. Nevertheless, a proportion of these patients still undergo a second surgery, mostly represented by right hemicolectomy with mesenteric lymphadenectomy, in consideration of the presence of certain risk factors (size >1.5 or 2 cm; tumors of the appendiceal base with or without suspicious residuals, mesoappendiceal invasion, lymphovascular invasion, serosal breach). This approach represents an overtreatment of patients with a benign clinical course regardless of the presence of risk

\* Corresponding author: Calogero Virgone, MD, PhD, Pediatric Surgery, Department of Women's and Children's Health, University Hospital of Padua, Via Giustiniani 3, Padua 35128, Italy.

E-mail address: [calogero.virgone@unipd.it](mailto:calogero.virgone@unipd.it) (C. Virgone).

<https://doi.org/10.1016/j.surg.2025.109451>

0039-6060/© 2025 The Author(s). Published by Elsevier Inc. This is an open access article under the CC BY-NC-ND license (<http://creativecommons.org/licenses/by-nc-nd/4.0/>).

factors and/or whether a second surgery is performed. National recommendations for diagnosis, treatment, and follow-up of neuroendocrine tumors of the appendix in pediatric age are available in France, Italy, and Germany, but international consensus is lacking. This review presents the internationally harmonized recommendations for the diagnosis and treatment of neuroendocrine tumors of the appendix in children and adolescents, established by the European Cooperative Study Group for Pediatric Rare Tumors group.

© 2025 The Author(s). Published by Elsevier Inc. This is an open access article under the CC BY-NC-ND license (<http://creativecommons.org/licenses/by-nc-nd/4.0/>).

## Introduction

Neuroendocrine tumors of the appendix (aNETs), formerly known as carcinoid tumors, are rare, slow-growing tumors characterized by an indolent clinical course. Although rare in children and adolescents,<sup>1</sup> aNETs are the most common gastrointestinal epithelial tumors in this age group and are usually an incidental finding at histology after an appendectomy.<sup>2,3</sup>

The precise incidence in relation to the total number of appendectomies is not available. In adults, it has been estimated to be approximately 0.2%, whereas in children, the frequency has been reported to be 0.17% of all appendectomies.<sup>4,5</sup> A recent study estimated an incidence rate of 0.4% of all appendectomies performed in 8 tertiary hospitals in the United States.<sup>6</sup> Therefore, the general incidence has been reported to range between 1:100,000 and 1.14:1,000,000 children per year.<sup>3,7,8</sup>

In a systematic review of a pediatric population that included a total of 958 published cases up to 2018, Njere et al<sup>4</sup> found a 100% overall survival (OS) and event-free survival (EFS). The same results were reported in a recent systematic review focused on “high-risk” cases (incomplete resection, tumor at base of appendix, grade 2 NET, lymphovascular or >3 mm mesoappendiceal invasion of tumor cells).<sup>9</sup> In both studies, these positive outcomes were obtained regardless of the type of treatment received after appendectomy. The majority of authors have suggested that the aggressive approach generally indicated in adults, represented by right hemicolectomy (RHC), may not be justified in young patients.<sup>2–4,9–11</sup>

National recommendations for diagnosis, treatment, and follow-up of aNETs in the pediatric age are available in France, Italy, and Germany,<sup>2,3,11</sup> but an international consensus is still missing. The European Cooperative Study Group for Pediatric Rare Tumors (EXPERT) began its activity in 2008 as a collaboration between national cooperative groups dedicated to very rare tumors (VRT) in children within the International Society of Pediatric Oncology – European Branch (SIOPE). From the beginning, it was recognized that in pediatric VRT randomized or even observational prospective clinical trials were very difficult to perform because of the small number of affected patients. With this limitation, EXPERT worked to establish recommendations for a series of VRT occurring in pediatric age.<sup>12–21</sup>

The aim of this article is to establish international recommendations for the diagnosis and treatment of children and adolescents with aNETs according to the Consensus Conference Standard Operating Procedure methodology with definition of levels of evidence (Level I to V) and grades of recommendation (Grade A to E).<sup>22</sup>

## Background: Therapeutic approach in adults and risk factors

The European Neuroendocrine Tumor Society (ENETS) guidelines, last published in 2023, recommend appendectomy alone for a well-differentiated aNET  $\leq 2$  cm and RHC in tumors >2 cm, or in tumors >1 cm and <2 cm with unclear margins, and high G2 and G3.<sup>23</sup> In addition, it is suggested that ileocecal resection may be an alternative to RHC in pediatric patients.<sup>23</sup>

The North American Neuroendocrine Tumor Society (NANETS) guidelines, last published in 2010, recommend RHC in adult patients

when there is evidence of a tumor invasion at the base, size >2 cm, R1 resection, lymphovascular and mesoappendiceal invasion, intermediate- to high-grade tumors, mixed histology, and nodal involvement at appendectomy. However, they do not recommend applying these guidelines to the pediatric population.<sup>24</sup>

Nevertheless, data supporting a less-aggressive approach have been reported since early 2000, even in adults.<sup>25–30</sup> Pawa et al<sup>31</sup> in 2017 highlighted how the current adult guidelines are effective in identifying patients at risk of nodal metastases, but at the same time these authors emphasized that the impact of nodal disease on EFS and OS is still uncertain. Similar results have been shared by mono-institutional analyses performed in national centers of excellence.<sup>32–35</sup> A European retrospective multi-institutional cohort study found that RHC does not confer any advantage after appendectomy in completely resected aNETs of 1–2 cm in size and that regional lymph node metastases are clinically irrelevant, although present in up to 20%.<sup>36</sup> The appropriate approach for incompletely resected well-differentiated aNETs and/or larger than 2 cm remains elusive, given the fact that, also in these subgroups, regional lymph node metastases may be similarly of no clinical significance.<sup>32–38</sup>

In the past, several risk factors were adopted from previous experiences in adults to treat pediatric cases of aNETs, and this has led to an overtreatment of these patients.

- Serosal breach/tumor rupture, mesoappendiceal invasion, lymphovascular invasion: These findings may be present in up to 20% of cases,<sup>2,3,11</sup> alone or in combination. Although they are considered risk factors in adults, there is no evidence they may indicate a greater risk in the pediatric age group.<sup>2–11</sup>
- Tumor size >2 cm: Although tumor size is considered the main prognostic factor, as surrogate marker for predicting micro-metastases in regional lymph nodes, it remains to be established a precise pediatric cut-off that requires treatments more intensive than the simple appendectomy.<sup>2,3,9–11</sup>
- Incomplete/marginal resection or tumor located to the base of the appendix: Approximately 6–7% of aNETs are located at the base of the appendix and/or are treated with a marginal resection. Traditionally, in these patients a re-excision has been performed: in those who underwent RHC or a limited cecal resection, residual tumors or positive nodes were detectable only in a minority of cases (approximately 6–10%).<sup>2–4,9,39</sup> In addition, patients with the same indications who were observed without second surgery did not experience local or distant relapse and are in complete remission even at longer follow-up. Furthermore, the presence of nodal histologic involvement does not correlate to the pediatric patient's outcome and should not be used as a surrogate marker to decide the need of RHC.<sup>2–4,9,39</sup>
- Nodal involvement at appendectomy: A total of 1–2% of cases may have positive nodes found at appendectomy when the mesoappendix is removed together with the appendix. However, there is no evidence that nodal microfoci of aNET may lead to lower EFS and OS in children, and the majority of reported cases was only observed with an uneventful follow-up.<sup>2–4,9,11,39</sup>

- High-grade tumors: G3 aNETs are extremely rarely encountered in children and adolescents, with only 2 patients have been reported so far. Both of these patients had a positive outcome following appendectomy alone.<sup>40</sup>

### Specific consideration on aNETs in pediatric patients

aNETs, both in adult and pediatric patients, seem to be indolent tumors, which may involve locoregional lymph nodes in a discreet rate (up to 20% in adult series, and 10–15% in pediatric patients) and exceptionally spread to distant sites. However, the clinical course appears to be remarkably better in children and adolescents, since metastatic spread and cancer-specific mortality are virtually absent in this age group. To date, there are more than 1,000 published cases with no reported mortality and an estimated relapse rate of less than 0.1%.<sup>4,40,41</sup> So far, only 2 cases of relapsed and metastatic aNETs have been reported. A Polish case series included a patient who experienced 2 local recurrences (both successfully treated with surgery only), and, in a German case series on the basis of insurances databases, an adolescent with distant metastatic spread at diagnosis (with very limited available data).<sup>40,41</sup> In the series published by Virgone et al.,<sup>3</sup> only 2 patients underwent a second surgery, as the result of suspected liver metastasis and serotonin receptor imaging (SRI)-positive nodes: the liver lesion was found to be a focal nodular hyperplasia and the node was positive for NET micrometastases.

Indolent metastases involving regional lymph nodes have been reported.<sup>2–4,9,11,39</sup> These are represented by microscopic foci of NETs, and their prognostic value is still to be determined, but not related to distant tumor spread.<sup>2–4,9,39</sup> The excellent prognosis and event-free follow-up of these patients highlight the need to optimize and reduce therapeutic and diagnostic procedures after appendectomy.

The diagnostic workup and the postappendectomy follow-up strategy in children and adolescents have not yet been standardized, and very few detailed recommendations have been developed. Imaging (both at diagnosis or during follow-up) seems to have a limited role. The resolution of ultrasound, computed tomography (CT), and magnetic resonance imaging (MRI) is hardly useful to detect residual disease smaller than 1 cm or nodal micrometastasis (a metastatic focus measuring between 0.2 and 2.0 mm).<sup>42,43</sup> Similarly, SRI techniques, such as [<sup>68</sup>Ga]Ga-DOTA-TOC and [<sup>68</sup>Ga]Ga-DOTA-TATE, might miss or underdetect lymph node micrometastases, and reports of the pitfalls of SRI have been published.<sup>44–49</sup> In addition, [<sup>68</sup>Ga]Ga-DOTA-TOC, [<sup>68</sup>Ga]Ga-DOTA-TATE positron emission tomography (PET)-CT, and other SRI techniques usually are not useful in low-stage aNETs because most follow-up SRI-PET studies in low-risk patients are negative, and the risk of false-positive findings should not be minimized.<sup>44–49</sup>

Laboratory investigations traditionally have included the measurement of the urinary levels of 5-hydroxyindoleacetic acid (5-HIAA), and the serum levels of chromogranin A (CgA) and neuron-specific enolase (NSE).<sup>50</sup> Both 5-HIAA and CgA may be elevated in case of bulky residual disease or large liver metastases,<sup>51</sup> and NSE in high-grade tumors,<sup>51,52</sup> but none of these conditions have occurred in the pediatric population. Current data demonstrate that the vast majority of patients are cured with appendectomy alone, rendering further surgical approaches to prevent local or distant recurrences or to benefit greater EFS or OS unnecessary.<sup>2–4,9,39,53,54</sup> Different second surgeries may be performed with different aims and results. An RHC may improve local control, and it allows a complete regional lymphadenectomy. An ileocecal resection may improve local control and it

allows only a partial regional lymphadenectomy, whereas a partial cecectomy (or pull string-suture removal) is aimed at local control only.

The national groups of Italy (Tumori Rari in Età Pediatrica; REP) and France (French Very Rare Tumors Committee; FRACTURE) did not suggest RHC or other second surgery for any case, even when the size of the tumor exceeded 2 cm. The German group (German Society for Paediatric Oncology and Haematology—Malignant Endocrine Tumours; GPOH-MET), which used to recommend RHC for tumors >1.5 cm, recently published an analysis in which they demonstrated that neither tumor size >1.5 cm nor other associated risk factors correlated with disease recurrence or secondary metastatic spread in the subgroup of patients treated with appendectomy only. In 19 children with R1, R2, or unclear resection status, no residual tissue of the primary tumor was detected after second surgery.<sup>39</sup>

### EXPERT consensus recommendations

The risk factors for regional indolent nodal involvement that could be taken into consideration in the pediatric population are R1/microscopic residuals (tumors located to the base of the appendix); size >2 cm; grade >2; positive nodes at the time of appendectomy; suspicious secondary lesions found at postoperative imaging [Level IV; Grade B]. Other risk factors (lymphovascular invasion, serosal breach—perforated appendix—or tumor rupture, invasion of the mesoappendix) as reported by adult guidelines do not to apply to the pediatric population [Level III; Grade E].

Discussion by an MDT is highly recommended in case of R1 resection, tumors larger than 2 cm, high-grade lesions, neuroendocrine carcinoma (NEC) and mixed neuroendocrine non-neuroendocrine neoplasms (MiNEN), and in those with suspicious residual at the postappendectomy investigations (imaging and laboratory assessment), when performed. [Level V; Grade B].

### Diagnosis and initial assessment

aNETs are mostly diagnosed by the pathologist as an incidental finding, after the appendix is removed because of appendicitis or as a side procedure performed during another abdominal surgery.

#### Pathology

aNETs are classified according to the most recent *WHO Classification of Tumours, 5th Edition, Endocrine and Neuroendocrine Tumours*,<sup>55</sup> and staged according to the AJCC/ENETS staging system ninth edition.<sup>56</sup> Careful histopathologic evaluation should be undertaken, and doubtful cases should be referred for second opinion to tertiary centers [Level IV; Grade A].

The entire appendix should be processed [Level IV; Grade A]: conventional hematoxylin and eosin stain and immunohistochemistry for CgA, synaptophysin, and Ki-67 (MIB-1 clone) should be performed to allow proper grading, staging, and margin assessment.<sup>57</sup> Other immunohistochemistry may be performed and includes hormones (serotonin, glicentin, and peptide YY) for distinguishing serotonin-producing enterochromaffin cell compared with L-type cell tumors and somatostatin receptor type 2/5.

The pathologic report should contain the following information: type of resection, tumor site, tumor size and tumor type (NET, NEC, MiNEN), grade,<sup>57</sup> stage,<sup>56</sup> mitotic index and Ki-67% in clear, infiltration level, resection margin(s) status, invasion of vessels (vascular and lymphatic) and nerves, number of lymph nodes, and number of positive lymph nodes<sup>58</sup> [Level IV; Grade A]. Clear margins are defined as the presence of at least 1 mm of nonmalignant

tissue between the tumor and the surgical margin following en bloc resection without tumor spillage.<sup>59</sup>

**Imaging**

In almost all pediatric patients, regional abdominal nodal micrometastases are the unique possible target and, because the resolution of both conventional and functional imaging is suboptimal for this aim, there is no evidence to support the routine use of both conventional and SRI techniques [Level IV; Grade E].

A cautious approach can be considered for patients with 1 or a combination of risk factors. A postoperative abdominal MRI (in case of suspicious microscopic residuals, size >2 cm, positive nodes found at the time of appendectomy), SRI (in case of tumor grade >2 or NEC, suspicious microscopic residuals), or PET/MRI-CT (tumor grade >2 or NEC, suspicious microscopic residuals) are not routinely recommended here, but can be performed at discretion of the treating physician and/or following multidisciplinary team (MDT) discussion [Level IV; Grade C].

**Additional assessment**

No serum or urinary marker measurement is recommended in the initial staging of these patients [Level IV; Grade D].

**Therapeutic recommendations after appendectomy**

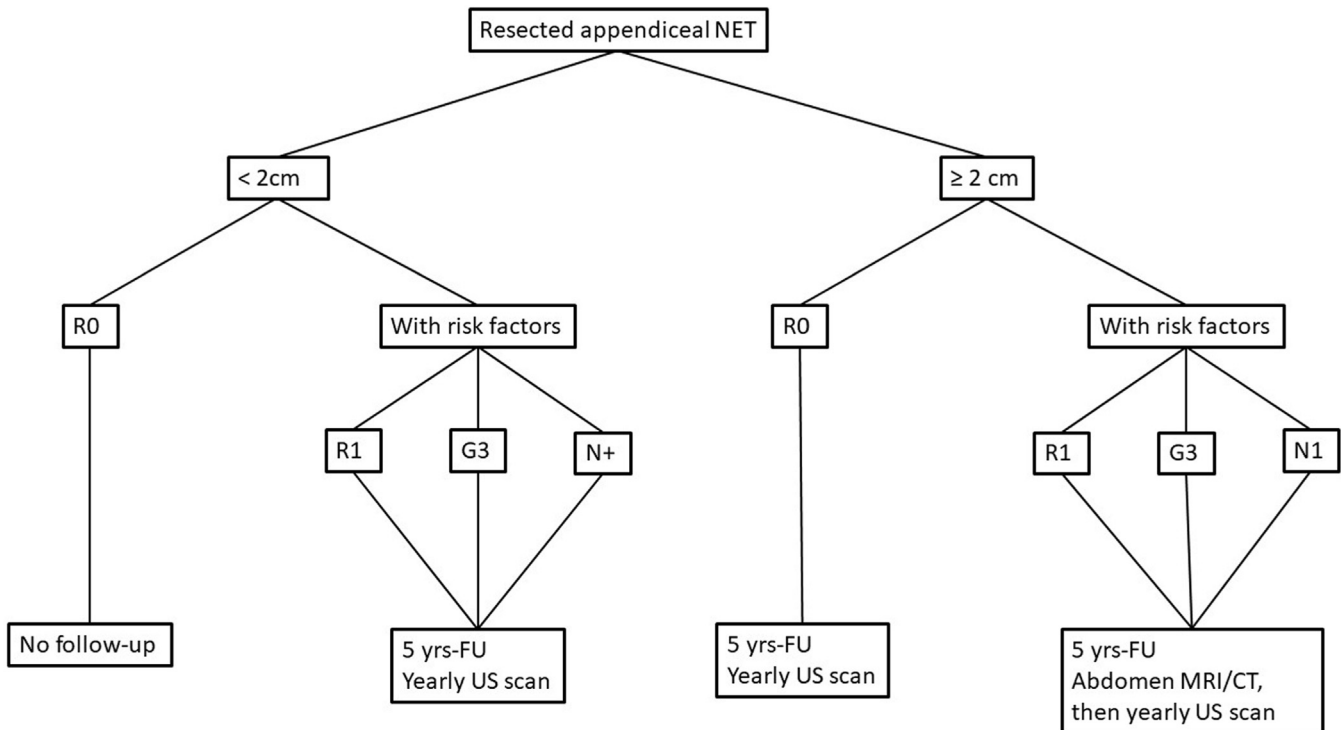
Appendectomy alone seems to be curative in all pediatric patients with aNETs, irrespectively of presenting risk factors, and a second surgery should be reserved only to a highly selected subgroup of patients after MDT discussion [Level III; Grade A] (Figure 1; Tables I and II).

**aNETs without risk factors (<2 cm, R0)**

In this group of patients, a second surgery is discouraged because it does not provide benefits in terms of OS and EFS. In particular, tumors between 1 and 2 cm in major diameter are properly cured by appendectomy alone, and the suggestion to treat these patients considering their younger age as a risk factor, as argued in the ENETS guidelines, is not supported by clinical evidence [Level III; Grade E].

**aNETs with risk factors**

- Serosal breach/tumor rupture, mesoappendiceal invasion, lymphovascular invasion: Appendectomy alone should be considered curative in these patients [Level III; Grade A].
- Tumor size >2 cm: Appendectomy alone should be considered curative in these patients [Level IV; Grade A].
- Incomplete/marginal resection or tumor located to the base of the appendix: Reported data suggest that appendectomy alone is sufficient, and second surgeries should be deemed unnecessary [Level IV; Grade D]. MDT discussion is advised on a local and/or on a national level, to evaluate the role of limited complementary cecectomy/ileocecal resection in case of R1 resection [Level IV; Grade B].
- Nodal involvement at appendectomy: Appendectomy alone is sufficient, and second surgeries should be deemed unnecessary [Level IV; Grade E].
- Suspicious nodal or distant lesions (at diagnosis or follow-up): Appendectomy alone may be considered sufficient, even when nodal metastases are suspected) [Level IV; Grade B]. Biopsy or second surgery of distant lesions may be indicated when clinical and radiologic data do not rule out distant metastases. However, a central review (or second review) of the initial diagnosis and MDT discussion are always recommended on a local and/or on a national level [Level IV; Grade B].



**Figure 1.** Postappendectomy treatment flowchart—EXPeRT group proposal. CT, computed tomography; EXPeRT, European Cooperative Study Group for Pediatric Rare Tumors; FU, follow-up; MRI, magnetic resonance imaging; NET, neuroendocrine tumors of the appendix; US, ultrasonography.

**Table I**

Summary of the EXPeRT recommendations for treatment of aNETs compared with current adult guidelines

Society	aNETs <1 cm	aNETs >1 cm and <2 cm	aNETs >2 cm
EXPeRT (2025)	Appendectomy alone. MDT discussion recommended: R1, G3	Appendectomy alone. MDT discussion recommended: R1, G3	Appendectomy alone. MDT discussion recommended: R1, G3
ENETS (2024) <sup>23</sup>	RHC recommended: R1 MDT discussion recommended: High G2	RHC recommended: R1 Consider RHC: High G2 and G3	RHC recommended in all cases (for pediatric age ileocecal resection as an alternative)
NANETS (2010) <sup>24</sup>	RHC recommended: R1, base, lymphovascular or mesoappendiceal invasion	RHC recommended: R1, base, lymphovascular or mesoappendiceal invasion G2 or more, N1	RHC recommended in all cases
JNETS (2021) <sup>60</sup>	RHC recommended: R1, G2 or more, lymphovascular invasion	RHC recommended: size >15.5 mm, R1, G2 or more, lymphovascular invasion	RHC recommended in all cases
French Intergroup- TNCD (2020) <sup>61</sup>	Consider RHC: R1	Consider RHC: suspected N1 mesoappendiceal invasion >3 mm, lymphovascular invasion, G2 or more, R1 (base)	RHC recommended in all cases

aNETs, neuroendocrine tumors of the appendix; ENETS, European Neuroendocrine Tumor Society; EXPeRT, European Cooperative Study Group for Pediatric Rare Tumors; JNETS, Japanese Neuroendocrine Tumor Society; MDT, multidisciplinary team; NANETS, North American Neuroendocrine Tumor Society; RHC, right hemicolectomy; TNCD, Thésaurus National de Cancérologie Digestive.

**Table II**

Summary of the EXPeRT recommendations for follow-up of aNETs compared with current adult guidelines

Society	Indication for FU	Methods (and duration)
EXPeRT (2025)	<2 cm: R1 N1 G3 >2 cm with or w/o risk factors	<2 cm and >2 cm w/o risk factor: yearly abdominal US + clinical evaluation (5 yr) >2 cm with risk factors: Abdominal MRI/CT then yearly abdominal US + clinical evaluation (5 yr)
ENETS (2024) <sup>62</sup>	<2 cm: G1-2 non resected, or G3 >2 cm	<2 cm G1-2 non resected, or G3, and >2 cm G1-2: 5-HIAA, CgA (every 3–6 mo), CT/MRI/US (every 3–12 mo), SRI (every 24 mo) >2 cm G3/NEC: HIAA, CgA or other relevant hormones (every 3 mo), CT/MRI/US (every 2–3 mo), SRI (every 12–24 mo), FDG-PET (every 12–24 mo)
NANETS (2010) <sup>24</sup>	Size 1–2 cm: N1, lymphovascular or mesoappendiceal invasion, intermediate or high grade Size >2 cm	interval history, physical examination, CgA, and 5-HIAA, CT or MRI, octreotide scintigraphy as clinically indicated (every 6 to 12 mo for at least 7 yr)
French Intergroup- TNCD (2020) <sup>61</sup>	<2 cm: N1 after colectomy and lymphadenectomy <2 cm	Morphologic imaging and nuclear imaging (after 3–6 mo), morphologic imaging (every 6–12 mo for 5 yr, then every 12–24 mo for 10 yr and then every 5 yr). US may be an alternative; Ga-DOTA-PET if clinical recurrence is suspected.

5-HIAA, 5-hydroxyindoleacetic acid; aNETs, neuroendocrine tumors of the appendix; CgA, chromogranin A; CT, computed tomography; ENETS, European Neuroendocrine Tumor Society; EXPeRT, European Cooperative Study Group for Pediatric Rare Tumors; FU, follow-up; JNETS, Japanese Neuroendocrine Tumor Society; MDT, multidisciplinary team; MRI, magnetic resonance imaging; NANETS, North American Neuroendocrine Tumor Society; PET, positron emission tomography; RHC, right hemicolectomy; SRI, serotonin receptor imaging; TNCD, Thésaurus National de Cancérologie Digestive; US, ultrasonography.

- Grade 3: Appendectomy alone may be considered sufficient in most cases, and no second surgeries should be necessary [Level V; Grade B]. MDT discussion is always recommended on a local, and/or on a national level, if needed, and when other risk factors are present (R1, size >2 cm) [Level V; Grade B].

#### aNETs with local relapse

Complete tumor resection of the relapse should be first considered as the treatment of choice [Level V; Grade C]. MDT discussion is always recommended on a local and/or on a national level [Level V; Grade B].

#### Recommendations for follow-up

The traditional follow-up investigations adopted for pediatric aNETs have been variably used in published case series. Current evidence demonstrates that conventional imaging and functional imaging are not useful in these patients. The same evidence applies to serum (NSE, CgA) and/or urine markers (5-HIAA).

There is no evidence to support the use of imaging techniques during follow-up and it is therefore discouraged also in these patients [Level IV; Grade E].

There is no evidence to support the measurement of serum and/or urinary markers during follow-up, and it is therefore discouraged also in these patients [Level IV; Grade E].

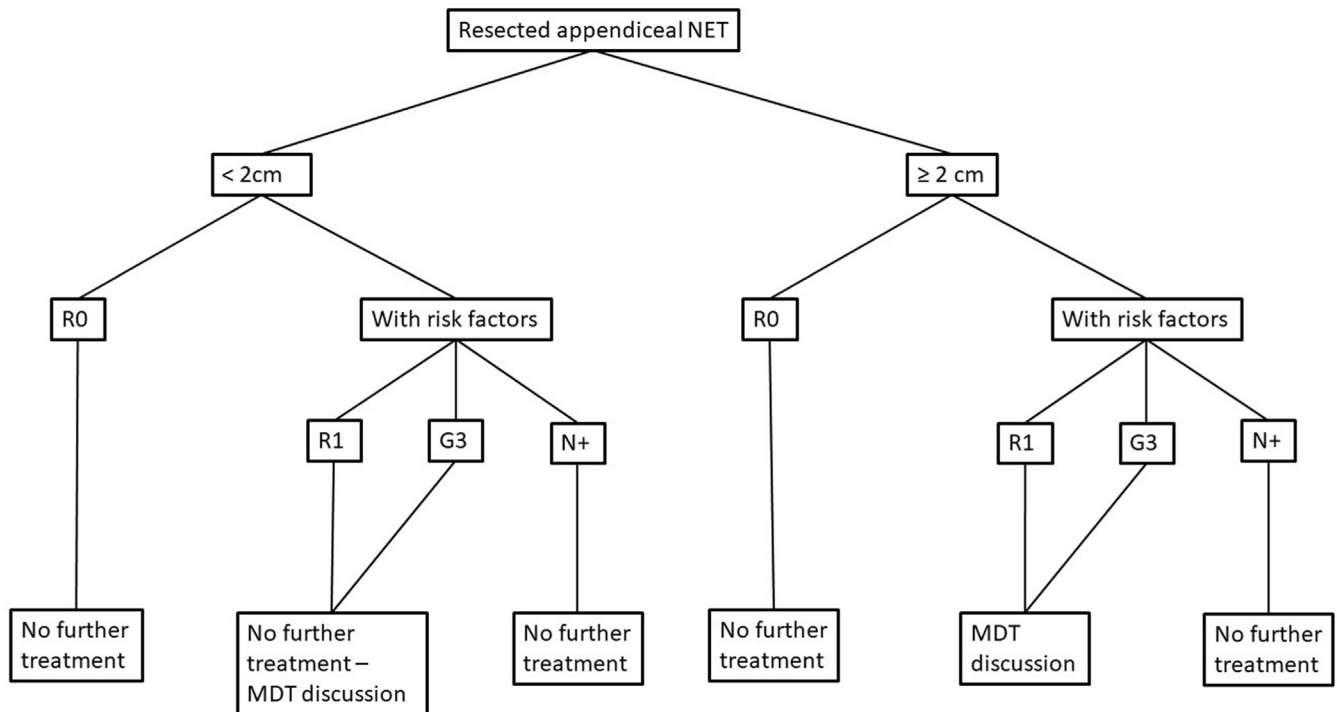
The length of follow-up has traditionally been recommended for 5–10 years, except for those cases with R0 tumors <1 cm, and tumors between 1 and 2 cm in size with no lymph node metastases at second surgery. This suggests that very few patients should be followed-up for 5 (or 10) years after diagnosis, and that both imaging and marker assay should be used in a very limited subset of patients.

The “historical” risk factors that have been taken into consideration so far, and widely discussed in the introductory section are not able to identify patients at risk of an event, as events such as relapse, progression, or tumor-related death are unlikely in pediatric aNETs.

Although it is not clear how to define a risk stratification for eligibility to follow-up, it is evident that routine surveillance should not rely on markers and functional imaging, since the vast majority of pediatric aNETs are low-stage tumors.

EXPeRT follow-up recommendations [Level IV; Grade C] are as follows (Figure 2):

- aNETs <2 cm that have been completely resected (R0) and without other risk factors (G3, N1): no follow-up is recommended;
- aNETs  $\geq$ 2 without risk factors: 5 years of follow-up including yearly clinical evaluation and abdominal ultrasound;
- aNETs <2 cm with risk factors (R1, G3, N1): 5 years of follow-up including yearly clinical evaluation and abdominal ultrasound;



**Figure 2.** Follow-up flowchart—EXPeRT group proposal. EXPeRT, European Cooperative Study Group for Pediatric Rare Tumors; MDT, multidisciplinary team; NET, neuroendocrine tumors of the appendix.

- aNETs  $\geq 2$  cm with additional risk factors (R1, G3, N1): post-operative abdominal MRI (or CT) scan (SRI-PET only in case of equivocal MRI/CT findings), and 5 years of follow-up including yearly clinical evaluation and abdominal ultrasound.

#### Limitations of available evidence and open questions remained

The limited availability of evidence in pediatric aNETs (especially in those  $>2$  cm, high-grade, or incompletely resected) hampers the establishment of more precise stratification, primarily due to the lack of robust data on long-term follow-up. Although this has minimal impact on treatment after appendectomy (which is likely unnecessary), it makes it rather difficult for the time being to reduce the duration and intensity of follow-up.

#### Funding/Support

The authors received no funding for this work. The French FRACTURE group is supported by “SFCE - Enfants Cancers et Santé.” The German STEP- and MET-Registries are supported by the German Childhood Cancer Foundation. The Italian TREP Registry has been partially supported by Fondazione Giovanni Celeghini, ONLUS.

#### Conflict of Interest/Disclosure

The authors have no relevant financial disclosures.

#### CRediT authorship contribution statement

**Calogero Virgone:** Conceptualization, Methodology, Data acquisition, Quality control of data and algorithms, Formal Analysis, Data Curation, Writing – Original Draft, Manuscript review. **Jelena Roganovic:** Conceptualization, Methodology, Data acquisition, Quality control of data and algorithms, Formal Analysis, Data Curation, Writing – Original Draft, Manuscript review. **Guido Rindi:** Data acquisition, Formal Analysis, Data Curation, Writing – Original Draft, Manuscript review. **Michaela Kuhlen:** Formal Analysis, Data Curation, Writing – Original Draft, Manuscript review. **Jan Jamsek:** Data acquisition, Formal Analysis, Data Curation, Manuscript review. **Paraskevi Panagopoulou:** Formal Analysis, Data Curation, Manuscript review. **Viera Bajciová:** Formal Analysis, Data Curation, Manuscript review. **Tal Ben-Ami:** Formal Analysis, Data Curation, Writing – Original Draft, Manuscript review. **Martine F. Raphael:** Formal Analysis, Data Curation, Manuscript review. **Guido Seitz:** Formal Analysis, Data Curation, Manuscript review. **Patrizia Dall'Igna:** Formal Analysis, Data Curation, Manuscript review. **Sheila C.E.J. Terwisscha van Scheltinga:** Formal Analysis, Data Curation, Manuscript review. **Miranda P. Dierselhuis:** Formal Analysis, Data Curation, Manuscript review. **Ramon R. Gorter:** Formal Analysis, Data Curation, Manuscript review. **Said Bachiri:** Formal Analysis, Data Curation, Manuscript review. **Ulrich-Frank Pape:** Formal Analysis, Data Curation, Writing – Original Draft, Manuscript editing, Manuscript review. **Florent Guérin:** Formal Analysis, Data Curation, Writing – Original Draft, Manuscript editing, Manuscript review. **Ines B. Brecht:** Formal Analysis, Data Curation, Manuscript review. **Brice Fresneau:** Formal Analysis, Data Curation, Manuscript review. **Daniel Orbach:** Conceptualization, Methodology, Data acquisition, Quality control of data and algorithms, Formal Analysis, Data Curation, Writing – Original Draft, Manuscript editing, Manuscript review. **Antje Redlich:** Conceptualization, Methodology, Data acquisition, Quality control of data and algorithms, Formal Analysis, Data Curation, Manuscript review.

## Supplementary materials

Supplementary material associated with this article can be found, in the online version, at [<https://doi.org/10.1016/j.surg.2025.109451>].

## References

- Ferrari A, Brecht IB, Gatta G, et al. Defining and listing very rare cancers of paediatric age: consensus of the joint action on rare cancers in cooperation with the European Cooperative Study Group for Pediatric Rare Tumors. *Eur J Cancer*. 2019;110:120–126.
- de Lambert G, Lardy H, Martelli H, Orbach D, Gauthier F, Guérin F. Surgical management of neuroendocrine tumors of the appendix in children and adolescents: a retrospective French multicenter study of 114 cases. *Pediatr Blood Cancer*. 2016;63:598–603.
- Virgone C, Cecchetto G, Alaggio R, et al. Appendiceal neuroendocrine tumours in childhood: Italian TREP project. *J Pediatr Gastroenterol Nutr*. 2014;58:333–338.
- Njere I, Smith LL, Thurairasa D, et al. Systematic review and meta-analysis of appendiceal carcinoid tumors in children. *Pediatr Blood Cancer*. 2018;65:e27069.
- Doede T, Foss HD, Waldschmidt J. Carcinoid tumors of the appendix in children—epidemiology, clinical aspects and procedure. *Eur J Pediatr Surg*. 2000;10:372–377.
- Zeineddin S, Aldrink JH, Bering J, et al. Multi-institutional assessment of the prevalence of neuroendocrine tumors in children undergoing laparoscopic appendectomy for acute appendicitis in the United States. *Pediatr Blood Cancer*. 2023;70:e30620.
- Parkes SE, Muir KR, Al Sheyyab M, et al. Carcinoid tumours of the appendix in children 1957–1986: incidence, treatment and outcome. *Br J Surg*. 1993;80:502–504.
- Duess JW, Lange A, Zeidler J, et al. Appendiceal carcinoids in children—prevalence, treatment and outcome in a large nationwide pediatric cohort. *Medicina (Kaunas)*. 2022;59:80.
- van Amstel P, Mahieu A, Bakx R, et al. Management and outcome of high-risk neuroendocrine tumors of the appendix in children; a systematic review. *Eur J Surg Oncol*. 2023;49:329–338.
- Simon CT, Ehrlich P, Hryhorczuk A, et al. Well-differentiated neuroendocrine tumors of the appendix in children and adolescents: a clinicopathologic study. *Pediatr Dev Pathol*. 2023;26:250–258.
- Boxberger N, Redlich A, Böger C, et al. Neuroendocrine tumors of the appendix in children and adolescents. *Pediatr Blood Cancer*. 2013;60:65–70.
- Bien E, Roganovic J, Krawczyk MA, et al. Pancreatoblastoma in children: EXPeRT/PARTNER diagnostic and therapeutic recommendations. *Pediatr Blood Cancer*. 2021;68(Suppl 4):e29112.
- Surun A, Schneider DT, Ferrari A, et al. Salivary gland carcinoma in children and adolescents: the EXPeRT/PARTNER diagnosis and treatment recommendations. *Pediatr Blood Cancer*. 2021;68(Suppl 4):e29058.
- Schneider DT, Orbach D, Ben-Ami T, et al. Consensus recommendations from the EXPeRT/PARTNER groups for the diagnosis and therapy of sex cord stromal tumors in children and adolescents. *Pediatr Blood Cancer*. 2021;68(Suppl 4):e29017.
- Virgone C, Roganovic J, Vorwerk P, et al. Adrenocortical tumours in children and adolescents: the EXPeRT/PARTNER diagnostic and therapeutic recommendations. *Pediatr Blood Cancer*. 2021;68(Suppl 4):e29025.
- Bisogno G, Sarnacki S, Stachowicz-Stencel T, et al. Pleuropulmonary blastoma in children and adolescents: the EXPeRT/PARTNER diagnostic and therapeutic recommendations. *Pediatr Blood Cancer*. 2021;68(Suppl 4):e29045.
- Ben-Ami T, Kontny U, Surun A, et al. Nasopharyngeal carcinoma in children and adolescents: the EXPeRT/PARTNER diagnostic and therapeutic recommendations. *Pediatr Blood Cancer*. 2021;68(Suppl 4):e29018.
- Ferrari A, Lopez Almaraz R, Reguerre Y, et al. Cutaneous melanoma in children and adolescents: the EXPeRT/PARTNER diagnostic and therapeutic recommendations. *Pediatr Blood Cancer*. 2021;68(Suppl 4):e28992.
- Stachowicz-Stencel T, Synakiewicz A, Cornet M, et al. Thymoma and thymic carcinoma in children and adolescents: the EXPeRT/PARTNER diagnostic and therapeutic recommendations. *Pediatr Blood Cancer*. 2021;68(Suppl 4):e29042.
- Di Carlo D, Fichera G, Dumont B, et al. Olfactory neuroblastoma in children and adolescents: the EXPeRT recommendations for diagnosis and management. *EJC Paediatric Oncol*. 2023;2:100136.
- Lemelle L, Flaadt T, Fresneau B, et al. NUT carcinoma in children and adolescents: the expert European standard clinical practice harmonized recommendations. *J Pediatr Hematol Oncol*. 2023;45:165–173.
- Dykewicz CA, Centers for Disease Control and Prevention (U.S.), Infectious Diseases Society of America, American Society of Blood and Marrow Transplantation. Summary of the guidelines for preventing opportunistic infections among hematopoietic stem cell transplant recipients. *Clin Infect Dis*. 2001;33:139–144.
- Kaltsas G, Walter T, Knigge U, et al. European Neuroendocrine Tumor Society (ENETS) 2023 guidance paper for appendiceal neuroendocrine tumours (aNET). *J Neuroendocrinol*. 2023;35:e13332.
- Boudreaux JP, Klimstra DS, Hassan MM, et al. The NANETS consensus guideline for the diagnosis and management of neuroendocrine tumors: well-differentiated neuroendocrine tumors of the jejunum, ileum, appendix, and cecum. *Pancreas*. 2010;39:753–766.
- Bamboot ZM, Berger DL. Is right hemicolectomy for 2.0-cm appendiceal carcinoids justified? *Arch Surg*. 2006;141:349–352.
- Assadi M, Kubiak R, Kaiser G. Appendiceal carcinoid tumors in children: does size matter? *Med Pediatr Oncol*. 2002;38:65–66.
- Yao JC, Hassan M, Phan A, et al. One hundred years after "carcinoid": epidemiology of and prognostic factors for neuroendocrine tumors in 35,825 cases in the United States. *J Clin Oncol*. 2008;26:3063–3072.
- Onyemkpa C, Davis A, McLeod M, Oyasiji T. Typical carcinoids, goblet cell carcinoids, mixed adenoneuroendocrine carcinomas, neuroendocrine carcinomas and adenocarcinomas of the appendix: a comparative analysis of survival profile and predictors. *J Gastrointest Oncol*. 2019;10:300–306.
- Mullen JT, Savarese DM. Carcinoid tumors of the appendix: a population-based study. *J Surg Oncol*. 2011;104:41–44.
- Guzman C, Boddhula S, Panneerselvam N, et al. Appendiceal carcinoid tumors: is there a survival advantage to colectomy over appendectomy? *J Gastrointest Surg*. 2020;24:1149–1157.
- Pawa N, Clift AK, Osmani H, et al. Surgical management of patients with neuroendocrine neoplasms of the appendix: appendectomy or more. *Neuroendocrinology*. 2018;106:242–251.
- Alabraba E, Pritchard DM, Griffin R, et al. The impact of lymph node metastases and right hemicolectomy on outcomes in appendiceal neuroendocrine tumours (aNETs). *Eur J Surg Oncol*. 2021;47:1332–1338.
- Holmager P, Willemoe GL, Nielsen K, et al. Neuroendocrine neoplasms of the appendix: characterization of 335 patients referred to the Copenhagen NET Center of Excellence. *Eur J Surg Oncol*. 2021;47:1357–1363.
- Storan D, Swan N, Swan K, et al. Clinical features and outcomes of appendiceal neuroendocrine tumours: 10-year audit from the Irish NET Centre of Excellence. *J Neuroendocrinol*. 2023;35:e13329.
- Nesti C, Bräutigam K, Benavent M, et al. Hemicolectomy versus appendectomy for patients with appendiceal neuroendocrine tumours 1–2 cm in size: a retrospective, Europe-wide, pooled cohort study. *Lancet Oncol*. 2023;24:187–194.
- Daskalakis K, Alexandraki K, Kassi E, et al. The risk of lymph node metastases and their impact on survival in patients with appendiceal neuroendocrine neoplasms: a systematic review and meta-analysis of adult and paediatric patients. *Endocrine*. 2020;67:20–34.
- Mehrvarz SA, Advani S, Halperin DM, et al. Regional lymph node involvement and outcomes in appendiceal neuroendocrine tumors: a SEER database analysis. *Oncotarget*. 2017;8:99541–99551.
- Toumpanakis C, Fazio N, Tiensuu Janson E, et al. Unmet needs in appendiceal neuroendocrine neoplasms. *Neuroendocrinology*. 2019;108:37–44.
- Kuhlen M, Kunstreich M, Pape UF, et al. Lymph node metastases are more frequent in paediatric appendiceal NET  $\geq 1.5$  cm but without impact on outcome—data from the German MET studies. *Eur J Surg Oncol*. 2024;50:108051.
- Panek M, Szymczak M, Stepaniuk M, et al. Radical surgical treatment of neuroendocrine tumors of the appendix in children—a Polish multicenter study. *Arch Med Sci*. 2021;17:1128–1131.
- Duess JW, Lange A, Zeidler J, et al. Appendiceal carcinoids in children—prevalence, treatment and outcome in a large nationwide pediatric cohort. *Medicina (Kaunas)*. 2022;59:80.
- Ronot M, Dioguardi Burgio M, Gregory J, et al. Appropriate use of morphological imaging for assessing treatment response and disease progression of neuroendocrine tumors. *Best Pract Res Clin Endocrinol Metab*. 2023;37:101827.
- Sundin A, Arnold R, Baudin E, et al. ENETS consensus guidelines for the standards of care in neuroendocrine tumors: radiological, nuclear medicine & hybrid imaging. *Neuroendocrinology*. 2017;105:212–244.
- Oberg K, Couvelard A, Delle Fave G, et al. ENETS consensus guidelines for standard of care in neuroendocrine tumours: biochemical markers. *Neuroendocrinology*. 2017;105:201–211.
- Saponjski J, Macut D, Sobic-Saranovic D, et al. Somatostatin receptor scintigraphy in the follow up of neuroendocrine neoplasms of appendix. *World J Clin Cases*. 2020;8:3697–3707.
- Carrasquillo JA, Chen CC. Molecular imaging of neuroendocrine tumors. *Semin Oncol*. 2010;37:662–679.
- Hope TA, Allen-Auerbach M, Bodei L, et al. SNMMI procedure standard/EANM practice guideline for SSTR PET: imaging neuroendocrine tumors. *J Nucl Med*. 2023;64:204–210.
- Moses WW. Fundamental limits of spatial resolution in PET. *Nucl Instrum Methods Phys Res A*. 2011;648:S236–S240.
- Hope TA, Pampaloni MH, Nakakura E, et al. Simultaneous (68)Ga-DOTA-TOC PET/MRI with gadoxetate disodium in patients with neuroendocrine tumor. *Abdom Imaging*. 2015;40:1432–1440.
- Oberg K, Couvelard A, Delle Fave G, et al. ENETS consensus guidelines for standard of care in neuroendocrine tumours: biochemical markers. *Neuroendocrinology*. 2017;105:201–211.
- Nobels FR, Kwekkeboom DJ, Coopmans W, et al. Chromogranin A as serum marker for neuroendocrine neoplasia: comparison with neuron-specific enolase and the alpha-subunit of glycoprotein hormones. *J Clin Endocrinol Metab*. 1997;82:2622–2628.

52. Lindholm DP, Öberg K. Biomarkers and molecular imaging in gastroenteropancreatic neuroendocrine tumors. *Horm Metab Res.* 2011;43: 832–837.
53. Mishra PR, Stringer MD. Appendiceal carcinoid tumors: a plea for critical reporting. *Pediatr Surg Int.* 2020;36:539–540.
54. Parikh PP, Perez EA, Neville HL, Hogan AR, Sola JE. Nationwide overview of survival and management of appendiceal tumors in children. *J Pediatr Surg.* 2018;53:1175–1180.
55. Rindi G, de Herder WW, McCluggage WG, et al. Neuroendocrine tumours. In: WHO Classification of Tumours Editorial Board, ed. *Endocrine and Neuroendocrine Tumours*. 5th ed. 10. Lyon: International Agency for Research on Cancer; 2025.
56. Overman M, Kakar S, Carr NJ, et al. *AJCC Cancer Staging System: Neuroendocrine Tumors of the Appendix (Version 9 of the AJCC Cancer Staging System)*. Chicago: American College of Surgeons; 2023.
57. Couvelard A, Perren A, Sipos B. Appendiceal neuroendocrine neoplasms. In: *WHO classification of tumors. Tumors of the Digestive Tract*. 5th ed. Lyon: International Agency for Research on Cancer; 2019:152–155.
58. van Velthuysen MF, Couvelard A, Rindi G, et al. ENETS standardized (synoptic) reporting for neuroendocrine tumour pathology. *J Neuroendocrinol.* 2022;34: e13100.
59. Sparber-Sauer M, Ferrari A, Spunt SL, et al. The significance of margins in pediatric Non-Rhabdomyosarcoma soft tissue sarcomas: consensus on surgical margin definition harmonization from the International Soft Tissue SaRcoma Consortium (INSTRuCT). *Cancer Med.* 2023;12:11719–11730.
60. Ito T, Masui T, Komoto I, et al. JNETS clinical practice guidelines for gastroenteropancreatic neuroendocrine neoplasms: diagnosis, treatment, and follow-up: a synopsis. *J Gastroenterol.* 2021;56:1033–1044.
61. de Mestier L, Lepage C, Baudin E, et al. Digestive Neuroendocrine Neoplasms (NEN): French Intergroup clinical practice guidelines for diagnosis, treatment and follow-up (SNFGE, GTE, RENATEN, TENPATH, FFCD, GERCOR, UNICANCER, SFCD, SFED, SFRO, SFR). *Dig Liver Dis.* 2020 May;52:473–492.
62. Knigge U, Capdevila J, Bartsch DK, et al. ENETS consensus recommendations for the standards of care in neuroendocrine neoplasms: follow-up and documentation. *Neuroendocrinology.* 2017;105:310–319.