

Case Report: Agranulocytosis in a Child Following Metamizole Use – A Diagnostic Challenge

Aljaž Pirnat¹, Tomaž Prelog², Janez Jazbec², Alenka Trampuš Bakija¹

¹Clinical Institute of Special Laboratory Diagnostic, University Children's Hospital, University Medical Centre Ljubljana, Ljubljana, Slovenia, ²Department of Haematology and Oncology, University Children's Hospital, University Medical Centre Ljubljana, Ljubljana, Slovenia

Correspondence: *aljaz.pirnat@kclj.si*; Tel.: + 386 1 5229267

Received: 16 December 2024; **Accepted:** 12 March 2025

Abstract

Objective. This case report describes a young female who developed agranulocytosis with blast cells in peripheral blood following prolonged metamizole use after ankle surgery. **Case Report.** A 17-year-old female patient was admitted to the Department of Infectious Diseases due to high fever and sore throat. Initial diagnostics revealed agranulocytosis, followed by occurrence of blast cells and left shifted neutrophils in the peripheral blood, in subsequent days. Extensive further diagnostics were performed due to suspicion of leukaemia, which was excluded after flow cytometry and cytogenetic analysis of bone marrow aspirate. After all tests were completed, the patient disclosed that she had been using metamizole for four months following ankle surgery. **Conclusion.** In cases of agranulocytosis, involving a prolonged history of metamizole use accompanied by the presence of blast cells and granulocyte precursors in peripheral blood, we would recommend an initial diagnostic approach that includes a complete blood count with differential and flow cytometry of peripheral blood. Bone marrow aspiration may be postponed or deemed unnecessary if peripheral blood flow cytometry shows no aberrant populations and there are no other signs of leukaemia.

Key Words: Metamizole ■ Agranulocytosis ■ Leukaemia ■ Flow Cytometry ■ Blast Cell.

Introduction

Metamizole, or dipyrone, is a non-opioid drug commonly used for its antipyretic, antispasmodic and analgesic properties. It exhibits favourable gastrointestinal, cardiovascular and cerebrovascular tolerability in comparison to non-steroidal anti-inflammatory drugs (NSAIDs) (1, 2). Metamizole is used widely across numerous countries, and in Slovenia it is listed among the most prescribed medications. Furthermore, the prescription of metamizole has been increasing in recent years (1-3). Its administration is also included in the guidelines for postoperative pain management in children provided by the Pain Committee of the European Society for Paediatric Anaesthesiology (4). Despite its widespread use, metamizole has been banned in some countries due to its potential for severe adverse effects, such

as agranulocytosis (1). Agranulocytosis is a severe form of neutropenia, characterized by an absolute neutrophil count less than $0.2 \times 10^9/L$, without any affect on other two cell lineages (5). This life-threatening condition poses a significant risk for severe infections, and commonly manifests within two months of initiating metamizole treatment, with one third to half of the cases occurring within the first week of treatment (1, 6). The mechanism of metamizole-induced agranulocytosis is not yet fully understood. Likely contributing factors include an immune mediated mechanism, and the direct toxic effects of metamizole and its metabolites on granulocyte precursors (5). The estimated incidence of metamizole-induced agranulocytosis varies significantly across studies, with some reports indicating a rate as high as one case per 1,439 prescriptions (6).

This report presents a case of agranulocytosis, most likely induced by metamizole use, with the unusual presence of blast cells in the peripheral blood, as a probable result of bone marrow regeneration and acute infection.

Case Report

A 17-year-old female patient presented at the Outpatient Clinic of the Infectious Diseases Department, complaining of high fever and a sore throat. These symptoms had persisted for the previous week and failed to improve despite phenoxymethylpenicillin therapy. Physical examination revealed pale skin and typical signs of upper respiratory tract infection. She had no history of significant illnesses, but had undergone ankle surgery five months earlier. She denied taking any medication regularly. The laboratory tests showed elevated C-reactive protein (CRP), leukopenia and moderate anaemia (Table 1). She was prescribed amoxicillin and sent home.

Two days later, on follow-up, left-shifted neutrophilic maturation with the presence of promyelocytes, myelocytes, metamyelocytes and blast cells, was reported in a peripheral blood smear (Figure 1).

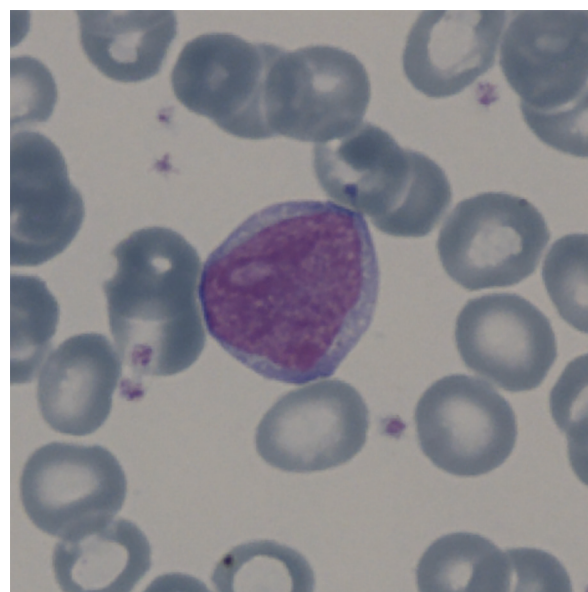


Figure 1. Blast cell in peripheral blood smear.

Table 1. Laboratory Results

Laboratory test [unit]	Outpatient clinic visit	Follow-up visit*	Discharge†	Follow-up visit‡	Reference range
Leukocytes (10 ⁹ /l)	0.8	1.6	12.6	5.5	4.2 – 10.8
Erythrocytes (10 ¹² /l)	4.05	3.85	4.33	4.32	3.90 – 5.15
Haemoglobin (g/l)	97	95	108	1.7	120 – 154
Thrombocytes (10 ⁹ /l)	502	585	612	396	150 – 410
Blast cells (%)	NA§	5	0	0	-
Promyelocyte (%)	NA	2	10	0	-
Myelocyte (%)	NA	6	20	0	-
Metamyelocyte (%)	NA	2	12	0	-
Band neutrophil (%)	NA	4	4	0	-
Segmented neutrophil (%)	NA	10	22	55	36 – 77
Eosinophils (%)	NA	0	0	0	0.5 – 5.5
Basophils (%)	NA	0	0	0	0.00 – 1.75
Lymphocytes (%)	NA	61	26	40	20 – 44
Monocytes (%)	NA	9	5	5	1.5 – 9.0
Plasma cells (%)	NA	1	1	0	-
Band neutrophil (10 ⁹ /l)	NA	0,1	0,5	0	-
Segmented neutrophil (10 ⁹ /l)	NA	0.2	2.8	3.0	1.2 – 7.9
CRP (mg/l)	226	NA	NA	NA	< 8

*Two days after outpatient clinic visit; †Four days after hospitalization; ‡Two months after discharge; §Not assessed.

Due to the suspicion of leukaemia, she was admitted and underwent detailed diagnostic evaluation. A bone marrow aspiration was performed. Morphological examination showed hypercellular bone marrow with decreased erythropoiesis, decreased megakaryopoiesis and increased granulopoiesis. The myelopoiesis-to-erythropoiesis ratio was 11:1 (normal ratio 3:1). The blast cell count was within the reference range (<5%), and Auer rods were absent. One third of all the mononuclear cells were hypergranular promyelocytes, however maturation of the myelocytes beyond the promyelocyte stage was present. Flow cytometry revealed less than 1% of progenitor (CD34+) cells, with no aberrant lymphoid or myeloid populations detected in the bone marrow. Karyotyping and molecular genetics were negative for rearrangements typical for lymphoid and myeloid proliferation, such as BCR::ABL1 ((t(9;22)) and PML::RARA (t(15;17)).

After the bone marrow aspiration test, the patient revealed a history of regular metamizole use, three times daily for the first two months following her ankle surgery. Her complete and differential blood count (CBC DIFF) prior to ankle surgery was reviewed, showing no abnormalities. Following two months of regular metamizole use, she continued with occasional use for following two months. The metamizole treatment was stopped one month before the admission to our hospital. After consideration of additional anamnestic data and previous negative testing, she was diagnosed with agranulocytosis and increased bone marrow production, which could potentially be attributed to prolonged metamizole use and recent infection. At discharge, her condition was stable with a slightly elevated blood leukocyte count, and the mild anaemia persisted with an evident left shift, although no blast cells were detected. At the two-month follow-up appointment, complete resolution was observed, and her laboratory tests were unremarkable. No additional work up or follow-up was necessary.

Discussion

The patient was prescribed metamizole for postoperative pain after her ankle surgery. However, the

patient did not have regular blood checks during her metamizole use, despite the fact that this is recommended when it is administered for extended periods (7). She did not inform her primary care physician nor the physician at the outpatient clinic about her prior metamizole use. As previously emphasized by Hoffmann et al., patients and health-care workers must be aware of the risks associated with metamizole use. It is essential to seek medical attention promptly when a patient is using metamizole and symptoms of infections occur. The patient should be evaluated and treated by specialists experienced in managing febrile neutropenia. Furthermore, if a patient is still taking metamizole, it must be discontinued immediately (2, 5). The lack of awareness in this case endangered the patient's safety, and contributed to delayed diagnosis of agranulocytosis. Since drug-induced agranulocytosis may manifest after a prolonged interval from the last dose of metamizole, it is crucial to obtain detailed anamnestic data and provide preventable action (2). If it is clinically assessed that the patient can be discharged to home care, they must be specifically advised upon discharge to seek immediate medical attention if any signs of new infection appear (5).

The detection of blast cells in the peripheral blood during a follow-up visit was a particularly critical finding, suggesting a possible malignant disease such as acute leukaemia (5). In our experience, almost all children with the presence of blasts in their peripheral blood, are diagnosed with acute lymphoblastic leukaemia or have preleukemia. However, it is important to note that blast cells can also be present in newborns with low birth weight, in individuals with Down syndrome, and in severe cases of sepsis. More important than the proportion of blasts in the peripheral blood is their interpretation in accordance with the clinical presentation. However, any presence of blasts should be evaluated by a haematologist (5, 8). When interpreting blast cells in a peripheral blood smear, the concomitant presence of other cells is important to consider in the differential diagnosis. If blast cells are accompanied by granulocyte precursors, this primarily suggests

regenerative proliferation (9). This case scenario was seen in our patient, as an evident left shift was present in the peripheral blood smear. A useful parameter for differentiating agranulocytosis from leukaemia and other haematological disorders is also haemoglobin concentration. In agranulocytosis, anaemia is generally absent or, when present, only mild. In contrast, other haematological disorders accompanied by neutropenia typically exhibit more pronounced anaemia (5). In our case, moderate anaemia was observed. Consequently, since abnormalities in multiple blood cell lineages increase the suspicion of leukaemia, bone marrow aspiration was performed to exclude the diagnosis. On the basis of the findings of the bone marrow examination, the diagnosis aligned more closely with recovering bone marrow, a condition that might be related to the patient's prolonged metamizole use and concurrent infection.

Conclusion

While the use of metamizole has been on the rise, an inadequate understanding remains among both patients and physicians regarding its potential severe adverse effects, such as agranulocytosis. Given the potentially fatal outcomes of agranulocytosis, it is crucial for patients who develop clinical signs of infection during or after metamizole administration to seek immediate medical assistance from specialists experienced in managing febrile neutropenia. Healthcare professionals should promptly initiate suitable diagnostics and treatment. Additionally, discontinuation of metamizole is essential to prevent further complications. However, accurately diagnosing this condition can sometimes be particularly challenging. As evidenced by our case, the presence of blast cells, which are not typically seen in drug induced agranulocytosis, can mimic the manifestations of leukaemia. In the case of a history of metamizole treatment, we would recommend a more rational initial approach that involves CBC DIFF and flow cytometry of peripheral blood. If the flow cytometry does not reveal any aberrant lymphoid or myeloid populations, an invasive bone marrow

analysis may be postponed or considered unnecessary. Subsequent patient management should include careful monitoring, with additional diagnostic interventions undertaken only if there are indications of disease progression, particularly if any signs suggestive of evolving leukaemia occur.

What Is Already Known on This Topic:

Metamizole is a widely used non-opioid analgesic and antipyretic. Despite its widespread use and inclusion in guidelines for postoperative pain management in children, it has been banned in some countries due to the risk of severe adverse effects, most notably agranulocytosis. Agranulocytosis is a potentially life-threatening condition due to a significant risk for infections and is known to occur within two months of initiating metamizole therapy. Although the incidence of metamizole-induced agranulocytosis varies, its potential severity underscores the need for careful monitoring of patients on prolonged treatment.

What This Study Adds:

This study emphasizes the diagnostic challenges of metamizole-induced agranulocytosis, particularly when atypical findings, such as peripheral blast cells, mimic leukaemia. It highlights the importance of thorough patient history-taking, regular blood monitoring during prolonged metamizole use, and awareness among healthcare providers of delayed manifestations of agranulocytosis. The study proposes a rational diagnostic approach involving CBC DIFF and flow cytometry to minimize invasive procedures, while ensuring timely and accurate diagnosis, thereby improving patient safety and management.

Authors' Contributions: Conception and design: AP, TP, JJ and ATB; Acquisition, analysis and interpretation of data: AP, TP, JJ and ATB; Drafting the article: AP; Revising it critically for important intellectual content: AP, TP, JJ and ATB; Approved final version of the manuscript: AP, TP, JJ and ATB.

Conflict of Interest: The authors declare that they have no conflict of interest.

References

1. Blaser LS, Tramonti A, Egger P, Haschke M, Krähenbühl S, Rätz Bravo AE. Hematological safety of metamizole: retrospective analysis of WHO and Swiss spontaneous safety reports. *Eur J Clin Pharmacol.* 2015;71(2):209-17. doi: 10.1007/s00228-014-1781-z. Epub 2014 Nov 18.
2. Hoffmann F, Bantel C, Jobski K. Agranulocytosis attributed to metamizole: An analysis of spontaneous reports in EudraVigilance 1985-2017. *Basic Clin Pharmacol Toxicol.* 2020;126(2):116-25. doi: 10.1111/bcpt.13310. Epub 2019 Oct 7.
3. Kostnapfel T, Albrecht T, editors. Poraba ambulantno predpisanih zdravil v Sloveniji v letu 2021. [Consumption of outpatient prescribed medications in Slovenia in 2021] [monograph on the Internet]. [cited 2023 Jul 5]. Available

- from: https://nijz.si/wp-content/uploads/2022/07/ambulantna_zdravila_2022_objava_a_19.05.22.pdf.
4. Vittinghoff M, Lönnqvist PA, Mossetti V, Heschl S, Simic D, Colovic V, et al. Postoperative pain management in children: Guidance from the pain committee of the European Society for Paediatric Anaesthesiology (ESPA Pain Management Ladder Initiative). *Paediatr Anaesth*. 2018;28(6):493-506. doi: 10.1111/pan.13373. Epub 2018 Apr 10.
 5. Zver S. Bolezni krvi in krvotvornih organov. [Diseases of the blood and hematopoietic organs.] In: *Interna medicina* [Internal medicine]. 5th ed. Ljubljana: Medicinska fakulteta, Slovensko zdravniško društvo, Buča; 2018. p. 1099-248.
 6. Ibáñez L, Vidal X, Ballarín E, Laporte JR. Agranulocytosis associated with dipyrrone (metamizol). *Eur J Clin Pharmacol*. 2005;60(11):821-9. doi: 10.1007/s00228-004-0836-y. Epub 2004 Dec 3.
 7. s-026893.pdf [database on the Internet]. [cited 2023 Jul 30]. Available from: [http://www.cbz.si/cbz/bazazdr2.nsf/o/E3B7488F25FCB9CFC125874C00839845/\\$File/s-026893.pdf](http://www.cbz.si/cbz/bazazdr2.nsf/o/E3B7488F25FCB9CFC125874C00839845/$File/s-026893.pdf).
 8. Bhatnagar N, Nizery L, Tunstall O, Vyas P, Roberts I. Transient Abnormal Myelopoiesis and AML in Down Syndrome: an Update. *Curr Hematol Malig Rep*. 2016;11(5):333-41. doi: 10.1007/s11899-016-0338-x.
 9. Rose G, Heidi Reinhard H, Kahwash SB. Is this a blast? An illustrated practical review on peripheral blood smear examination in the paediatric patient. *Malays J Pathol*. 2020 Apr;42(1):37-49. PMID: 32342929.