



## Case report

# Bilateral Acrylic Hip Mold Arthroplasty in a Child With a Revision 60 years After Implantation: Clinical Case and Chemical Analysis of Endoprosthetic Material

Samo Roškar, MD <sup>a, b, 1, \*</sup>, Ingrid Milošev, PhD <sup>a, c, 1</sup>, René Mihalič, MD, PhD <sup>a, b</sup>,  
Ema Žagar, PhD <sup>d</sup>, Rihard Trebše, MD, PhD <sup>a, b</sup>

<sup>a</sup> Valdoltra Orthopaedic Hospital, Ankaran, Slovenia

<sup>b</sup> Faculty of Medicine, University of Ljubljana, Ljubljana, Slovenia

<sup>c</sup> Jožef Stefan Institute, Ljubljana, Slovenia

<sup>d</sup> National Institute of Chemistry, Department of Polymer Chemistry and Technology, Ljubljana, Slovenia

## ARTICLE INFO

## Article history:

Received 31 January 2024

Received in revised form

1 April 2024

Accepted 7 April 2024

Available online 21 May 2024

## ABSTRACT

A 68-year-old man was referred due to bilateral hip pain and gradual deterioration of walking. He had mold arthroplasties on both hips at the age of 7 years and has been functioning well for more than 5 decades. However, the original data on operative report and the prostheses were missing. The radiological examination revealed bilateral broken prosthetic material. Thus, stage bilateral revision total hip arthroplasty was performed. A detailed chemical analysis of retrieved mold arthroplasty implants proved that the acrylic material was noted to be the same composition with the difference in appearance likely being related to different thermal treatments originally applied to the implants. As presented in our clinical case, even obsolete implants may have good survivorship. According to the case presented, total hip arthroplasty could be considered an effective option with the desired functional outcome when conservative and joint-preserving measures are exhausted.

© 2024 The Authors. Published by Elsevier Inc. on behalf of The American Association of Hip and Knee Surgeons. This is an open access article under the CC BY-NC-ND license (<http://creativecommons.org/licenses/by-nc-nd/4.0/>).

## Introduction

Hip arthroplasty in skeletally immature children remains controversial due to questionable implant survival [1–3] and the technically demanding surgical procedure. In the past, in children with secondary end-stage hip failure, hip arthrodesis was the most common treatment option [4]. Total hip arthroplasty (THA) is a suitable and effective treatment for those patients after failed joint preserving surgeries or conservative treatment [4,5]. Smith-Petersen performed the first attempts at hip arthroplasty in 1923 and introduced the concept of "mold" arthroplasty by fitting a glass cup between damaged acetabular and femoral head cartilages to stimulate the growth of synovial/cartilage-like layer on damaged joint surfaces [6]. In the 1950s, the

Judet brothers introduced the concept of an acrylic hip hemiarthroplasty covering the damaged femoral head [7]. The most common problem of Smith-Petersen and Judet implants was the prosthesis material failure [7]. Despite implant improvements [6–8], both concepts never reached the desired results and were replaced by contemporary cemented hip arthroplasty introduced by Charnley in the 1960s [1,9]. The most important concerns regarding THA in children include technical difficulties associated with poor bone stock, severe bony deformities, leg length differences, issues regarding preservation of the growth plate and small bone size with a narrow femoral canal [10]. There are no historical reports of pediatric hip arthroplasty and very few for those younger than 10 years. This article reports a rare clinical case of pediatric bilateral acrylic non-Judet hemiarthroplasty implanted 60 years ago.

## Case history

A 68-year-old male patient was referred to our hospital in September 2019 due to bilateral hip pain and inability to walk. He reported that he was treated at our institution at the age of 7 years

\* Corresponding author. Valdoltra Orthopaedic Hospital, Jadranska cesta 31, SI-6280 Ankaran, Slovenia; Faculty of Medicine, University of Ljubljana, Vrazov trg 2, Ljubljana, Slovenia SI-1000. Tel.: +38656696100.

E-mail address: [samo.roskar@ob-valdoltra.si](mailto:samo.roskar@ob-valdoltra.si)

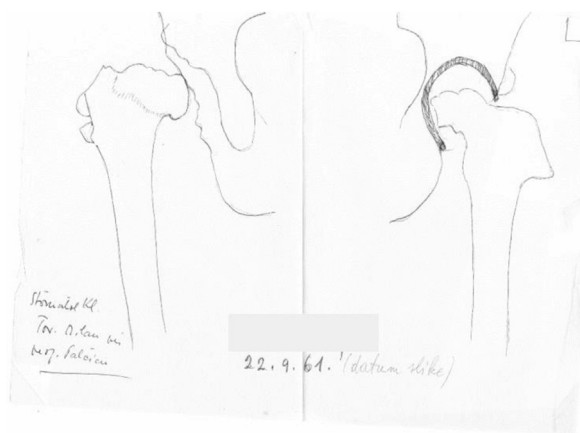
<sup>1</sup> Authors share co-first authorship

for bilateral congenital hip dislocation. In 1961, bilateral glass-like mold arthroplasty with hip repositioning was performed (Fig. 1). We have no records about the implant manufacturer, but it does not look like a Judet implant used in the same period [11].

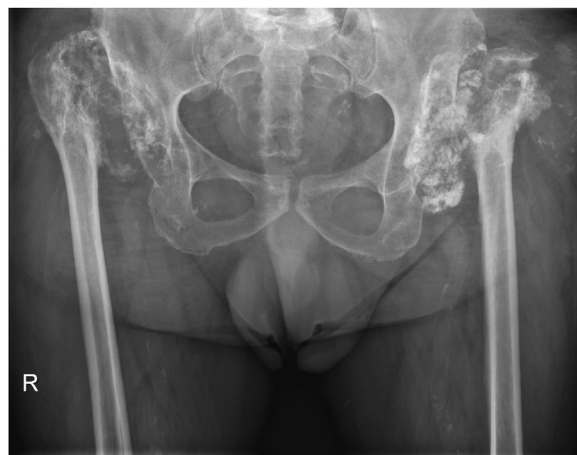A detailed examination of his medical history revealed that he was affected by bilateral hip dislocation treated at the age of 2 years. In March 1956, he was treated with skeletal traction following repositioning and casting, followed by several unsuccessful closed hip repositioning attempts. In April 1961, mold arthroplasty was performed on the left hip, and the right side followed in October 1961. At the time of surgery, he weighed 25 kg. The greater trochanter osteotomy was performed during the approach, the teres ligament was dissected, and the femoral head was dislocated. With chisels, the acetabulum was deepened, and the incorrectly shaped femoral head was marginally resected and shaped to fit the diameter of the mold. Mold arthroplasty is a hemiarthroplasty technique where a hollow hemisphere fits over the femoral head, that is, no acetabular component is implanted. After the surgery, he was immobilized in hip spica cast and skin traction was applied for 3 weeks. In August 1962, he walked without support with the hip flexion at 85°, abduction at 25°, internal rotation at 20°, external rotation at 30°, and retroflexion at 15°.

For several decades after the procedure, he walked shorter distances without pain, even played football, but he was never an avid walker. In the last few years before revision, he experienced progressive pain in both hip joints and could not walk independently, even for short distances. In the weeks before the referral, his average bilateral hip pain was 8/10 according to the visual analog scale, and his ability to walk was less than 100 meters with crutches. The physical examination revealed scars above both hips without any sign of inflammation. Both hips were lax under the axial tension, with good passive movements but considerably restricted active movements.

The revisions were performed in our hospital, first on the right and second on the left. For detailed planning of the surgery, computed tomography scan was performed, and it revealed bilateral dysplastic acetabula with proximally displaced femur, with severe destruction of the articular surfaces and a massive amount of heterotopic ossification in the surrounding tissues. The preoperative X-ray image (Fig. 2) showed that on the right side, joint space, the foreign material was fragmented, while on the left side, there was still a partially preserved dome structure with a diameter of 42 mm.



**Figure 1.** Preoperative planning data from 1961.

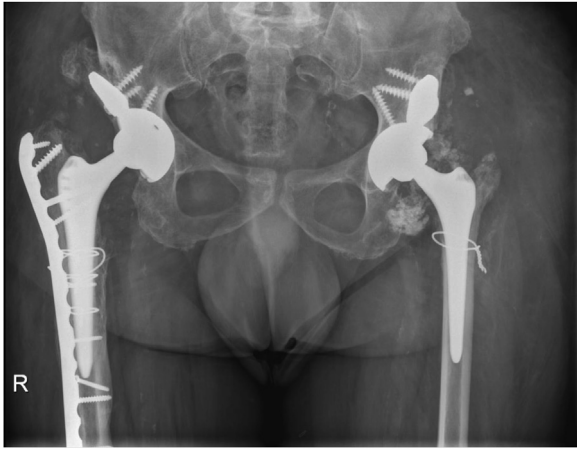


**Figure 2.** An X-ray image of bilateral mold arthroplasties recorded in May 2020 before the revision operation.

The first THA procedure was performed in May 2020 on the right hip (Fig. S1) with the direct lateral approach [12]. After debridement of the hip, including the removal of most broken glass-like fragments of the implant, a Paprosky type 2C acetabular bone defect was identified, and the reconstruction of the acetabulum was performed with the porous revision tantalum cup with lateral acetabular edge supported with a porous tantalum augment (TMARS, Zimmer Biomet, Warsaw, IN), the TMARS shell was size 48 mm and the neutral Longevity liner size 48 mm was cemented into the shell. The Alloclassic stem (Zimmer Biomet, Warsaw, IN) was inserted on the femoral side and 28-mm head was used. Microbiological and histopathological analysis samples were obtained during surgery and were negative regarding infection. After the surgery, there was a functional leg length difference of 7 cm, for which he required special orthopaedic shoes. Postoperative in-hospital physiotherapy that included learning to walk with crutches with limited weight-bearing (up to 40 kg) on the right side was initially uneventful.

In the middle of June 2020, he was urgently admitted to our hospital for a dislocation (Fig. S2a), which was closely reduced. A few days later (end of June 2020), he suffered another dislocation with a subsidence of the femoral component treated with an exchange of the femoral component (Fig. S2b). At the end of July 2020, he was again urgently readmitted for a periprosthetic fracture Vancouver type B1-C (Fig. S2c) when he slipped on the toilet at home and could no longer bear the weight on his right leg, and osteosynthesis was performed (Fig. S2d). At the follow-up in September 2021, he was walking with crutches and scored 66 points on the Harris hip score. His most significant problem at that point was the pain on the left, untreated side, upon standing still for a shorter period of time. Another complaint reported by him was an increased leg length discrepancy since the last surgeries, which was noted to be approximately 9 cm.

In January 2022, the surgery on the left hip was performed using the same approach and implants as described previously, with an uneventful postoperative period. At the last follow-up in April 2022, 3 months after the surgery on the left side and 9 months after the last procedure on the right side, he had no pain in both hips (Fig. 3). He walked with crutches for longer and without them for shorter distances. At the 2-year follow-up in February 2024, he reported no pain associated to both hip regions, he walked without crutches for shorter distances while required crutches for longer walk. At the last follow-up, he scored 79 points on the Harris hip score.



**Figure 3.** X-ray image after definitive revision THA treatments of both hips at follow-up in April 2022.

A written informed consent was provided by the patient for this paper to be published.

As the explanted material differed from the Judet hemiarthroplasty used for adults in the 1950s, we were interested in the material used for the implants. The explanted mold arthroplasty implants are shown in Figure 4. The revised right implant was a fractured cup with a glass-like appearance and sound (Fig. 4a). The revised left implant differed somewhat from the right one (Fig. 4b). It appeared like a dome, but the top surface was worn, leaving a large hole. It was also transparent but more plastic-like and not glass-like compared to the implant on the right side. We had no information on the manufacturer of the prosthetic material and contacted all the retired senior orthopaedic surgeons in the country; however, nobody remembered anything about the case or the praxis to pediatric implant prostheses in the early sixties.

### Material analysis

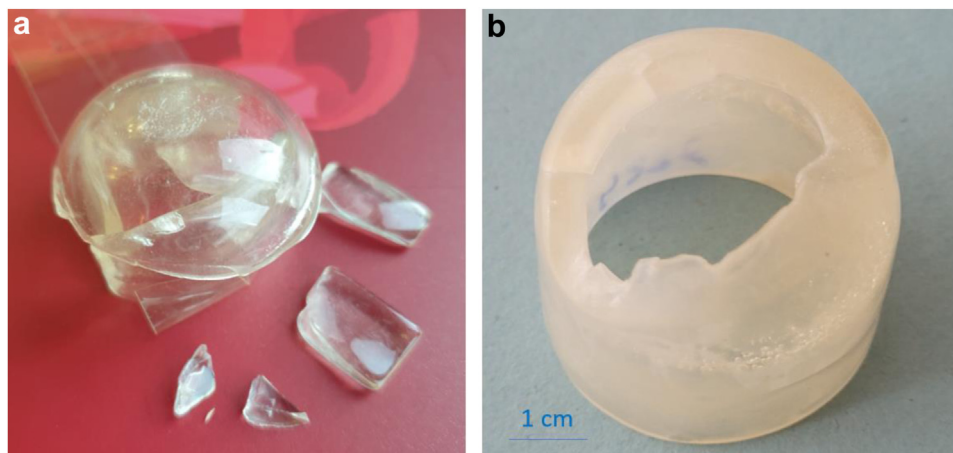
The explants were characterized by different analytical techniques to reveal their chemical composition. The methodology is described in the Supplemental material.

The implant in Figure 4a was analyzed by scanning electron microscopy with energy-dispersive X-ray spectroscopy (Because of its size the implant in Figure 4b could not be placed inside the

microscope without being cut in pieces. The analysis was therefore carried out only for implant in Figure 4a.). The prominent general appearance of the samples is matrix intertwined with fractures and longitudinal marks, presumably related to the wear during decades of use (Fig. 5a and b). The images in Figure 5c and d detail the wear of material where individual scratches and numerous pits are observed. Energy-dispersive X-ray spectroscopy analysis identified only carbon and oxygen (Fig. S3), indicating that the material is organic, that is, polymeric. Since the sample was coated with carbon, it is impossible to distinguish the signal originating from the sample itself. However, if the material were glass, it would contain other elements such as silicon and calcium, which was not the case.


Fourier-transform infrared spectroscopy (FTIR) was explored to resolve the material's chemical composition. FTIR spectra were similar for both implants (Fig. 6). The spectra indicated the acrylic type of material, presumably poly(methyl methacrylate) (PMMA), also known as acrylic glass. FTIR spectrum of PMMA is characterized by the bands between 3500 and 2850  $\text{cm}^{-1}$  due to C–H stretching asymmetric vibrations, an intense band at 1722  $\text{cm}^{-1}$  due to C=O ester carbonyl group, and multiple bands in the region between 1463 and 1377  $\text{cm}^{-1}$  related to C–H ( $\text{CH}_2$ ) and C–H ( $\text{CH}_3$ ) bending vibrations. The band at 1190  $\text{cm}^{-1}$  can be ascribed to C–O stretching vibrations. Bands at smaller wavenumbers below 1000  $\text{cm}^{-1}$  are also associated with CH–CH and bending-out vibrations. The presented spectrum is aligned with the literature data [13].

Based on scanning electron microscopy/ energy-dispersive X-ray spectroscopy and FTIR analyses, it was confirmed that the implants were made of polymeric acrylic material. However, how these materials differ was still unclear since only one had a glassy-like appearance (Fig. 4a). To find a reason for the different appearances of the 2 PMMA materials, they were further characterized by several methods: differential scanning calorimetry, nuclear magnetic resonance (NMR), size exclusion chromatography multi-angle light scattering, and high-performance liquid chromatography. The  $^1\text{H}$  NMR spectra of both samples were comparable and indicative of PMMA (Fig. 7), similar to the FTIR spectra. They showed a comparable content of isotactic, atactic, and syndiotactic triad sequences, indicating a comparable molecular microstructure of both PMMA samples. This is consistent with their comparable glass transition temperatures ( $T_g$ ), as shown by the DSC results ( $T_g$ : 121.8°C and 123.4°C for the right and left implant, respectively; Fig. S4). Furthermore, the  $^1\text{H}$  NMR spectra showed no additional signals indicating the presence of additives, which was also confirmed by high-performance liquid chromatography coupled to a universal evaporative light scattering detector (Fig. S5). The



**Figure 4.** The explanted mold arthroplasties with glass-like appearance: (a) right hip operated in May 2020 and (b) left hip operated in January 2022.





**Figure 5.** Scanning electron images (SEM) of the interior of the concave parts of the mold arthroplasty in Figure 4a show (a, b) longitudinal marks), (c) scratches and (d) pits.

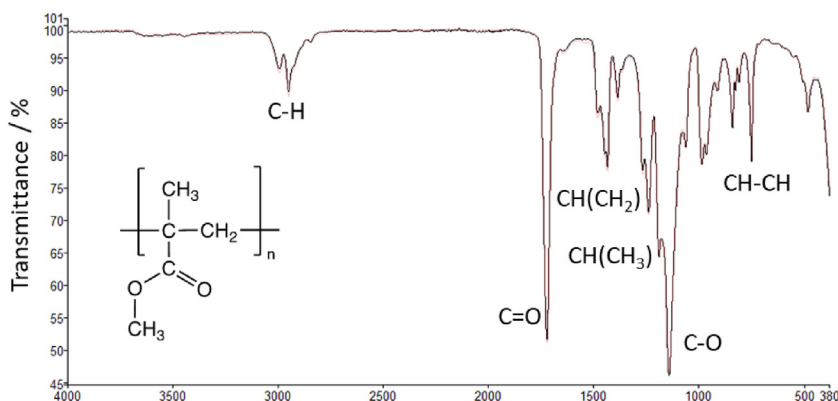
PMMA material of the 2 hips differs only in the molar mass characteristics, as the PMMA of the right hip has higher molar mass averages and slightly broader molar mass distribution (described with the dispersity  $\bar{D}$ ) than the PMMA material of the left hip (Fig. 8).

## Discussion

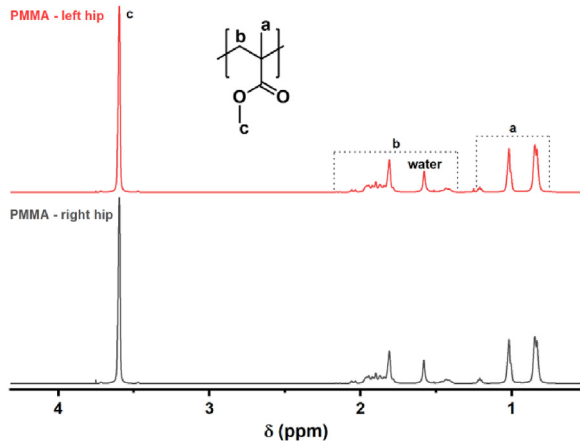
Despite the abundance of evidence regarding THA in adults, the data on pediatric THA is still scarce [1]. Mostly, there are case series of children having THAs during adolescence [2,14], but there is no evidence about using early designs of hip implants in children. The first attempts to solve problems of damaged hips in the past were related to improving joint congruences with smooth and solid materials such as glass or acrylate [6,8]. The main drawbacks of those materials were the components' fragility and lack of component bone on/ingrowth, significantly reducing implants' survival [7,8]. Although several reports about early material

breakage exist, many implants survived for decades after primary implantation [14,15]. It was generally shown that the results of THAs were inferior at a very young age. Only a few reports of hip arthroplasty in children are primarily associated with particular circumstances, including rheumatoid diseases, neurologic conditions, and similar conditions. Different studies on THAs in patients younger than 21 report survival rates between 83% at 3 years of follow-up and 89.5% at 10 years of follow-up [14,16-20]. Literature data are summarized in Table 1. With contemporary implant design, however, a large Mayo series demonstrated excellent results and survivorship [16]. There are no historical reports of pediatric hip arthroplasty and very few for those younger than 10 years.

As in most historical implants, material failure was probably the main reason for hip failure in this patient. We do not know when the material broke, but as there was a period a few years before the revision when the patient noticed a sharp increase in pain and functionality loss, we speculate it was then that the implants



**Figure 6.** Fourier-transform infrared spectra (FTIR) of the interior of the concave parts of the mold arthroplasties in Figure 4a. The chemical structure of poly(methyl methacrylate) (PMMA) is given in inset.



**Figure 7.** Proton nuclear magnetic resonance ( $^1\text{H}$  NMR) spectra of the concave parts of the mold arthroplasties.

shattered. The macroscopic appearance of the implant (Fig. 4a) resembled a glass, while a detailed material analysis of the explanted materials confirmed that it was acrylic-based but not the Judet type [11]. However, the implants differed in visual appearance—one was glassy and the other matt. Our analyses revealed no significant difference in composition and glassy temperature. The glassy-like implant shows higher molar mass averages, as proven by size exclusion chromatography multiangle light scattering.  $^1\text{H}$  NMR and high-performance liquid chromatography chromatograms confirmed that PMMA implants have a comparable microstructure and no other additives.

PMMA is a synthetic polymer of methyl methacrylate monomers (inset in Fig. 6). It was discovered in the 1930s and is widely used as a substitute for glass (due to its adequate properties, that is, lightweight, high impact strength, and shatter resistance [13]. PMMA is an amorphous thermoplastic material because the adjacent methyl group ( $-\text{CH}_3$ ) in the polymer structure prevents it from packing closely in ordered crystalline domains [21]. It is clear and colorless, with very good thermal stability, a glass transition temperature between  $100^\circ\text{C}$  to  $130^\circ\text{C}$  and a  $1.2\text{ g/cm}^3$  density. PMMA is thus an organic glass at room temperature; that is, it is below its glass transition temperature. Commercial products based on PMMA

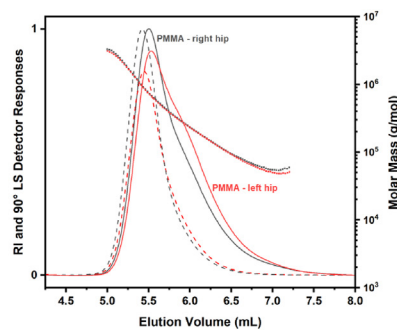
**Table 1**

Literature data on total hip arthroplasty (THA) in young patients younger than 21 years.

Reference	Cohort	Results
Pallante et al. [16]	91 primary THAs in patients <21 y old (average age of 17 y) with bearing surfaces of 58% ceramic-on-ceramic, 31% metal-on-highly cross-linked polyethylene, and 11% ceramic-on-highly cross-linked polyethylene	At an average follow-up of 8 y, the average HHS was 92, and the survivorship for any complication was 91.2%, 91.2%, and 89.5% at 2, 5, and 10 y, respectively. No difference in linear wear among different bearing surfaces was observed.
Khalenberg et al. [17]	129 primary THAs in patients <21 y old (mean age: 17 y)	Survivorship for revision was 79.1% at a mean follow-up of 13.2 years, the mean UCLA activity score was 5.9, the mean Forgotten Joint Score 57.9 and the mean Hip Disability in Osteoarthritis Outcome Score for Joint replacement was 84.6 at final follow-up.
Buddhdev et al. [18]	60 primary THA in patients <19 y old (mean age: 16.7 y)	Survivorship for revision was 97% at a mean follow-up of 9.3 years, the mean Oxford hip score was 44, and mean VAS was 1.5 at final follow-up.
Van de Velde et al. [14]	24 primary THA in patients <16 (mean age: 14.6 y)	At a mean follow-up of 3.8 y; all patients had greatly improved pain and function scores.
Launay et al. [19]	17 primary THAs	At a mean follow-up of 3 y; 83% of patients had a satisfactory function, and the mean HHS was 87.7 at the final follow-up.
Chopat et al. [20]	12 primary THAs (mean age: 16 y)	At mean follow-up 6 y (minimum 2, maximum 9 y), mean HHS was 81 and Oxford hip score was 39.5. No revision surgery required to the last follow-up.

HHS, Harris hip score; VAS, visual analog scale.

are usually mixed formulations of homopolymers and various additives or fillers, optimized relative to the particular application of interest. Furthermore, different manufacturing procedures, such as injection and compression molding or cell-casting, and various post-treatments are available. The detailed chemical analyses of the 2 acrylic polymer materials did not show structural differences



Sample	$M_w$ kg/mol	$M_n$ kg/mol	$\bar{D} = M_w/M_n$
Right hip	602	269	2.24
Left hip	506	243	2.08

**Figure 8.** Size-exclusion chromatograms of the concave parts of the mold arthroplasties. The solid and dotted curves represent the refractive index detector and  $90^\circ$  light-scattering detector responses, respectively, while the lines represent the molar mass as a function of elution volume. The table below shows the weight- ( $M_w$ ) and number- ( $M_n$ ) of the average molar masses and dispersity of the PMMA materials from which the implants are made.

between them. Therefore, the difference in their appearance is ascribed to different processing conditions and/or thermal histories of the samples. Nonetheless, both hips functioned well for 6 decades in the human body and proved that polymer-based materials could achieve long-lasting performance.

The presented report of prosthetic hips implanted during childhood and lasting into old age is unique in several aspects. It represents a world record of child prosthetic hip survivorship, although it is not a universal hip implant survivorship record [22]. It demonstrated that alternative materials had been considered during the history of artificial hips. And finally, it shows that pediatric hip arthroplasty has been present for years. Based on the Guinness Book of Records, the longest-lasting Vitallium hip replacement was still in place and functioning as of 2022, but Norman Sharp, the patient, was 23 years of age when he received his artificial hips [23], while our patient was only 7 years of age. To our knowledge, the implant on the left side is the world record in the survival of any implanted pediatric hip prosthesis in history, as, on the right side, the revision was performed 59 years after implantation, and on the left side, 61 years after implantation.

## Summary

Despite good survival, even with obsolete implants, there are still many concerns regarding indications for pediatric THA due to technical difficulties, severe bone deformities, poor bone stock, and a higher rate of complications than adult THA. We believe there are solid indications for THA but only if other conservative or joint-preserving surgeries are exhausted. Normalizing a severe hip failure in childhood with a THA can result in an uneventful teenage period, finding a perfect basis for adulthood despite pending problems with an eventual THA failure. Considering the optimal implant material, the quest for the best material for artificial joints was ever-present and is still unanswered [24].

## Acknowledgments

The authors thank Barbara Kapun, BSc, of the Jožef Stefan Institute for SEM/EDS and FTIR analyses. Center for Electron Microscopy and Microstructure and Center of Excellence NAMASTE are acknowledged for using SEM/EDS and FTIR instruments, respectively.

## Funding

The Valdoltra Orthopaedic Hospital funded the study. The authors IM and EŽ acknowledge the partial funding by the Slovenian Research and Innovation Agency (grants No. P2-0393 and P2-0145).

## Conflicts of interest

The authors declare there are no conflicts of interest.

For full disclosure statements refer to <https://doi.org/10.1016/j.artd.2024.101401>.

## Informed patient consent

The author(s) confirm that written informed consent has been obtained from the involved patient(s) or if appropriate from the parent, guardian, power of attorney of the involved patient(s); and,

they have given approval for this information to be published in this case report (series).

## Ethics approval and consent to participate

All procedures performed were following the ethical standards of the institutional research committee and with the 1964 Helsinki Declaration and its later amendments or comparable standards.

## Consent for publication

The patient was informed that data concerning the case would be submitted for publication, and he provided written consent.

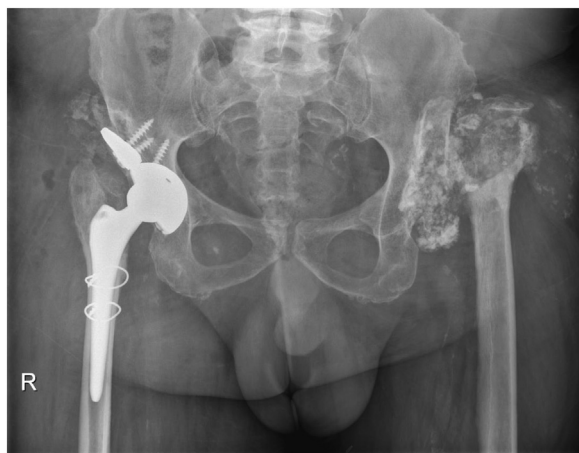## Availability of data and material

All data and materials analyses are available upon reasonable request.

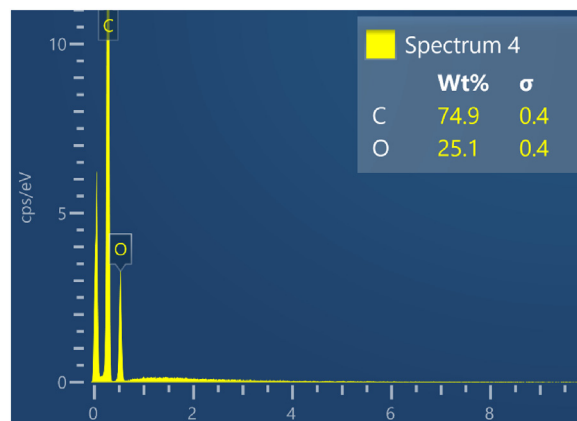
## References

- [1] Halvorsen V, Fenstad AM, Engesaeter LB, Nordsletten L, Overgaard S, Pedersen AB, et al. Outcome of 881 total hip arthroplasties in 747 patients 21 years or younger: data from the Nordic Arthroplasty Register Association (NARA) 1995–2016. *Acta Orthop* 2019;90:331–7.
- [2] Luceri F, Morelli I, Sinicato CM, Della Grazia A, Verdoni F, Maffulli N, et al. Medium-term outcomes of total hip arthroplasty in juvenile patients. *J Orthop Surg Res* 2020;15:476.
- [3] Daurka JS, Malik AK, Robin DA, Witt JD. The results of uncemented total hip replacement in children with juvenile idiopathic arthritis at ten years. *J Bone Joint Surg Br* 2012;94:1618–24.
- [4] Patel NK, Luff T, Whittingham-Jones P, Gooding CR, Hashemi-Nejad A. Total hip arthroplasty in teenagers: an alternative to hip arthrodesis. *Hip Int* 2012;22:621–7.
- [5] Shah KN, Racine J, Jones LC, Aaron RK. Pathophysiology and risk factors for osteonecrosis. *Curr Rev Musculoskelet Med* 2015;8:201–9.
- [6] Smith-Petersen MN. Evolution of mould arthroplasty of the hip joint. *J Bone Joint Surg Br* 1948;30B:59–75.
- [7] Judet J, Judet R. The use of an artificial femoral head for arthroplasty of the hip joint. *J Bone Joint Surg Br* 1950;32-B:166–73.
- [8] Judet R, Judet J. Technique and results with the acrylic femoral head prosthesis. *J Bone Joint Surg Br* 1952;34-B:173–80.
- [9] Charnley J. Arthroplasty of the hip. A new operation. *Lancet* 1961;1:1129–32.
- [10] Polkowski GG, Novais EN, Kim YJ, Millis MB, Schoenecker PL, Clohisy JC. Does previous reconstructive surgery influence functional improvement and deformity correction after periacetabular osteotomy? *Clin Orthop Relat Res* 2012;470:516–24.
- [11] Kovač S, Pišot V, Trebše R, Rotter A. Fifty-one-year survival of a Judet polymethylmethacrylate hip prosthesis. *J Arthroplasty* 2004;19:664–7.
- [12] Hardinge K. The direct lateral approach to the hip. *J Bone Joint Surg Br* 1982;64:17–9.
- [13] Rodić P, Korošec RC, Kapun B, Mertelj A, Milošev I. Acrylate-based hybrid sol-gel coating for corrosion protection of AA7075-T6 in aircraft applications: the effect of copolymerisation time. *Polymers* 2020;12:948.
- [14] Van de Velde SK, Loh B, Donnan L. Total hip arthroplasty in patients 16 years of age or younger. *J Child Orthop* 2017;11:428–33.
- [15] Rushton N, Hart GM, Arden GP. The Judet prosthesis: a long-term follow-up of three cases and a review of the literature. *Injury* 1979;11:49–51.
- [16] Pallante GD, Statz JM, Milbrandt TA, Trousdale RT. Primary total hip arthroplasty in patients 20 years old and younger. *J Bone Joint Surg Am* 2020;102:519–25.
- [17] Kahlenberg CA, Garvey MD, Blevins JL, Sculco TP, Sculco PK, Figgie MP. High satisfaction and activity levels after total hip arthroplasty in patients under age 21. *J Arthroplasty* 2021;36:3485–9.
- [18] Buddhdev PK, Vanhegan IS, Khan T, Hashemi-Nejad A. Early to medium-term outcomes of uncemented ceramic-bearing total hip arthroplasty in teenagers for paediatric hip conditions. *Bone Joint J* 2020;102-B:1491–6.
- [19] Launay F, Jouve JL, Guillaume JM, Viehweger E, Jacquemier M, Bollini G. Arthroplastie totale de hanche sur mesure et sans ciment chez l'enfant et l'adolescent: à propos de 17 cas [Total hip arthroplasty without cement in children and adolescents: 17 cases]. *Rev Chir Orthop Reparatrice Appar Mot* 2002;88:460–6.

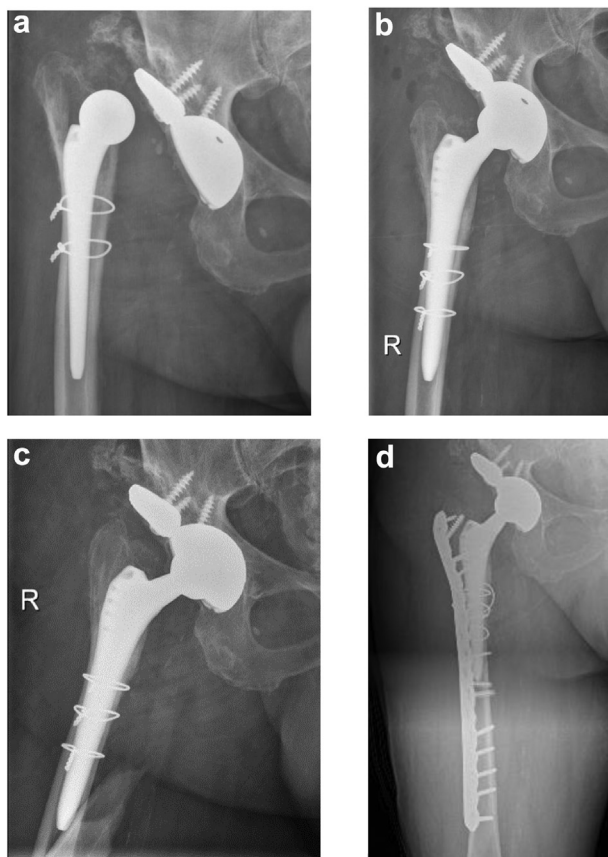
- [20] Chapot A, Zambelli PY, Merckaert SR. Functional and patient-related outcomes of total hip arthroplasty in patients younger than 20 years. *Arthroplast Today* 2023;20:101100. <https://doi.org/10.1016/j.artd.2023.101100>.
- [21] Ali U, Karim KJBA, Buang NA. A review of the properties and applications of poly (methyl methacrylate) (PMMA). *Polyme Rev* 2015;55:678–705. <https://doi.org/10.1080/15583724.2015.1031377>.
- [22] Guinness World Records. Longest lasting hip replacement, London: Guinness World Records. <https://www.guinnessworldrecords.com/world-records/72895-longest-lasting-hip-replacement>; 2022. [Accessed 1 June 2022].
- [23] Guinness World Records. The inspiring story of the man whose pioneering hip replacement has lasted a record-breaking 70 years. <https://www.guinnessworldrecords.com/news/2019/11/the-inspiring-story-of-the-man-whose-pioneering-hip-replacement-has-lasting-a-reco-597819>; 2019. [Accessed 1 June 2022]. London: Guinness World Records.
- [24] Milošev I, Levašić V, Kovač S, Sillat T, Virtanen S, Tiainen V-M, et al. Metals for joint replacements. Elsevier. In: Ravell P, editor. *Joint Replacement Technology*. 3rd ed. Cambridge, United States: Woodhead Publishing Series in Biomaterials; 2021. p. 65–112. <https://doi.org/10.1016/B978-0-12-821082-6.00020-0>.



**Figure S1.** X-ray image after the implantation of THA of the right hip in June 2020.

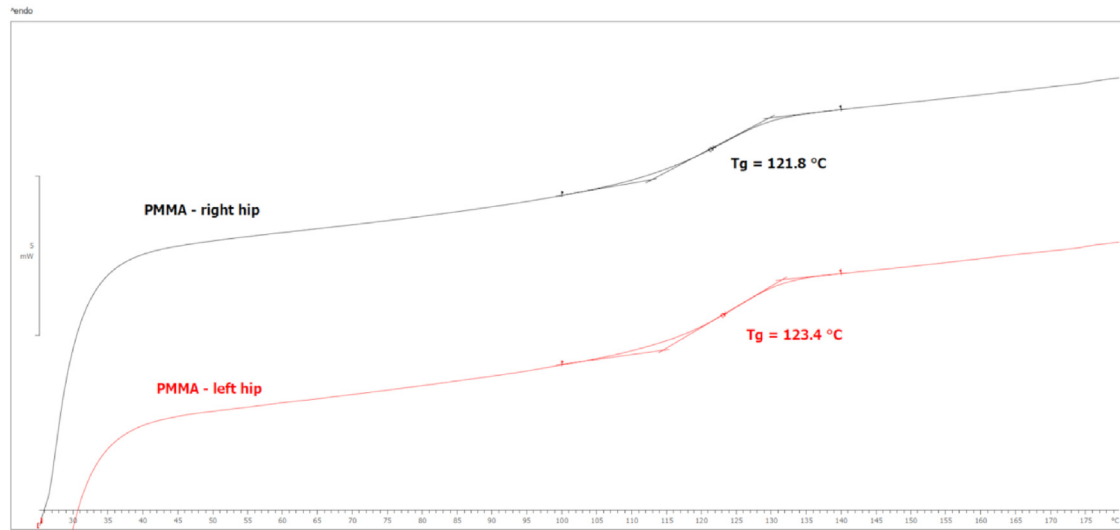


**Figure S3.** The energy-dispersive X-ray spectrum of the interior of the concave part of the cup shown in Figure 4a. The chemical composition in weight % is given in the inset table.

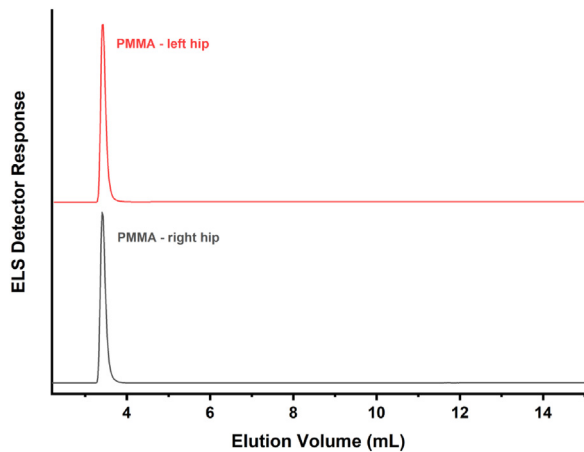


**Figure S2.** X-ray images of (a) luxation of THA of the right hip in June 2020, (b) after the first revision in June 2020, (c) after the second revision in July 2020 and (d) after the treatment of periprosthetic fracture in July 2020.





**Figure S4.** Differential scanning calorimetry (DSC) thermograms of the concave parts of the mould arthroplasties show comparable glass transition temperatures for both PMMA materials from which the implants are made.



**Figure S5.** High-performance liquid chromatograms (HPLC) of the concave parts of the mould arthroplasties show that the material of the 2 implants does not differ in chemical composition.