

research article

Reliability of new radiographic measurement techniques for elbow bony impingement

Uros Meglic^{1,2}, Oskar Zupanc^{1,2}¹ Department of Orthopaedic Surgery, University Medical Centre Ljubljana, Ljubljana, Slovenia² Faculty of Medicine, University of Ljubljana, Ljubljana, Slovenia

Radiol Oncol 2022; 56(1): 32-36.

Received 19 October 2021

Accepted 10 November 2021

Correspondence to: Prof. Oskar Zupanc, M.D., Ph.D, Department of Orthopedic Surgery, University Medical Centre Ljubljana, Slovenia.
E-mail: oskarzupanc@gmail.com

Disclosure: No potential conflicts of interest were disclosed.

This is an open access article under the CC BY-NC-ND license (<http://creativecommons.org/licenses/by-nc-nd/4.0/>).

Background. Identifying the location and scale of radiographic changes in elbow bony impingement (EBI) is critical in formulating an appropriate diagnosis and treatment plan for such patients. The purpose of present study was to evaluate the intra-rater and inter-rater reliability of the new radiographic parameters, Anterior Impingement angle (Ala) and Posterior Impingement angle (Pla), for EBI. In addition, to determine if there was a relationship between radiographic parameters and clinical evaluation.

Patients and methods. Three raters of different levels of training evaluated the radiographs of 60 patients (30 in EBI group and 30 in normal group) twice, at least 2 weeks apart. Intra-rater and inter-rater reliabilities were calculated by Intraclass Correlation Coefficients (ICC) with 95% confidence intervals. Correlation between radiographic parameters and clinical evaluation was calculated by Pearson correlation coefficient.

Results. In both groups, intra-rater and inter-rater reliabilities were substantial. There were no significant differences in reliability between upper-hand expert surgeons and resident for either measurement. Good correlation was observed between impingement arcs and range of motion values.

Conclusions. Both Ala and Pla measurements demonstrated substantial intra-rater and inter-rater reliability for normal radiographs and in EBI patients. Good reliability, for either expert surgeons or residents in training, and good correlation between radiographic measurements and manual testing, appoints this method may be easily and reliably used in every day practice.

Key words: elbow; osteoarthritis; impingement; classification; reliability

Introduction

Bony impingement of the elbow (EBI) is an early radiographic sign of the elbow degenerative disease.¹ Although being rare in general population, with prevalence up to 2%, it can be noticed with increased prevalence, up to 10%, in professional overhead athletes and manual laborers.² As a result of excessive and repetitive motions, bony osteophytes occur in anterior and posterior compartment of the elbow.³ Changing elbow geometry, it causes flexion and extension deficit of the elbow motion.⁴

Although a flexion-extension range of motion (fROM) between 30 degrees and 130 degrees of flexion is enough to achieve 90% of the daily living activities, in professional athletes or manual laborers even a smaller loss of fROM can be devastating, with huge impact on their quality of life.⁵ Thus it has to be recognized early and treated properly.

To date, there is no consensus among orthopedic surgeons as to when in the course of the disease and how much to treat EBI, to provide symptomatic relief for a given patient. One reason for the lack of consensus is an inability to predict success based on preoperative assessment. A paucity of informa-

tion regarding specific radiographic parameters is a significant cause in these cases.

The purpose of present study was, first, to evaluate the intra-rater and inter-rater reliability of the new radiographic parameters for EBI. The second goal was to determine if there was a relationship between radiographic parameters and clinical evaluation.

Patients and methods

Slovenia National Medical Ethics Committee approval (No. 1650513) was obtained for this investigation.

A total 60 subjects were enrolled. Among them 30 subjects with fROM deficit and diagnosed, not yet treated, EBI were recruited as the EBI group. Remaining 30 subjects with other elbow pathologies (epicondylitis, ulnar neuritis etc.), but with a normal fROM and no clinical signs of EBI were recruited as the NORMAL group. A brief clinical history was obtained in order to rule out previous injury or upper extremity abnormality. Focused physical examination was performed with manual fROM testing.

Standard antero-posterior and lateral x-ray views were obtained. Unsatisfactory films were repeated in order to maintain consistency. Digital radiograph images were analyzed using Agfa IMPAX 6 software (Agfa HealthCare, Belgium). Broberg and Morrey (BM) as well as Hasting and Rettig (HR) classifications of elbow osteoarthritis were used to assess elbow joint's degenerative changes.^{6,7} Sigmoid notch coverage (SNC) measurement was performed as described by Goldfarb *et al.*, as a line connecting the center of the circle, fitted to sigmoid notch, to both the tip of the olecranon and coronoid (Figure 1C).⁸ Measurements of the Anterior Impingement angle (AIa) and Posterior Impingement angle (PIa) were obtained on lateral x-ray images as previously described by Meglic and Zupanc.⁹ The angle between the centralized ulnar direction line and the line between the center of rotation (COR) and the tip of the coronoid presents AIa. The angle between the centralized ulnar direction line and the line between the COR and the tip of the olecranon presents PIa (Figure 1A, B).⁹ For reliability evaluation, two upper extremity surgeons (OZ, UM) and one resident after radiological training (NK), independently evaluated each radiograph for radiographic measurements of AIa and PIa. Each evaluator re-measured both parameters after an interval of at least 2 weeks, a

period used in other reliability studies in upper extremity.^{1,10} The examiners were blinded to their previous measurements.

Subjects were excluded from participation if there was evidence of: an upper extremity injury history, a growth or congenital abnormality, moderate or severe grade on BM or HR classification (grade II and III).

Statistical Package for Social Sciences version 21.0 (SPSS Inc, Chicago, IL, USA) was used for all statistical analyses. Student t test was used for group comparisons when normality was accepted, and a Mann-Whitney U test was used if normality was rejected. The Fisher exact test was used for categorical data between groups. Original data from all 3 raters were used to assess reliability of measurements. Inter- and intra-rater reliability were calculated using intraclass correlation coefficients (ICC), ICC 2.1 for inter-rater, ICC 3.1 for intra-rater.¹¹ Pearson correlation coefficient was used to measure correlation between impingement arcs and fROM. Correlation coefficient values less than 0.5 are indicative of poor reliability, values between 0.5 and 0.74 indicate moderate reliability, values between 0.75 and 0.89 indicate good reliability, and values greater than 0.90 indicate excellent reliability.¹¹ All tests were 2-tailed, with $p < 0.05$ considered significant. All ICC values were calculated with 95% confidence interval (95% CI).

Results

All patients included in the study were analyzed (60 patients, 100%). There were 20 males (67%), 10 females (33%) in EBI group and 12 males (40%), 18 females (60%) in NORMAL group ($p = 0.07$). The average age was 44 years (range 21–64 years) in EBI group and 33 years (range 18–60 years) in NORMAL group ($p = 0.02$). Pathology was presented on dominant hand in 22 cases (73%) in EBI group and in 26 cases (87%) in NORMAL group ($p = 0.33$). In EBI group in all cases BM and HR classification was graded stage I and in NORMAL group in all cases, no radiographic signs of osteoarthritis were reported.

Table 1 summarizes manual and radiographic measurements, comparing both groups. In all measurements, the differences between groups were statistically significant.

ICCs for AIa and PIa measurements demonstrated good to excellent intra-rater and inter-rater reliability in both groups. Almost all ICCs were in 0.75–0.89 class, except intra-rater ICC in AIa in

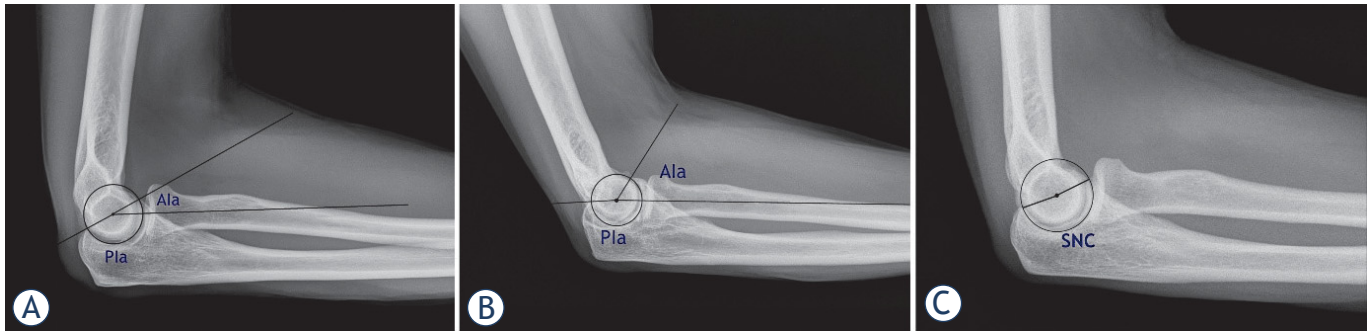


FIGURE 1. Radiographic measurements: (A) Anterior Impingement angle (Ala) and Posterior Impingement angle (Pla) in normal group, (B) Ala and Pla in EBI group, (C) sigmoid notch coverage angle (SNC) in normal group.

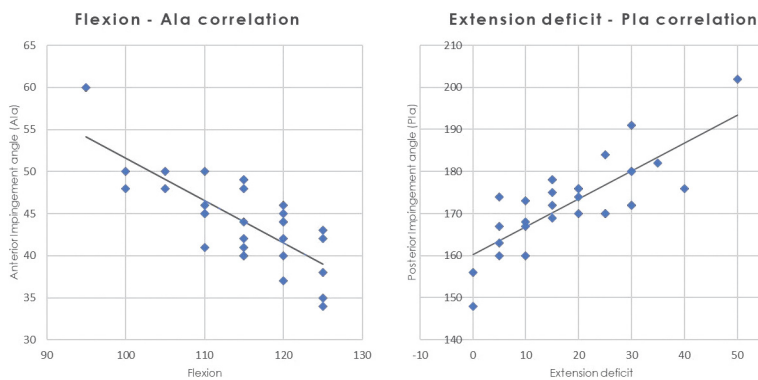


FIGURE 2. Manual flexion-extension range of motion (FROM) and radiographic measurement correlations between (A) flexion and Anterior Impingement angle Ala, (B) extension deficit and Posterior Impingement angle (Pla).

TABLE 1. Manual and radiographic measurements

	EBI group ^a	NORMAL group ^a	P
Flexion (°)	115 ± 8	139 ± 5	< 0.05
Extension deficit (°)	19 ± 12	0 ± 0	< 0.05
fROM (°)	96 ± 14	139 ± 5	< 0.05
SNC (°)	217 ± 10	170 ± 6	< 0.05
Ala (°)	44 ± 5	20 ± 4	< 0.05
Pla (°)	173 ± 10	150 ± 5	< 0.05

^aMean ± SD;

Ala = Anterior Impingement angle; EBI = elbow bony impingement; SNC = sigmoid notch coverage; Pla = Posterior Impingement angle; fROM = flexion-extension range of motion

NORMAL group and inter-rater ICC in AIa between Surgeon 1 and Resident in NORMAL group being in > 0.90 class. AIa measurements ranged from 34° to 60° (average 44°) in EBI group and from 10° to 25° (average 20°) in NORMAL group. Pla measurements ranged from 148° to 202° (average

173°) in EBI group and from 140° to 160° (average 150°) in NORMAL group. Inter-rater reliability and intra-rater reliabilities for all 3 raters are summarized in Table 2.

There were no significant differences in reliability between two upper-hand expert surgeons and one resident for either measurement. Both surgeons and a resident demonstrated a substantial agreement in all measurements. Inter-rater reliabilities between all raters are summarized in Table 3.

Statistically significant correlations were observed between fROM measurements and according Impingement arc. Correlation coefficient showed good negative correlation between flexion and AIa measurements, measured 0.76, (95% CI = 0.86–0.51; $p < 0.05$) (Figure 2A). A good positive correlation between extension deficit and Pla measurements was observed, measured 0.79, (95% CI = 0.59–0.89; $p < 0.05$) (Figure 2B).

Discussion

Treating EBI remains a challenging problem. A factor influencing heavily in determining the appropriate treatment choice is a lack of a reliable and accurate measurement technique. Very little information exists describing pathologic radiographic anatomy of EBI, thus making diagnosis and treatment difficult for both clinical and research purposes.

The results of this study revealed substantial intra-rater and inter-rater reliability of both AIa and Pla measurements on EBI and normal elbow radiographs. For selecting and reporting ICC reliability we used Koo *et al.* guidelines.¹¹ Following Koo's guidelines, we used 3 raters with blinded re-measurements, used ICC 3.1 for intra-rater and ICC 2.1 for inter-rater reliability and reported all

TABLE 2. Inter-rater and intra-rater reliabilities^a

		Inter-rater reliability ^a	Intra-rater reliability for rater 1 ^a	Intra-rater reliability for rater 2 ^a	Intra-rater reliability for rater 3 ^a
EBI group	Ala	0.85 (0.75–0.94)	0.87 (0.75–0.94)	0.87 (0.74–0.94)	0.87 (0.75–0.95)
	Pla	0.84 (0.69–0.92)	0.83 (0.66–0.91)	0.88 (0.76–0.94)	0.85 (0.75–0.93)
NORMAL group	Ala	0.87 (0.76–0.94)	0.90 (0.81–0.95)	0.87 (0.74–0.94)	0.87 (0.75–0.95)
	Pla	0.85 (0.75–0.93)	0.86 (0.73–0.93)	0.86 (0.73–0.93)	0.86 (0.74–0.94)

^aICC value (95% CI);

Ala = Anterior Impingement angle; CI = confidence interval; EBI = elbow bony impingement; ICC = intraclass correlation coefficients; Pla = Posterior Impingement angle

TABLE 3. Inter-rater reliability between two upper-hand expert surgeons and one resident

		Surgeon 1 vs. surgeon 2 ^a	Surgeon 1 vs. resident ^a	Surgeon 2 vs. resident ^a
EBI group	Ala	0.85 (0.71–0.93)	0.85 (0.74–0.94)	0.86 (0.78–0.95)
	Pla	0.84 (0.69–0.92)	0.89 (0.79–0.95)	0.87 (0.74–0.94)
NORMAL group	Ala	0.87 (0.74–0.94)	0.90 (0.80–0.95)	0.88 (0.77–0.94)
	Pla	0.85 (0.71–0.93)	0.89 (0.77–0.94)	0.87 (0.760–0.94)

^aICC value (95% CI);

Ala = Anterior Impingement angle; CI = confidence interval; EBI = elbow bony impingement; ICC = intraclass correlation coefficients; Pla = Posterior Impingement angle

results with 95% CI. Therefore, we can conclude that our results, with good to excellent reliability, are valid.

Furthermore, our results suggest that training level does not affect the reliability of both measurement techniques, which is largely substantial for both surgeons and trainees before applying them to practice.

Lastly, correlation of manual testing and radiographic measurements is necessary before routine use of these methods. Our results showed a good correlation of AIa with flexion measurement, and Pla with extension deficit. Thus, these radiographic measurements are valid for diagnosing and clinical evaluation of EBI.

In up to date literature, previous studies focus mainly on normal radiographic anatomy, ossification patterns, gender differences and fracture outcomes.^{8,12-14} Most of those described parameters are not usable in EBI evaluations, as it is an early sign of elbow degeneration. For elbow osteoarthritis HR classification is usually used.⁷ Yet, no specific radiographic parameter in HR is described that can be used for EBI classification, only staging of the disease. Without a specific method of measurement, that is objectively verifiable, measurements

and conclusions can vary markedly from evaluator to evaluator.

To our knowledge, ours is the first study examining reliability and clinical correlation of Impingement angles for EBI evaluation. Only parameter in the literature being slightly associated with EBI is the SNC described by Goldfarb *et al.*⁸ Although, they report SNC being only a moderately reliable parameter, we decided to use it in our measurements for group comparison. SNC was significantly greater in EBI group compared to NORMAL group. We believe this reflects the common characteristics seen in degenerative elbow disease, such as osteophyte formation. However, SNC does not specify the origin and extent of EBI, as impingement can be mainly in anterior or in posterior compartment of the elbow joint. For that reason, we decided not to use it in the reliability measurements.

Our study has a few limitations. It demonstrated substantial reliability that may be partially due to the smaller number of raters, all from a single institution. Also, the strong reliability between upper-hand expert surgeons and a resident may be because the resident-rater was under the tutelage of the surgeon-rater. However, our study was

designed with Koo's ICC guidelines and can be treated as valid.

Another limitation is that radiographic assessment was performed only on plain radiographs. In clinical practice a computer tomography (CT) scan is often used for evaluating EBI in cases to be surgically treated.¹⁵ A 3D CT study by Lim *et al.* showed osteophytes predominating in the humeroulnar compartment, specifically in the anterior coronoid area (in 95%) and posteromedial compartment (in 86%).¹⁶ A CT scan helps visualizing osteophytes and assess their relationship to normal joint surfaces. Nonetheless, given the fact that most clinical assessments are based on plain radiographs and obtaining a CT scan in most cases means a transfer of patient to another department, we feel our techniques are reasonable in a way to be easy accessible.

Lastly, as a study limitation, elbow motion includes pronation and supination, which was not assessed. Clinically, patients with EBI have limited flexion-extension ROM and pain in terminal extension and forced flexion. Characteristically, these patients (grade I on HR) do not have pronation-supination limitations.⁷ Pronation-supination limitations are associated with radio-capitellar joint degeneration and subluxation, estimated grade II or III on HR, which was an exclusion parameter in our study.⁷

In summary, the findings in our study support the use of AIa and PIa measurements on plain radiographs of elbow joint in patients with suspected EBI. This may prove helpful in future studies by allowing comparison of function, treatment choice and outcomes according to radiographic measurements.

Conclusions

Identifying the location and scale of radiographic changes in EBI is critical in formulating an appropriate diagnosis and treatment plan for such patients. Both AIa and PIa measurement demonstrated substantial intra-rater and inter-rater reliability. In this study both measurements were reliably applied by expert surgeons and resident, with good correlation to manual testing of the elbow function.

Acknowledgments

The authors thank Nerma Kulasic for the support and contribution in this study.

References

1. Amini MH, Sykes JB, Olson ST, Smith RA, Mauck BM, Azar FM, et al. Reliability testing of two classification systems for osteoarthritis and post-traumatic arthritis of the elbow. *J Shoulder Elbow Surg* 2015; **24**: 353-7. doi: 10.1016/j.jse.2014.10.015
2. Adla DN, Stanley D. Primary elbow osteoarthritis: an updated review. *Shoulder Elbow* 2011; **3**: 41-8. doi: 10.1111/j.1758-5740.2010.00089.x
3. Adams JE, Wolff LH 3rd, Merten SM, Steinmann SP. Osteoarthritis of the elbow: results of arthroscopic osteophyte resection and capsulectomy. *J Shoulder Elbow Surg* 2008; **17**: 126-31. doi: 10.1016/j.jse.2007.04.005
4. Wilson V. Upper extremity injuries in the throwing athlete. *Mo Med* 2011; **108**: 170-2. PMID: 21736074
5. Blonna D, Bellato E, Marini E, Scelsi M, Castoldi F. Arthroscopic treatment of stiff elbow. *ISRN Surg* 2011; **2011**: 378135. doi: 10.5402/2011/378135
6. Broberg MA, Morrey BF. Results of delayed excision of the radial head after fracture. *J Bone Joint Surg Am* 1986; **68**: 669-74. PMID: 3722222
7. Rettig LA, Hastings H 2nd, Feinberg JR. Primary osteoarthritis of the elbow: lack of radiographic evidence for morphologic predisposition, results of operative debridement at intermediate follow-up, and basis for a new radiographic classification system. *J Shoulder Elbow Surg* 2008; **17**: 97-105. doi: 10.1016/j.jse.2007.03.014
8. Goldfarb CA, Patterson JM, Sutter M, Krauss M, Steffen JA, Galatz L. Elbow radiographic anatomy: measurement techniques and normative data. *J Shoulder Elbow Surg* 2012; **21**: 1236-46. doi: 10.1016/j.jse.2011.10.026
9. Meglic U, Zupanc O. Significance of radiographic parameters in the diagnosis and treatment of a bony impingement of the elbow. *Mater Technol* 2019; **53**: 747-50. doi: 10.17222/mit.2018.232
10. Blonna D, Zarkadas PC, Fitzsimmons JS, O'Driscoll SW. Validation of a photography-based goniometry method for measuring joint range of motion. *J Shoulder Elbow Surg* 2012; **21**: 29-35. doi: 10.1016/j.jse.2011.06.018
11. Koo TK, Li MY. A Guideline of selecting and reporting intraclass correlation coefficients for reliability research. *J Chiropr Med* 2016; **15**: 155-63. doi: 10.1016/j.jcm.2016.02.012
12. Cheng JC, Wing-Man K, Shen WY, Yurianto H, Xia G, Lau JT, et al. A new look at the sequential development of elbow-ossification centers in children. *J Pediatr Orthop* 1998; **18**: 161-7. PMID: 9531396
13. Keenan WN, Clegg J. Variation of Baumann's angle with age, sex, and side: implications for its use in radiological monitoring of supracondylar fracture of the humerus in children. *J Pediatr Orthop* 1996; **16**: 97-8. doi: 10.1097/01241398-199601000-00019
14. Zarezaadeh A, Mamelson K, Thomas WC, Schoch BS, Wright TW, King JJ. Outcomes of distal humerus fractures: what are we measuring? *Orthop Traumatol Surg Res* 2018; **104**: 1253-1258. doi: 10.1016/j.otsr.2018.08.017
15. Ko CC, Tai MH, Lin CH, Tzeng WS, Chen JH, Shu G, et al. Posteromedial olecranon impingement of the pitching elbow: additional findings provided by CT. *Eur J Radiol* 2016; **85**: 211-217. doi: 10.1016/j.ejrad.2015.11.022
16. Lim YW, van Riet RP, Mittal R, Bain GI. Pattern of osteophyte distribution in primary osteoarthritis of the elbow. *J Shoulder Elbow Surg* 2008; **17**: 963-6. doi: 10.1016/j.jse.2008.03.012