

research article

Infarct-core CT perfusion parameters in predicting post-thrombolysis hemorrhagic transformation of acute ischemic stroke

Crt Langel¹, Katarina Surlan Popovic²

¹ Novo Mesto General Hospital, Slovenia

² Institute of Radiology, University Medical Centre Ljubljana, Slovenia

Radiol Oncol 2019; 53(1): 25-30.

Received 26 August 2018

Accepted 11 November 2018

Correspondence to: Assoc. Prof. Šurlan Popović Katarina, M.D., Ph.D., Institute of Radiology, University Medical Centre Ljubljana, Zaloška cesta 7, SI-1000 Ljubljana, Slovenia. Phone: +386 1 522 85 30; E-mail: katarina.surlan@gmail.com

Disclosure: No potential conflicts of interest were disclosed.

Background. Intravenous thrombolysis (IVT) is the method of choice in reperfusion treatment of patients with signs and symptoms of acute ischemic stroke (AIS) lasting less than 4.5 hours. Hemorrhagic transformation (HT) of acute ischemic stroke is a serious complication of IVT and occurs in 4.5–68.0% of clinical cases. The aim of our study was to determine the infarct core CT perfusion parameter (CTPP) most predictive of HT.

Patients and methods. Seventy-five patients with AIS who had undergone CT perfusion (CTP) imaging and were treated with IVT were enrolled in this retrospective study. Patients with and without HT after IVT were defined as cases and controls, respectively. Controls were found by matching for time from AIS symptom onset to IVT \pm 0.5 h. The following CTPPs were measured: cerebral blood flow (CBF), cerebral blood volume (CBV), mean transit time (MTT), relative CBF (rCBF) and relative CBV (rCBV). Receiver operating characteristic analysis curves of significant CTPPs determined cut-off values that best predict HT.

Results. There was a significant difference between cases and controls for CBF ($p = 0.004$), CBV ($p = 0.009$), rCBF ($p < 0.001$) and rCBV ($p = 0.001$). Receiver operating characteristic analysis revealed that rCBF $< 4.5\%$ of the contralateral mean (area under the curve = 0.736) allowed prediction of HT with a sensitivity of 71.0% and specificity of 52.5%.

Conclusions. CTP imaging has a considerable role in HT prediction, assisting in selection of patients that are likely to benefit from IVT. rCBF proved to have the highest HT predictive value.

Key words: acute ischemic stroke; computed tomography perfusion; infarct core; hemorrhagic transformation

Introduction

Ischemic stroke is defined as an episode of neurological dysfunction caused by focal cerebral, spinal or retinal infarction accompanied by overt symptoms.¹ About 90% of all strokes are ischemic, while roughly 10% are hemorrhagic (including intracerebral and subarachnoid hemorrhage).²

Patients presenting signs and symptoms of acute ischemic stroke (AIS) undergo a series of CT imaging procedures, including non-contrast CT to exclude pre-treatment intracranial hemorrhage, CT angiography (CTA) to determine the precise location of vessel occlusion, CT perfusion (CTP) to

differentiate between potentially salvageable and irreversibly damaged brain tissue, and post-treatment non-contrast CT to exclude thrombolysis-related hemorrhage.³⁻⁶

The standard AIS treatment method within 4.5 hours of symptom onset is intravenous thrombolysis (IVT) with tissue plasminogen activator (tPA) injection.^{7, 8} Patients with IVT-therapy contraindications or ineffectiveness may be eligible for endovascular mechanical thrombectomy (MT).^{8, 9}

Hemorrhagic transformation (HT) is a conversion of ischemic brain tissue into a hemorrhagic lesion due to blood-brain barrier disruption. It may occur spontaneously in ischemic brain tissue but

may also be triggered by reperfusion.^{10, 11} HT occurs in 4.5 - 68.0% of AIS clinical cases and has a higher incidence in patients treated with IVT than in patients without such treatment.¹²⁻¹⁴ While mild to moderate HT may not seriously impact the clinical outcome, severe HT is a significant predictor of neurological deterioration and higher mortality.^{14, 15}

CTP is an imaging technique that measures brain tissue blood perfusion by analyzing time-attenuation curves of contrast agent in input artery and parenchyma, generating maps of CT perfusion parameters (CTPPs). CTPPs are cerebral blood volume (CBV), mean transit time (MTT) and cerebral blood flow (CBF). CBV is defined as the total volume of flowing blood in a given volume of brain. MTT is defined as the average transit time of blood through a given brain region. CBF is defined as the volume of flowing blood moving through a given volume of brain in a specific amount of time. The three CTPPs are associated by the equation: $CBF = CBV / MTT$.¹⁶

Absolute CTPPs are values of a certain brain region while relative CTPPs are values of a certain brain region divided by values of the contralateral brain region. In the context of AIS, relative CTPPs are values measured in the pathological hemisphere expressed as a percentage of the values measured in the contralateral normal hemisphere.¹⁷

Previous studies have shown that CTPPs of the whole infarct area (penumbra and infarct core as a single region) could be used to predict HT, finding relative CBV ($rCBV$) ≤ 1.09 and $T_{max} > 14$ s, respectively, to be the most predictive of HT, with relative CBF ($rCBF$) $< 30\%$ also being of considerable utility in predicting HT.^{18, 19} One study found neither CBF nor CBV to be significantly different between cases and controls, while not examining relative CTPPs.²⁰ Another study examined infarct-core CTPPs, finding $CBV \leq 0.5$ mL/100 g to be predictive of symptomatic intra-cerebral hemorrhage, while also not investigating relative CTPPs.²¹ One study initially proposed separate analysis of infarct-core CTPPs but eventually dismissed the idea due to insufficient sample size.¹⁸

The rationale for separate analysis of the infarct core subregion is that it may provide a different insight into HT prediction than a whole-infarct approach, due to the elimination of the "average-out" effect.²¹ The reasoning behind the use of relative rather than absolute CTPPs is to account for potential interpatient variability, while also avoiding the inter-vendor variability of postprocessing software.^{18, 22} Our study thus aimed to investigate

CTPPs of the infarct core in predicting HT, with an emphasis on relative CTPPs

Patients and methods

Patients

This single-centre retrospective study enrolled 75 patients (47 males, 37 females, mean age \pm SD 72.63 ± 11.7 years) who had been admitted to neurological emergency, with AIS symptoms lasting less than 4.5 hours. Patients underwent admission non-contrast CT, CTA and CTP imaging, and were treated with IVT according to guidelines, in the period from January 2012 – April 2015. The study was performed in accordance with the Declaration of Helsinki and was approved by the National Medical Ethics Committee (Trial registration number: 0120-453/2017-3).

Methods

CT, CTA and CTP imaging were performed with a Siemens Sensation Open 40 (Siemens Medical Systems, Erlangen, Germany). CTP was performed using 40 mL of iodinated contrast medium at a flow rate of 6 mL/s, followed by 40 mL of saline flush at the same rate, injected into the cubital vein. Four s after initiation of the injection, a continuous (cine) scan was initiated using the following parameters: 80 kVp, 209 mAs, 4×5 mm sections, 1-second per rotation for a duration of 40 s.

The images were loaded onto a workstation (Syngo MultiModality Workplace; Siemens Healthcare, Erlangen, Germany). CTPPs - cerebral blood flow (CBF), cerebral blood volume (CBV) and mean transit time (MTT) - were automatically calculated from CTP data using commercial software (Neuro PCT; Siemens Healthcare, Erlangen, Germany). A single circular region of interest (ROI) measuring 15–20 mm in diameter was placed in the region of the infarct core. Mirror ROI was automatically placed by the software in the contralateral (i.e., asymptomatic) hemisphere. Region-specific CTPPs of both ROIs were measured. Relative CTPPs were calculated by dividing the CTPP values of infarct core ROI by asymptomatic hemisphere ROI.

The development of HT was documented by follow-up non-contrast CT 24 h after initial imaging. Patients who developed HT were assigned to the cases group ($n=35$), while patients that did not develop HT were assigned to the controls group ($n=40$), matching the cases based on time from AIS symptom onset to IVT ± 0.5 h. The matching was

carried out by first obtaining the data regarding the time period from AIS symptom onset to the start of the IVT procedure for each patient, then selecting those patients from the pool of controls group candidates that most closely matched each cases group patient's time period, ± 0.5 h being the cut-off point beyond which a controls group candidate would not be considered for matching. Adhering to these conditions 40 cases were assigned controls, however due to technical inadequacies of some of the imaging studies (e.g. patient movement) cases group was later reduced to 35 patients.

Statistical analysis

All numerical data were reported as means \pm standard deviation. The normality of data distribution was evaluated by the Shapiro-Wilk test. The Mann-Whitney U-test was used to determine the existence of a statistically significant difference in CTPPs between cases and controls. A p value < 0.05 was regarded as statistically significant. The area of the receiver operating characteristic (ROC) curve under the curve (AUC) determined the ability of CTPPs to differentiate between the occurrence and non-occurrence of HT. ROC curve analysis identified optimal cut-off values of CTPPs that predict the onset of HT with the highest sensitivity and specificity. IBM SPSS Statistics (version 20.0, SPSS Inc., Chicago, IL, USA) was used to perform statistical analyses.

Results

Seventy-five patients with AIS who had undergone CTP imaging and had been treated with IVT were included in the study. Significant differences in mean values between cases and controls were observed ($p = < 0.000-0.009$) for CBF, CBV, rCBF and rCBV.

The area under the curve (AUC) of the receiver operating characteristic (ROC) of rCBF (0.736) showed a satisfactory ability to differentiate between the occurrence and non-occurrence of HT, while AUCs of CBF, CBV and rCBV showed comparatively inferior differentiation abilities (0.704–0.676).

Discussion

HT is a potentially grave complication of IVT, occurring in 4.5–68.0% of clinical AIS cases. Severe

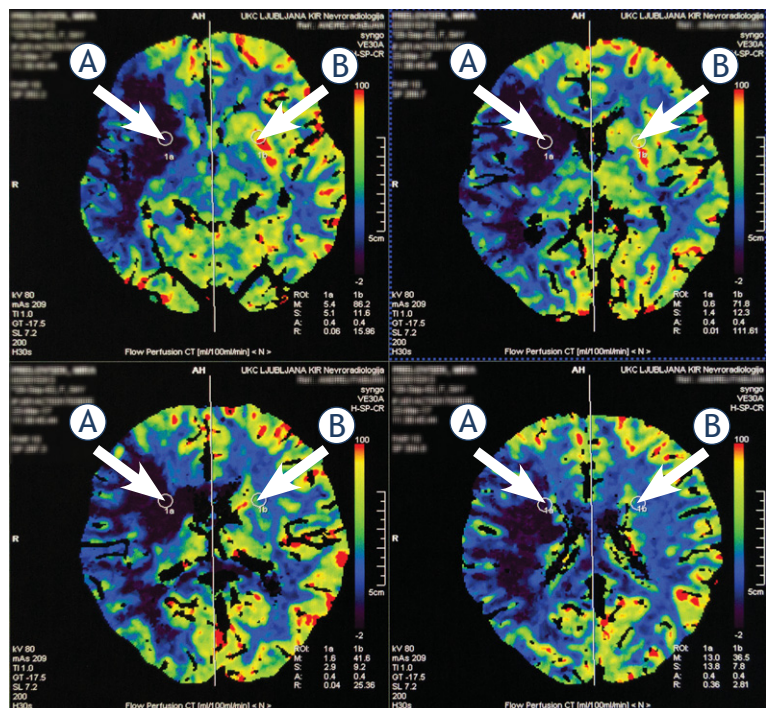


FIGURE 1. CT perfusion (CTP) in a 64-year old patient with acute ischemic stroke (AIS) in the territory supplied by the right middle cerebral artery (MCA). Four radiological slices correspond to different anatomical levels of image acquisition. (A) Hand-drawn region of interest (ROI) in the region of infarct core. (B) Automatically generated ROI of the asymptomatic contralateral hemisphere.

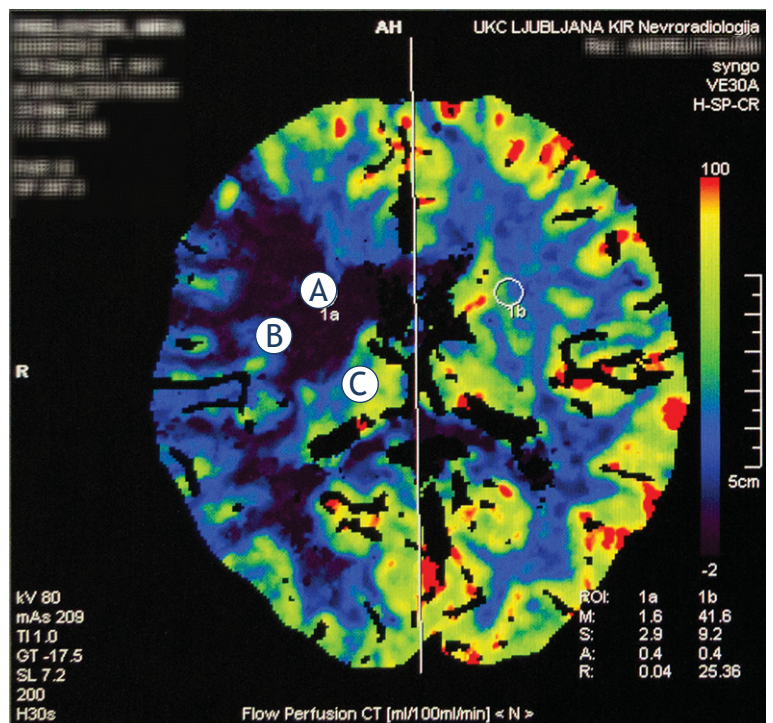


FIGURE 2. CT perfusion (CTP) in a 64-year old patient with acute ischemic stroke (AIS) in the territory supplied by the right middle cerebral artery (MCA). (A) Infarct core. (B) Penumbra. (C) Intact brain parenchyma.

TABLE 1. Characteristics of study cohort

Parameter	Cases	Controls	p value
CBF (mean (SD)) [mL/100 g/min]	0.38 (0.47)	0.98 (1.37)	0.004
CBV (mean (SD)) [mL/100 g]	1.45 (1.7)	3.06 (2.99)	0.009
MTT (mean (SD)) [s]	4.27 (4.00)	4.22 (3.26)	0.718
rCBF (mean (SD))	0.03 (0.05)	0.10 (0.12)	< 0.000
rCBV (mean (SD))	0.07 (0.09)	0.10 (0.12)	0.001
rMTT (mean (SD))	2.47 (2.05)	2.36 (1.65)	0.948

CBF = cerebral blood flow; CBV = cerebral blood volume; MTT = mean transit time; rCBF = relative cerebral blood flow; rCBV = relative cerebral blood volume; rMTT = relative mean transit time

TABLE 2. Region of interest (ROI) curve analysis results

	AUC	cut-off value	sensitivity	specificity
CBF [mL/100 g/min]	0.691	0.35	62.0%	35.0%
CBV [mL/100g]	0.676	1.65	68.6%	40.0%
rCBF	0.736	4.5%	71.0%	52.5%
rCBV	0.704	8.5%	71.4%	42.5%

CBF = cerebral blood flow; CBV = cerebral blood volume; rCBF = relative cerebral blood flow; rCBV = relative cerebral blood volume

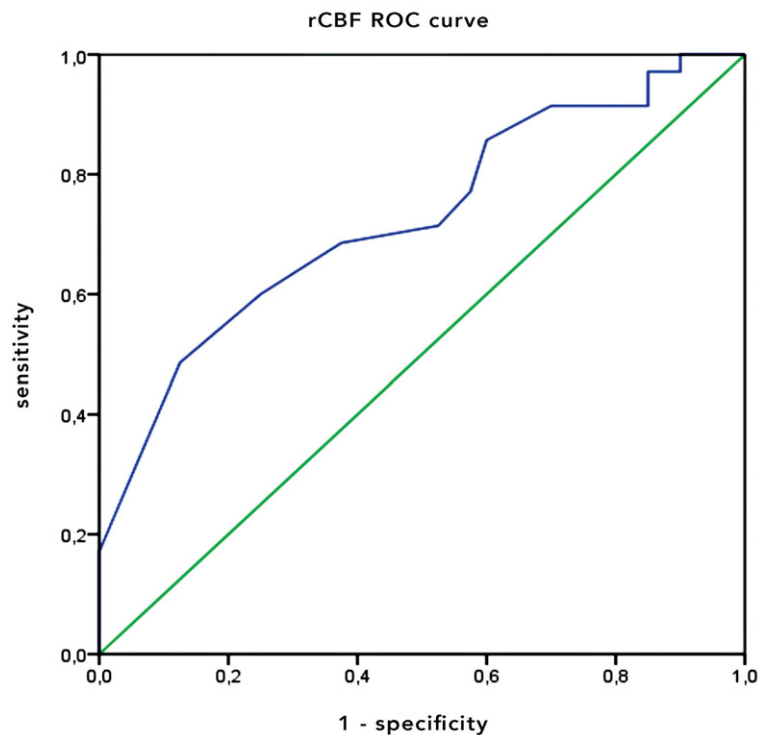


FIGURE 3. Region of interest (ROI) curve of relative cerebral blood flow (rCBF) in patients with and without hemorrhagic transformation (HT). rCBF represents the CBF of the infarct core region normalized to the intact contralateral side. The cut-off point marks the threshold at which relative cerebral blood volume (rCBV) can predict HT with optimal sensitivity and specificity. Diagonal segments are produced by ties.

HT is a significant predictor of neurological deterioration and higher mortality.¹⁵ Various HT prediction methods have been investigated, including CT, CTP, SPECT and diffusion- and perfusion-weighted MR imaging.²¹⁻²⁶ According to previously published data, CTPPs of the whole infarct area effectively predict HT. Jain *et al.* and Yassi *et al.* found relative CTPPs – rCBV and rCBF, respectively, – to be the most predictive of HT.^{18,19}

To the best of our knowledge, this study is the first to analyze relative CTPPs of infarct core in predicting HT. On the one hand, the infarct core itself seems not to have been the main focal point of investigations so far, due to various circumstances, including limited sample size, as was the case with Jain *et al.*¹⁸ On the other hand, the sole study that did analyze infarct core, carried out by Lin *et al.*, investigated absolute CTPPs only. The findings of Zussman *et al.* cautioned against using absolute CTPPs due to inter-vendor variability of post-processing software, while Jain *et al.* also warned of possible interpatient variability of absolute CTPPs, encouraging the use of relative CTPPs instead.^{21,22}

The above arguments prompted us to focus on analyzing relative CTPPs of the infarct core, with the full knowledge that there might currently be no point of reference to compare our results directly. We found additional reasoning for an infarct-core approach in the fact that our attempts at free-hand whole-infarct designation with image segmentation to eliminate structures that were irrelevant for CTP (*e.g.*, large vessels and sulci) proved futile in many cases; eliminating a large vessel completely often required such a large Hounsfield units (HU) exclusion interval that it inadvertently also deselected the majority of tissue viable for CTP analysis. Additionally, we found the non-segmentation single-ROI infarct-core approach to be fast and straightforward – a potential advantage when using CTPPs in an emergency clinical setting.

Our study of infarct-core CTPPs demonstrates that rCBF < 4.5% of the contralateral mean best predicts the occurrence of HT (sensitivity 71.0%, specificity 52.5%). Considering studies that opted for whole-infarct measurement of relative CTPPs, it should be noted that our approach offered considerably inferior sensitivity but better specificity than whole-infarct rCBF < 30% (sensitivity 100%, specificity 39.0%) studied by Yassi *et al.*, while whole-infarct rCBV < 1.09 (sensitivity 100%, specificity 58.3%) researched by Jain *et al.* proved to be superior to both infarct-core rCBF and whole-infarct rCBF. Infarct-core rCBV < 8.5% (sensitivity 71.4%, specificity 42.5%) examined by our study

proved to be inferior in HT prediction to the aforementioned CTPPs but might be considered as an additional parameter to rCBF when evaluating the infarct core due to similar sensitivity.

A possible reason for the extremely low infarct-core rCBF examined in our study being less sensitive in prediction of HT than the moderately low whole-infarct rCBF examined by Yassi *et al.* might be that the severe hypo-perfused stroke region contains very low levels of contrast, which in certain cases could be undetectable by CTP.¹⁹ Additionally, our ROI placement protocol limited the maximum diameter of circular ROI to 20 mm, and while smaller ROIs help eliminate the “average-out” effect that is associated with large, whole-infarct freehand ROIs, they may also be more susceptible to the effect of random pixel noise.²¹ Another possible source of the comparatively higher data heterogeneity in our study may be the potential temporal truncation of the contrast bolus in the infarct region.^{27, 28}

Our study has several limitations. It was a retrospective study. The effects of stroke severity and anatomical location were not controlled by matching, nor was the anatomical location of HT. HT was not stratified into subtypes. The time to treatment was controlled by matching; this, however, decreased the final cohort size. ROI placement was performed by a single experienced operator but no estimation of the intra-observer reproducibility of this procedure was made. Our results represent only a single-institution experience.

In conclusion, our analysis indicates that infarct-core CTPPs - low rCBF in particular - can predict HT in patients with AIS. Should this be further verified by larger multi-centre studies, CTP imaging could become the method of choice for identification of patients at low risk of HT, thus helping decide on IVT treatment.

References

- Sacco RL, Kasner SE, Broderick JP, Caplan LR, Connors JJ, Culebras A, et al. An updated definition of stroke for the 21st century: a statement for healthcare professionals from the American Heart Association/American Stroke Association. *Stroke* 2013; **44**: 2064-89. doi: 10.1161/STR.0b013e318296aeca
- Mozaffarian D, Benjamin EJ, Go AS, Arnett DK, Blaha MJ, Cushman M, et al. Heart Disease and Stroke Statistics-2016 Update: A Report From the American Heart Association. *Circulation* 2016; **133**: e38-360. doi: 10.1161/CIR.0000000000000350
- Rathore SS, Hinn AR, Cooper LS, Tyroler HA, Rosamond WD. Characterization of incident stroke signs and symptoms: findings from the atherosclerosis risk in communities study. *Stroke* 2002; **33**: 2718-21. PMID: 12411667
- Shetty SK, Lev MH. CT perfusion in acute stroke. *Neuroimaging Clin N Am* 2005; **15**: 481-501. doi: 10.1016/j.nic.2005.08.004
- Phan TG, Donnan GA, Koga M, Mitchell LA, Molan M, Fitt G, et al. Assessment of suitability of thrombolysis in middle cerebral artery infarction: a proof of concept study of a stereologically-based technique. *Cerebrovasc Dis* 2007; **24**: 321-7. doi: 10.1159/000106977
- Hoeffner EG, Case I, Jain R, Gujar SK, Shah GV, Deveikis JP, et al. Cerebral perfusion CT: technique and clinical applications. *Radiology* 2004; **231**: 632-44. doi: 10.1148/radiol.2313021488
- Demaerschalk BM, Kleindorfer DO, Adeoye OM, Demchuk AM, Fugate JE, Grotta JC, et al. Scientific rationale for the inclusion and exclusion criteria for intravenous alteplase in acute ischemic stroke: a statement for healthcare professionals from the American Heart Association/American Stroke Association. *Stroke* 2016; **47**: 581-641. doi: 10.1161/STR.0000000000000086
- Powers WJ, Rabinstein AA, Ackerson T, Adeoye OM, Bambakidis NC, Becker K, et al. 2018 guidelines for the early management of patients with acute ischemic stroke: a guideline for healthcare professionals from the American Heart Association/American Stroke Association. *Stroke* 2018; **49**: e46-e110. doi: 10.1161/STR.0000000000000158
- Powers WJ, Derdeyn CP, Biller J, Coffey CS, Hoh BL, Jauch EC, et al. 2015 American Heart Association/American Stroke Association focused update of the 2013 guidelines for the early management of patients with acute ischemic stroke regarding endovascular treatment: a guideline for healthcare professionals from the American Heart Association/American Stroke Association. *Stroke* 2015; **46**: 3020-35. doi: 10.1161/STR.0000000000000074
- Wang X, Lo EH. Triggers and mediators of hemorrhagic transformation in cerebral ischemia. *Mol Neurobiol* 2003; **28**: 229-44. doi: 10.1385/MN:28:3:229
- Nour M, Scalzo F, Liebeskind DS. Ischemia-reperfusion injury in stroke. *Interv Neurol* 2013; **1**: 185-99. doi: 10.1159/000353125
- Sussman ES, Connolly ES Jr. Hemorrhagic transformation: a review of the rate of hemorrhage in the major clinical trials of acute ischemic stroke. *Front Neurol* 2013; **4**: 69. doi: 10.3389/fneur.2013.00069
- Larrue V, von Kummer R R, Müller A, Bluhmki E. Risk factors for severe hemorrhagic transformation in ischemic stroke patients treated with recombinant tissue plasminogen activator: a secondary analysis of the European-Australasian Acute Stroke Study (ECASS II). *Stroke* 2001; **32**: 438-41. PMID: 11157179
- Kablam M, Kreisel SH, Sauer T, Binder J, Szabo K, Hennerici MG, et al. Predictors and early outcome of hemorrhagic transformation after acute ischemic stroke. *Cerebrovasc Dis* 2011; **32**: 334-41. doi: 10.1159/000331702
- D'Amelio M, Terruso V, Famoso G, Di Benedetto N, Realmuto S, Valentini F, et al. Early and late mortality of spontaneous hemorrhagic transformation of ischemic stroke. *J Stroke Cerebrovasc Dis* 2014; **23**: 649-54. doi: 10.1016/j.jstrokecerebrovasdis.2013.06.005
- Konstas AA, Goldmakher GV, Lee TY, Lev MH. Theoretic basis and technical implementations of CT perfusion in acute ischemic stroke. Part 1. Theoretic basis. *AJNR Am J Neuroradiol* 2009; **30**: 662-68. doi: 10.3174/ajnr.A1492
- Wintermark M, Flanders AE, Velthuis B, Meuli R, van Leeuwen M, Goldsher D, et al. Perfusion-CT assessment of infarct core and penumbra: receiver operating characteristic curve analysis in 130 patients suspected of acute hemispheric stroke. *Stroke* 2006; **37**: 979-85. doi: 10.1161/01.STR.0000209238.61459.39
- Jain AR, Jain M, Kanthala AR, Damania D, Stead LG, Wang HZ, et al. Association of CT perfusion parameters with hemorrhagic transformation in acute ischemic stroke. *AJNR Am J Neuroradiol* 2013; **34**: 1895-900. doi: 10.3174/ajnr.A3502
- Yassi N, Parsons MW, Christensen S, Sharma G, Bivard A, Donnan GA, et al. Prediction of poststroke hemorrhagic transformation using computed tomography perfusion. *Stroke* 2013; **44**: 3039-43. doi: 10.1161/STROKEAHA.113.002396
- Aviv RI, d'Este CD, Murphy BD, Hopyan JJ, Buck B, Mallia G, et al. Hemorrhagic transformation of ischemic stroke: prediction with CT perfusion. *Radiology* 2009; **250**: 867-77. doi: 10.1148/radiol.2503080257
- Lin K, Zink WE, Tsiouris AJ, John M, Tekchandani L, Sanelli PC. Risk assessment of hemorrhagic transformation of acute middle cerebral artery stroke using multimodal CT. *J Neuroimaging* 2012; **22**: 160-6. doi: 10.1111/j.1552-6569.2010.00562.x

22. Zussman BM, Boghosian G, Gorniak RJ, Olszewski ME, Read KM, Siddiqui KM, et al. The relative effect of vendor variability in CT perfusion results: a method comparison study. *AJR Am J Roentgenol* 2011; **197**: 468-73. doi: 10.2214/AJR.10.6058
23. Toni D, Fiorelli M, Bastianello S, Sacchetti ML, Sette G, Argentino C, et al. Hemorrhagic transformation of brain infarct: predictability in the first 5 hours from stroke onset and influence on clinical outcome. *Neurology* 1996; **46**: 341-5. PMID: 8614491
24. Hom J, Dankbaar JW, Soares BP, Schneider T, Cheng SC, Bredno J, et al. Blood-brain barrier permeability assessed by perfusion CT predicts symptomatic hemorrhagic transformation and malignant edema in acute ischemic stroke. *AJNR Am J Neuroradiol* 2011; **32**: 41-8. doi: 10.3174/ajnr.A2244
25. Alexandrov AV, Black SE, Ehrlich LE, Caldwell CB, Norris JW. Predictors of hemorrhagic transformation occurring spontaneously and on anticoagulants in patients with acute ischemic stroke. *Stroke* 1997; **28**: 1198-202. PMID: 9183351
26. Tong DC, Adami A, Moseley ME, Marks MP. Prediction of hemorrhagic transformation following acute stroke: role of diffusion- and perfusion-weighted magnetic resonance imaging. *Arch Neurol* 2001; **58**: 587-93. doi: 10.1001/archneur.58.4.587
27. Campbell BC, Christensen S, Levi CR, Desmond PM, Donnan GA, Davis SM. Cerebral blood flow is the optimal CT perfusion parameter for assessing infarct core. *Stroke* 2011; **42**: 3435-40. doi: 10.1161/STROKEAHA.111.618355.
28. Borst J, Marquering HA, Beenen LF, Berkhemer OA, Dankbaar JW, Riordan AJ. Effect of extended CT perfusion acquisition time on ischemic core and penumbra volume estimation in patients with acute ischemic stroke due to a large vessel occlusion. *PLoS One* 2015; **10**: e0119409. doi: 10.1371/journal.pone.0119409