

Images in clinical medicine

Duplication cyst of the esophagus

Tanja Šubic,¹ Breda Jamar,² Marija Dolensšek²

¹General Hospital of Novo mesto, Novo mesto, Slovenia

²Clinical Institute of Radiology, Clinical Centre, Ljubljana, Slovenia

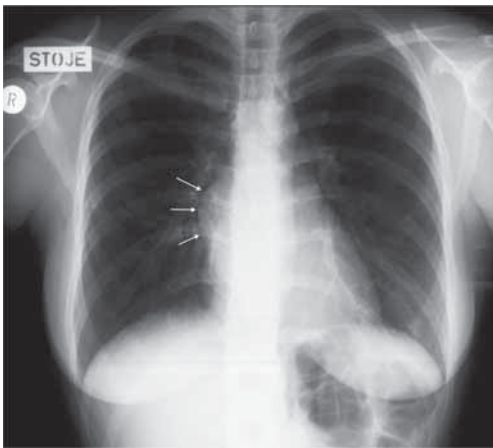


Figure 1. Chest X-ray showed a homogenous, well delineated, half-circular bulge of right mediastinum at the level of the left atrium.

A 24 years old female, previously healthy, complained for fever and severe retrosternal pain. Chest X-ray showed a homogenous, well delineated, half-circular bulge of right mediastinum at the level of the left atrium (Figure 1), and antibiotic treatment alleviated the symptoms. Afterwards barium swallow, and CT of chest were performed. On

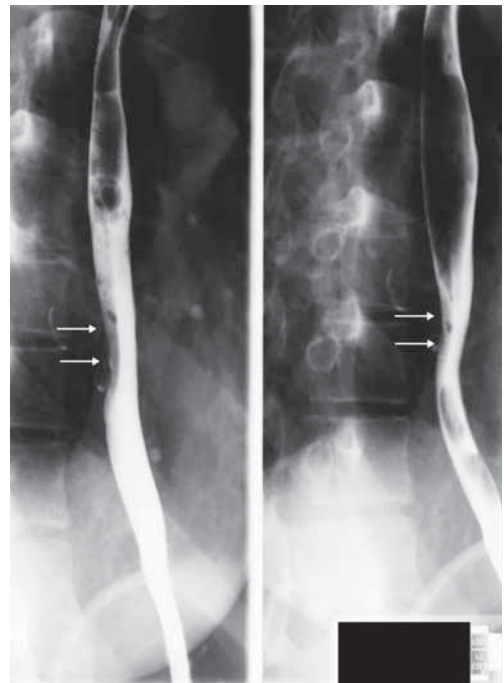


Figure 2. On barium swallow a semi-circular impression on the right side of the middle third of esophagus is seen.

barium swallow (Figure 2) a semi-circular impression on the right side of the middle third of esophagus is seen, the wall in this segment is rigid and peristalsis weak. Thin band of contrast medium is leaking out of the lumen. MDCT scans (Figures 3 and 4) showed an air-filled oval formation within the right posterior mediastinum. A com-

Received 13 June 2006

Accepted 20 June 2006

Correspondence to: Tanja Šubic, MD, General Hospital of Novo mesto, Šmihelska cesta 1, 8000 Novo mesto, Slovenia.

munication between the esophagus and the formation cannot be demonstrated.

Clinical features and radiological examinations suggest this formation most likely to be the duplication cyst of the esophagus. Other possible diagnoses are bronchogenic cyst, mediastinal lymphadenopathy, esophageal diverticuluma and neurinoma.

This rare congenital anomaly is mostly asymptomatic and represents an incidental finding on chest X- ray. Our patient had clinical symptoms because of cyst inflammation. Surgery was performed and a fibrotic, purulent structure, adherent to surrounding structures, was removed. Histology confirmed the radiological diagnosis.

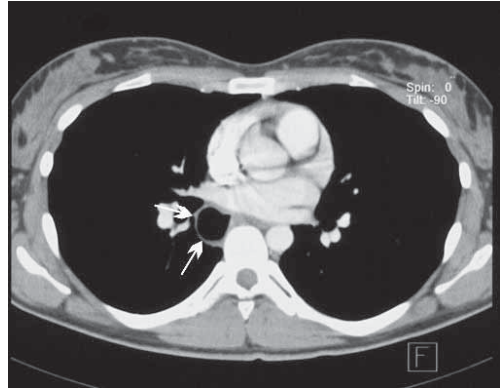


Figure 3. MDCT scans showed an air-filled oval formation within the right posterior mediastinum.

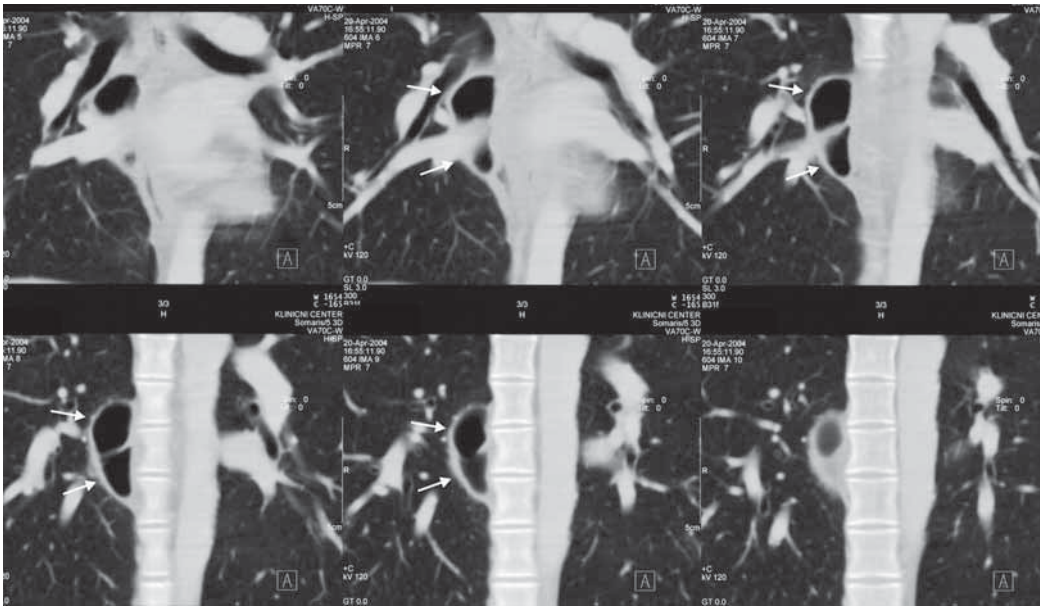


Figure 4. MDCT coronal reconstructions showed an air-filled oval formation within the right posterior mediastinum.