

## case report

# Erlotinib in previously treated non-small-cell lung cancer

Uroš Smrdel, Viljem Kováč

Department of Radiotherapy, Institute of Oncology Ljubljana, Ljubljana, Slovenia

---

**Background.** Erlotinib is a novel biological anti-tumour agent in the treatment of advanced non small cell lung cancer. It represents the molecularly-targeted therapy which has been studied extensively.

**Case report.** We present a case of a patient who suffered from advanced non-small-cell lung cancer. After the progress of disease following a prior chemotherapy he was treated with erlotinib with remarkable effect which was shown at chest x ray and symptoms were quite reduced.

**Conclusions.** In selected patients with advanced non-small-cell lung cancer Erlotinib improves survival and symptom control as it results in presented case.

*Key words:* carcinoma, non-small-cell lung; antineoplastic agents

---

## Introduction

In Europe lung cancer ranks first among all cancers and cancer related deaths in men and fourth in women. Similarly in Slovenia lung cancer ranks first in men with 787 new cases in year 2002 and fifth in women with 258 cases.<sup>1</sup> Between 80 - 85% of cases are non small cell lung cancers. A majority of patients is presented in advanced or locally advanced stages, and therefore these patients are not candidates for potentially curative resection. In patients with advanced disease our current treatment of choice is platinum based

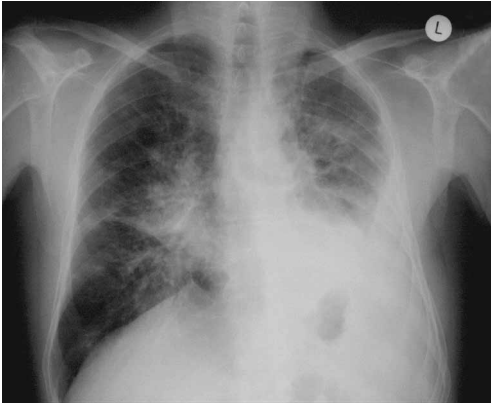chemotherapy with the newer agents, mostly with gemcitabine in the initial setting.<sup>2,3</sup> For patients who progress after achieving response to the primary treatment therapeutic option is the treatment with taxanes (e.g.docetaxel),<sup>4</sup> pemetrexed<sup>5</sup> or a novel antitumour agent in a clinical trial.<sup>6-8</sup>

Over the past few years, a number of new agents have become available for the treatment of metastatic non-small-cell lung cancer, including the inhibitors of receptors of tyrosine kinase.<sup>9,10</sup> Such a novel biological antitumor agent is erlotinib (Tarceva).<sup>11,12</sup> Erlotinib is a small molecule inhibitor of HER1/EGFR tyrosine kinase; chemically it belongs to the quinazoline class and is orally available.<sup>13</sup> It binds to an intracellular part of epidermal growth factor receptor and decreases tumour proliferation, invasion, metastases formation angiogenesis and tumour cell adhesion, while it increases apoptosis and probably also the sensitivity to

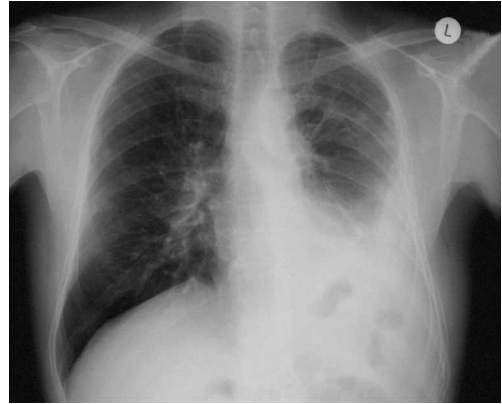
Received 15 February 2006

Accepted 28 February 2006

Correspondence to: Uroš Smrdel, M.D., Department of Radiotherapy, Institute of Oncology; Zaloška 2, 1000 Ljubljana, Slovenia; Phone +386 1 5879 622; Fax +386 1 5879 400; E-mail: usmrdel@onko-i.si



**Figure 1.** Lung tumour after chemotherapy; visible nonhomogenous lung infiltrates



**Figure 2.** Lung tumour two month after therapy with erlotinib; lung infiltrates in regression

chemotherapy. Among patients with non-small-cell lung cancer who receive erlotinib, the presence of an EGFR mutation may increase responsiveness to the agent, but it is not indicative of a survival benefit.<sup>14,15</sup>

In 2005 we enrolled in the study treatment with erlotinib through Tarceva EAP (extended access protocol). In this report we would like to present a case of our first patient treated with erlotinib.

### Case report

Fifty-eight-year old male patient was presented for the first time in year 2003. He suffered from fatigue and dyspnoea on exercise. These symptoms lasted for two years.

The patient was a former smoker who smoked for 30 years up to 20 cigarettes a day; seven years ago he stopped smoking.

On chest X ray there was a left sided pleural effusion and indurated right hilus.

Bronchoscopy revealed stenosis of the middle lobe bronchus and bronchus for the 6<sup>th</sup> left lobe, where mucosa was also granulated and bled at touch.

Histologically invasive adenocarcinoma was confirmed in specimen taken at bronchoscopy. Cytology of pleural effusion was twice negative at malignant cells.

At the clinical examination we found a lymph node at the right supraclavicular region.

The initial stage at diagnosis was T4N3Mx; re-evaluation of native chest X rays showed metastatic lesions in both lungs, therefore the stage was T4N3M1.

The patient was in good condition, Karnofsky performance status at the time of diagnosis was assessed at 80%.

The patient received chemotherapy with cisplatin and gemcitabine in the prolonged infuse for 6 cycles, the maximal response was stagnation. The leading symptom was dyspnoea.

Ten months after the completion of treatment chest X ray showed a progressing in lung, while the performance status deteriorated gradually.

In February 2005 the patient started the treatment with erlotinib. At the beginning of the treatment chest x ray showed the left sided pleural effusion, with patchy infiltrates centrally in both lungs, while in the periphery there were multiple small nodular lesions (Figure 1).

After a month of the treatment with erlotinib the patient's general condition improved and his breathing improved too. Of the adverse effects he presented with GII rash.

The improvement was seen also in chest X ray, with diminishing and rarefication of nodes shown in the periphery and also with the improvement of centrally located infiltrate.

After two months of the treatment there was a further regression of all lesions seen on X ray (Figure 2).

The patient resumed with his work as a public employee.

Until January 2006 the patient was in a partial remission. He was employed; his only complaint was rash, which persisted.

Upon progression the patient had more infiltrates on X ray, his performance status was still excellent (Karnofsky 90).

The patient continued treatment with chemotherapy with paclitaxel and carboplatinum.

## Discussion

In advanced non small cell lung cancer the aim of the treatment is to improve the survival and the quality of life (ref. meta-analysis).<sup>3</sup>

The survival in advanced non small cell lung cancer is still not as good as in some other types of advanced cancer (e. g. breast).<sup>16,17</sup> The treatment with platinum based doublets had achieved some degree of the disease control but the survival remains in range of 9 months to 1 year.<sup>16,18</sup> This has been improved slightly by the introduction of the second line chemotherapy with docetaxel or pemetrexed, which have a moderate efficacy and is reasonably well tolerated.<sup>4,5,8</sup>

However, the mode of action of erlotinib differs from that of less specific agents - both, in terms of anti-tumour activity and side effects.<sup>19</sup> The use of erlotinib is not connected with any significant degree of nausea and vomiting, the main side effect remains rash, which is usually well manageable and does not interfere with everyday functioning.<sup>21</sup>

Care should be taken of diarrhoea, which can be potentially life threatening so it is vital to ensure the patient's compliance with regimen and understanding of specific side effects.<sup>22</sup> Oral medication is usually preferred over i. v. infusion. But one must bear in mind that specific targeting of erlotinib means also that a significant proportion of patients receiving the drug will not benefit from it and that those would therefore benefit from early discontinuation and change of the treatment strategy.

We can, therefore, presume that in selected patients, erlotinib not only improves the survival, but also improves the quality of life.<sup>8,15</sup> According to the study by Sheppard *et al.*, this beneficial effect is not restricted only to female Asian non-smokers with lung adenocarcinoma but also to other patients as our patient witness.<sup>6</sup>

However, a careful monitoring of patient is needed and a discontinuation of the treatment at first signs of progressive disease and the reconsideration of other treatment options is warranted.

Our patient was not chemonaive, but received only the first line chemotherapy, so there is still a chance that he will respond to the second line chemotherapy. Furthermore, as his performance status improved, he is now probably a better candidate for the further treatment.

## Conclusions

The patient we are presenting has clearly benefited from the treatment with erlotinib. However, even though he has progressed after a year of the treatment he is still in a better clinical condition as before the treatment, likewise, despite his progression, radiologically his tumour burden is still smaller than before the treatment.

## References

1. Cancer Registry of Slovenia. *Cancer incidence in Slovenia 2000*. Report No. 44. Ljubljana: Institute of Oncology Ljubljana; 2005.
2. Schiller JH, Harrington D, Belani CP, Langer C, Sandler A, Krook J, et al, for the Eastern Cooperative Oncology Group. Comparison of four chemotherapy regimens for advanced non-small-cell lung cancer: *N Engl J Med* 2002; **346**: 92-8.
3. Kovač V, Srnrdel U. Meta-analyses of clinical trials in patients with non-small cell lung cancer. *Neoplasma* 2004; **51**: 334-40.
4. Barlesi F, Jacot W, Astoul P, Pujol JL. Second-line treatment for advanced non-small cell lung cancer: a systematic review. *Lung Cancer* 2006; **51**: 159-72.
5. Hanna N, Shepherd FA, Fossella FV, Pereira JR, De Marinis F, von Pawel J, et al. Randomized phase III trial of pemetrexed versus docetaxel in patients with non-small-cell lung cancer previously treated with chemotherapy. *J Clin Oncol* 2004; **22**: 1589-97.
6. Shepherd FA, Rodrigues Pereira J, Ciuleanu T, Tan EH, Hirsh V, Thongprasert S, et al; National Cancer Institute of Canada Clinical Trials Group. Erlotinib in previously treated non-small-cell lung cancer. *N Engl J Med* 2005; **353**: 123-32.
7. Thatcher N, Chang A, Parikh P, Rodrigues Pereira J, Ciuleanu T, von Pawel J, et al. Gefitinib plus best supportive care in previously treated patients with refractory advanced non-small-cell lung cancer: results from a randomised, placebo-controlled, multicentre study (Iressa Survival Evaluation in Lung Cancer). *Lancet* 2005; **366**: 1527-37.
8. de Marinis F, De Santis S, De Petris L. Second-line treatment options in non-small cell lung cancer: a comparison of cytotoxic agents and targeted therapies. *Semin Oncol* 2006; **33(1 Suppl 1)**: S17-24.
9. Giaccone G. Epidermal growth factor receptor inhibitors in the treatment of non-small-cell lung cancer. *J Clin Oncol* 2005; **23**: 3235-42.
10. Miller VA. Optimizing therapy in previously treated non-small cell lung cancer. *Semin Oncol* 2006; **33(1 Suppl 1)**: S25-31.
11. Perez-Soler R. The role of erlotinib (Tarceva, OSI 774) in the treatment of non-small cell lung cancer. *Clin Cancer Res* 2004; **10(12 Pt 2)**: 4238s-40s.
12. Tang PA, Tsao MS, Moore MJ. A review of erlotinib and its clinical use. *Expert Opin Pharmacother* 2006; **7**: 177-93.
13. Tamura K, Fukuoka M. Molecular target-based cancer therapy: tyrosine kinase inhibitors. *Int J Clin Oncol* 2003; **8**: 207-11.
14. Johnson BE, Janne PA. Epidermal growth factor receptor mutations in patients with non-small cell lung cancer. *Cancer Res* 2005; **65**: 7525-9.
15. Tsao MS, Sakurada A, Cutz JC, Zhu CQ, Kamel-Reid S, Squire J, et al. Erlotinib in lung cancer - molecular and clinical predictors of outcome. *N Engl J Med* 2005; **353**: 133-44.
16. Non-small Cell Lung Cancer Collaborative Group. Chemotherapy in non-small cell lung cancer: a meta-analysis using updated data on individual patients from 52 randomised clinical trials. *Brit Med J* 1995; **311**: 899-909.
17. Pompe-Kirn V, Zakotnik B, Zadnik V. *Cancer patients survival in Slovenia*. Ljubljana: Institute of Oncology Ljubljana; 2003. p. 30-4.
18. Le Chevalier T, Scagliotti G, Natale R, Danson S, Rosell R, Stahel R, et al. Efficacy of gemcitabine plus platinum chemotherapy compared with other platinum containing regimens in advanced non-small-cell lung cancer: a meta-analysis of survival outcomes. *Lung Cancer* 2005; **47**: 69-80.
19. Perez-Soler R, Chachoua A, Hammond LA, Rowinsky EK, Huberman M, Karp D, et al. Determinants of tumor response and survival with erlotinib in patients with non-small-cell lung cancer. *J Clin Oncol* 2004; **22**: 3238-47.
20. Krause DS, Van Etten RA. Tyrosine kinases as targets for cancer therapy. *N Engl J Med* 2005; **353**: 172-87.
21. Ramalingam S, Belani CP. Molecularly-targeted therapies for non-small cell lung cancer. *Expert Opin Pharmacother* 2005; **6**: 2667-79.
22. Blackhall FH, Rehman S, Thatcher N. Erlotinib in non-small cell lung cancer: a review. *Expert Opin Pharmacother* 2005; **6**: 995-1002.

*Radiol Oncol 2006; 40(1): 39-42.*

---

## Erlotinib pri zdravljenju nedrobnoceličnega raka pljuč

Smrdel U, Kovač V

**Izhodišča.** Erlotinib je novo biološko protitumorsko zdravilo, ki ga uporabljamo pri bolnikih z nedrobnoceličnim rakom pljuč. Predstavlja molekularno tarčno terapijo, ki so jo zelo intenzivno proučevali v kliničnih študijah.

**Prikaz primera.** Predstavljamo bolnika, ki smo ga obravnavali zaradi razširjene oblike nedrobnoceličnega raka pljuč. S kemoterapijo smo dosegli stagnacijo bolezni, ki je po desetih mesecih ponovno napredovala. Splošno stanje se je izrazito poslabšalo. Že po enem mesecu ponovnega sistemskega zdravljenja, tokrat z erlotinibom, so simptomi izzveneli in na rentgenski sliki prsnih organom vidimo znatno zmanjšanje bolezenskih sprememb (delno remisijo).

**Zaključki.** Pri izbranih bolnikih z nedrobnoceličnim rakom pljuč lahko erlotinib podaljša preživetje in znatno zmanjša simptome bolezni.

*Radiol Oncol 2006; 40(1): 43-9.*

---

## Fitoheماغlutinin kot modulator DNK popravljanih mehanizmov merjenih s številom kromosomskih aberacij in z mikronukleus testom po obsevanju z ionizirajočim sevanjem

Đurinec M, Želježić D in Garaj-Vrhovac V

**Izhodišča.** Obstaja korelacija med sposobnostjo popravila poškodb DNK in sposobnostjo delitve celic. Zato je bil namen študije ugotoviti vpliv fitoheماغlutinina (PHA) na sposobnost popravila DNK poškodb pri izoliranih humanih limfocitih, obsevanih z ionizirajočim sevanjem.

**Metode.** Limfociti so bili izolirani na Fikol gradientu. Za obsevanje celic smo uporabili <sup>60</sup>Co izvor proizvajalca Alcon. Celice so bile obsevane 1,24 minut pri sobni temperaturi, tako smo dosegli absorbirano dozo 2 Gy. Razlike v sposobnosti popravila DNA poškodb smo merili s številom kromosomskih aberacij in z mikronukleus testom 48 in 72 ur po PHA stimulaciji.

**Rezultati.** Število dicentričnih in acentričnih kromosomov je bilo signifikantno povečano pri celicah, ki so bile stimulirane s PHA takoj po obsevanju, ne pa pri celicah, kjer smo dodali PHA 1, 2 ali 4 ur kasneje. Mikronukleus test ni pokazal signifikantnih razlik v distribuciji ne glede na čas dodanega fitoheماغlutinina.

**Zaključek.** Rezultati nakazujejo, da fitoheماغlutinin ne vpliva signifikantno na popravljalne mehanizme DNK.

*Radiol Oncol 2006; 40(1): 57-62.*