

## Imaging of small amounts of pleural fluid. Part one – small pleural effusions

Igor Kocijančič

Department of Radiology, Institute of Oncology, Ljubljana, Slovenia

---

**Background.** Small pleural effusions are not readily identified on conventional radiographic views of the chest, but may be an important finding, sometimes leading, via thoracocentesis, to a definitive diagnosis of pleural carcinomatosis, infection or transudate.

A small meniscus sign and a medial displacement of the costophrenic angle are the only subtle signs of small accumulations of fluid on posteroanterior chest X-rays. On lateral views the finding of a small meniscus sign in the posterior costophrenic angle is the sign of small pleural effusion.

**Conclusions.** Lateral decubitus chest radiographs were used for many years for the diagnosis of small pleural effusions. In last decades ultrasonography of pleural space becomes a leading real-time method for demonstrating small pleural effusions.

*Key words:* pleural effusion; thoracic radiography

---

### Introduction

Small amount of fluid (5-20 ml) is often present in the pleural space of healthy individuals.<sup>1</sup> The data on the smallest amount of pleural fluid detectable by imaging methods vary considerably, but they are essentially within the same broad range whether computed tomography, sonography or X-ray examination are used.<sup>2-10</sup> With the advent of sonography it was shown that very small amounts of pleural fluid can be demonstrated on this way.<sup>3-8</sup>

Received 15 September 2005

Accepted 25 September 2005

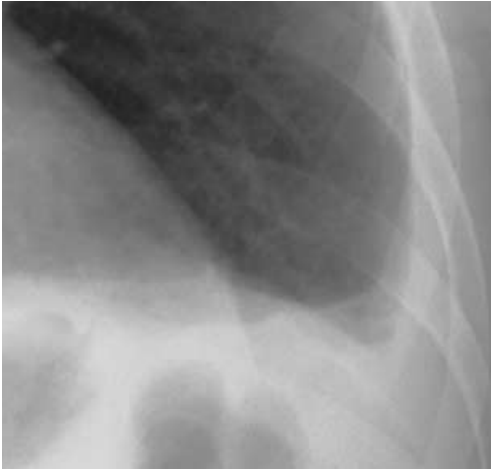Correspondence to: Assist. Prof. Igor Kocijančič, MD, PhD, Department of Radiology, Institute of Oncology, Zaloška 2, SI - 1000 Ljubljana; Slovenia; Phone: + 386 1 587 9 505; Fax.: + 386 1 587 9 400; E-mail: ikocijan-cic(onko-i.si)

In the literature there are only a few articles comparing the thickness of the pleural effusion as seen on sonography with X-ray and the amount of aspirated fluid. In addition, there is no clear consensus definition of a small pleural effusion on sonography. So, our term of small pleural effusions includes clinically silent effusions, which are usually unexpected findings on x-ray and/or ultrasonographic (US) examinations undertaken for different reasons.

### Conventional chest radiography

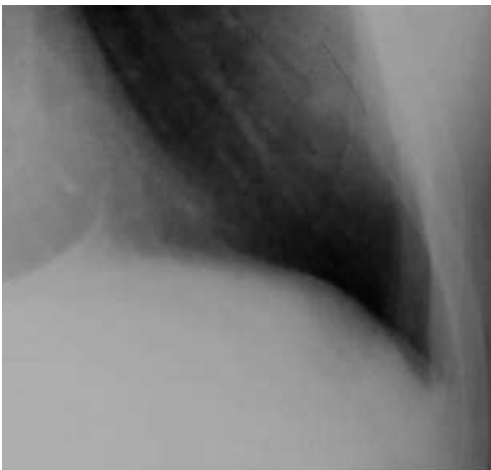#### *a) Erect posteroanterior (PA) views*

The term small pleural effusion cannot be used for the pleural fluid clearly visible on PA chest films, since it is known that the amo-

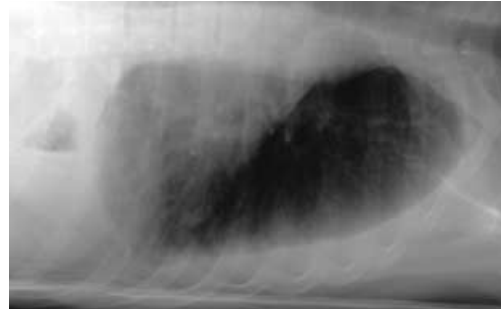


**Figure 1a.** Erect chest x-ray: a small meniscus sign in the left phrenicocostal sinus.

units of 175 to 500 ml could be hidden in the pleural space on such views.<sup>11</sup> In the early stage with the patient in the upright position, the fluid tends to accumulate in the infrapulmonary position if the pleural space is free of adhesions and the lung is healthy, forming subpulmonary effusion. In general, it is agreed that gravity is probably the main factor of the location of fluid although some investigators implicated the elasticity of the lung, basal atelectasis and surface tensions as well.<sup>12,13</sup> Nearly simultaneously with the infrapulmo-



**Figure 2a.** Only medial displacement of costophrenic angle on erect chest X-ray.



**Figure 1b.** Left lateral decubitus view: more than 1.5 cm thick fluid layer (approximately 300 ml of pleural fluid).

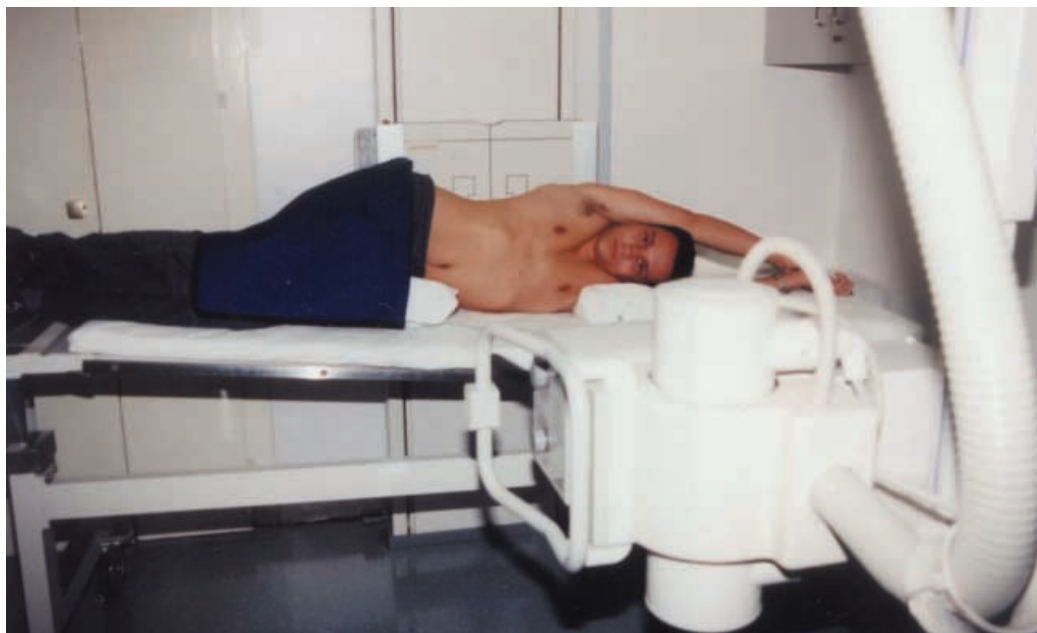nic accumulation, the pleural fluid will appear in the costophrenic sulcuses and can be seen as a medial displacement of the costophrenic angle first and with blunting of the diaphragm afterwards.<sup>12</sup>

Davis *et al.*<sup>14</sup> has shown that the upper limit of a free pleural effusion is horizontal and is located about the level of the apex of the meniscus shaped density. The x-ray beam traverses a greater depth of the fluid in the periphery of the thorax where the fluid is tangential to the beam.<sup>15</sup>

We proposed that a *small meniscus sign* (Figures 1a, 1b) and a *medial displacement of the costophrenic angle* (Figures 2a, 2b) are the only subtle signs of small accumulations of fluid on PA views. In these cases 200-300 ml of fluid can be evacuated from the pleural space<sup>13,16</sup> and that there is probably some residual fluid after thoracocentesis as well. We disagree with the authors who claim that a meniscus sign with blunting of one half of the he-



**Figure 2b.** About one cm thick fluid layer (approximately 200 mm of fluid) on the the left lateral decubitus view.



**Figure 3.** The patient's position during chest X-ray examination in left lateral decubitus position. After leaning 5 min with elevated hip in slight Trendelenburg position, the exposure with central X-ray beam aimed to the lateral thoracic wall was done.

mi diaphragm is the sign of small pleural effusion.<sup>17,18</sup>

#### b) Erect lateral views

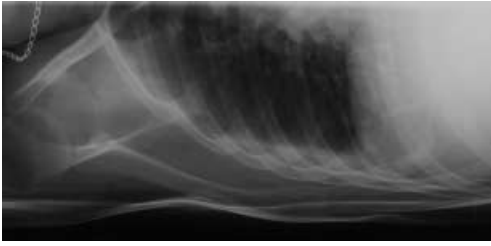
In the study on roentgen pathology models Collins<sup>11</sup> showed that as little as 25 ml of pleural fluid (injected saline) on lateral erect chest radiograms could be detected as a subpulmonic accumulation of fluid in posterior costophrenic sulcus, but only with the presence of coexisting pneumoperitoneum. This is less reliable in practice, so we proposed the finding of a *small meniscus sign* in the posterior costophrenic angle as the sign of small pleural effusion on lateral views.

Some authors<sup>13,19</sup> also suggested that the junction of the major fissure with the diaphragm may commonly be the site of small amounts of small pleural effusions on lateral erect chest radiograms. The sign is described as a straight triangular shadow at the anterior diaphragmatic contour. We claim that it is

difficult to interpret the sign without previous lateral chest x-rays and in the cases of superimposing fat in anterior mediastinum.

#### c) Lateral decubitus views

Lateral decubitus chest radiographs were used for many years for the diagnosis of small pleural effusions. This position was first mentioned in the work of Rigler.<sup>20</sup> Other investigators<sup>19,21</sup> have developed the technique and, using cadaveric studies,<sup>2</sup> have shown that volumes of pleural fluid as little as 5 ml may be detected. Rigler<sup>20</sup> did not use exposure in expiration, however, nor did he expose with central beam aimed at the lateral chest wall, parallel to the expected fluid level. The latter technical improvement was introduced by Hessen<sup>19</sup> together with the elevation of the patient's hip (Figure 3), while the exposure in expiration is mentioned in the work of Müller and Löfstedt,<sup>21</sup> but apparently without gaining wider acceptance.




**Figure 4.** One cm thick fluid layer of pleural fluid in the right lateral decubitus position in a patient with systemic connective disease.

The amounts of pleural fluid detected this way have been assessed in cadaveric experiments<sup>2</sup> to as little as 5 ml in experimental conditions. This is probably less reliable in practice, due to the inexact results of thoracentesis.

In the lateral decubitus position, the criteria for small pleural effusions is a density of at least 3 mm (but not exceeding 15 mm) thick, with horizontal level at lateral dependent chest wall (Figure 4).

The study of Kocijančič *et al.*<sup>22</sup> showed that lateral decubitus views taken in expiration contributed essentially to the diagnostic sensitivity of radiological examination as the fluid layer thickness changed during inspiration-expiration. The improved technique tends to facilitate the diagnosis of small pleural effusions (Figures 5a, 5b) and increased the ability to recognize artefacts such as skin folds, sheets and subcutaneous fat.

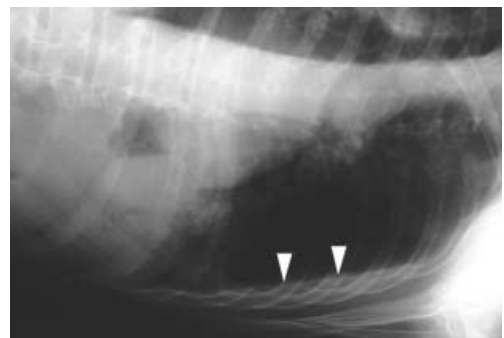


**Figure 5a.** Left lateral decubitus chest x-ray radiograph in a patient with left lower lobe lung cancer. The exposure taken during inspiration showed no pleural effusion.

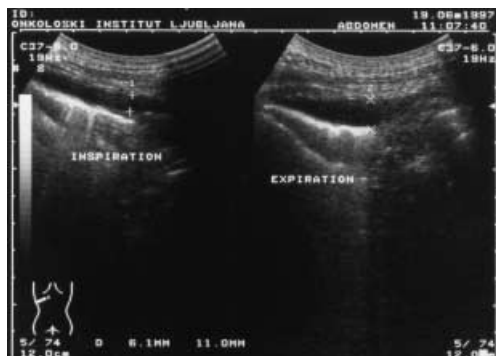## Chest ultrasonography

In last decades ultrasonography (US) of pleural space becomes a leading real-time method for demonstrating small pleural effusions.<sup>23-26</sup> US criteria determining pleural effusions are: at least 3 mm thick anechogenic zone between the parietal and the visceral pleura and/or changing of fluid layer thickness between expiration and inspiration as well as changing with different positions of the patient.<sup>23-26</sup> As US is a real-time method it is very important that all sonographic measurements with the probe perpendicular to the thoracic wall should be done.

Comparing chest US with expiratory lateral decubitus radiography, Kocijančič *et al.*<sup>27</sup> showed that both seem to be efficient methods for demonstrating small pleural effusions but US appears to assess the thickness of fluid layer more accurately than radiography does. It is interesting that in this study the main sign, allowing the demonstration of the smallest effusions, was similar in both modalities: the changing of the fluid layer during inspiration – expiration (Figure 6). The fluid layer thickness between 3-15 mm was found with both examination modalities. On erect chest radiograms only a medial displacement of costophrenic angle and a small meniscus sign were detected in 40% of patients.



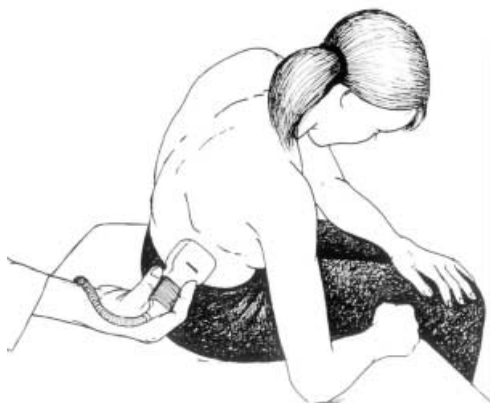**Figure 5b.** Left lateral decubitus chest x-ray radiograph in a patient with left lower lobe lung cancer. The exposure taken during expiration clearly revealed approximately 5 mm thick fluid layer.



**Figure 6.** Sonograms in a patient with right upper lobe lung cancer. Images show a thin (6 mm; calipers) fluid collection during inspiration (left image) that was more conspicuous (11 mm; calipers) during expiration (right image).

They have introduced a method of the US examination in the so called "elbow position".<sup>27</sup> The examination begins with the patient placed in the lateral decubitus position for 5 minutes first (similar to lateral decubitus chest radiography) and then the US examination performed with the patient leaning on the elbow (Figure 7). This manoeuvre allows the detection of small subpulmonic effusions, since the fluid tends to accumulate within the diaphragmatic pleurae in the erect position.

In the work of Wu *et al.*<sup>28</sup> so-called "fluid colour" sign was described as a useful indica-



**Figure 7.** Diagram shows the "elbow position" with the placement of the transducer during examination of the right pleural space.

tor for discrimination between pleural thickenings and pleural effusion and a diagnostic aid to grey scale US for minimal or loculated pleural effusions. Our opinion is that this sign is not a useful diagnostic marker when the amount of fluid is very small.

## Conclusions

Both US and "classical" radiography seem to be efficient methods for demonstrating small pleural effusions. For satisfactory results, the meticulous adherence to the techniques described (exact position of the patient during lateral decubitus radiography and during chest US examinations, perpendicular US measurements) is probably the most important.

## References

1. Noppen M, De Waele M, Li R, Gucht KV, D'Haese J, Gerlo E, et al. Volume and cellular content of normal pleural fluid in humans examined by pleural lavage. *Am J Crit Care Med* 2000; **162**: 1023-6.
2. Moskowitz H, Platt RT, Schachar R, Mellus H. Roentgen visualization of minute pleural effusion. *Radiology* 1973; **109**: 33-5.
3. Lipscomb DJ, Flower CDR. Ultrasound in the diagnosis and management of pleural disease. *Br J Dis Chest* 1980; **74**: 353-61.
4. Von Eibenberger K, Dock W, Metz V, Weinstabl C, Haslinger B, Grabenwöger F. Wertigkeit der thorax bettaufnahmen zur diagnostik und quantifizierung von pleuraergüssen - überprüfung mittels sonographie. *Fortschr Röntgenstr* 1991; **155**: 323-6.
5. Lorenz J, Börner N, Nikolaus HP. Sonographische volumetrie von pleuraergüssen. *Ultraschall* 1988; **9**: 212-5.
6. Mathis G. Lungen und pleurasonographie. Berlin: Springer-Verlag; 1992. p. 11.
7. Mc Loud TC, Flower CDR. Imaging of the pleura: sonography, CT and MR imaging. *AJR* 1991; **156**: 1145-53.

8. Mikloweit P, Zachgo W, Lörcher U, Meier-Sydow J. Pleuranage Lungenprozesse: Diagnostische wertigkeit sonographie versus CT. *Bildgebung* 1991; **58**: 127-31.
9. Leung AN, Muller NL, Miller RR. CT in the differential diagnosis of pleural disease. *AJR* 1990; **154**: 487-92.
10. Maffesanti M, Tommasi M, Pellegrini P. Computed tomography of free pleural effusions. *Europ J Radiol* 1987; **7**: 87-90.
11. Collins JD, Burwell D, Furmanski S, Lorber P, Steckel RJ. Minimal detectable pleural effusions. a roentgen pathology model. *Radiology* 1972; **105**: 51-3.
12. Rudikoff JC. Early detection of pleural fluid. *Chest* 1980; **77**: 109-11.
13. Petersen JA. Recognition of infrapulmonary pleural effusion. *Radiology* 1960; **74**: 34-41.
14. Davis S, Gardner F, Qvist G. The shape of a pleural effusion. *Brit Med J* 1963; **1**: 436-7.
15. Raasch BN, Carsky EW, Lane EJ, O'Callaghan JP, Heitzman ER. Pleural effusion: explanation of some typical appearances. *AJR Am J Roentgenol* 1982; **139**: 899-904.
16. Anzböck W, Stellamör K, Braun U, Hruby W. Die sonographie der lunge und pleura. *Fortschr Röntgenstr* 1990; **153**: 278-82.
17. Kohan JM, Poe RH, Israel RH, Kennedy JD, Benazzi RB, Kallay MC, et al. Value of chest ultrasonography versus decubitus roentgenography for thoracentesis. *Am Rev Respir Dis* 1986; **133**: 1124-6.
18. Wu RG, Yuan A, Liaw YS, Chang DB, Yu CJ, Wu HD, et al. Image comparison of real-time gray-scale ultrasound and color doppler ultrasound for use in diagnosis of minimal pleural effusion. *Am J Respir Crit Care Med* 1994; **150**: 510-4.
19. Hessen I. Roentgen examination of pleural fluid. A study of the localisation of free effusions, the potentialities of diagnosing minimal quantities of fluid and its existence under physiological conditions. *Acta Radiol* 1951; **86**(Suppl): 1-80.
20. Rigler LG. Roentgen diagnosis of small pleural effusions. *JAMA* 1931; **96**: 104 - 8.
21. Müller R, Löfstedt S. Reaction of pleura in primary tuberculosis of the lungs. *Acta Med Scand* 1945; **122**: 105-33.
22. Kocijančič I, Terčelj M, Vidmar K, Jereb M. The Value of inspiratory-expiratory lateral decubitus views in the diagnosis of small pleural effusions. *Clin Radiol* 1999; **54**: 595-7.
23. Mathis G. Thoraxsonography - part I: chest wall and pleura. *Ultrasound Med Biol* 1997; **23**: 1131-9.
24. Kocijančič I. The accuracy of chest sonography in the diagnosis of small pleural effusion. *Radiol Oncol* 2003; **37**: 13-6.
25. Eibenberger KL, Dock W, Metz V, Weinstabl C, Haslinger B, Grabenwöger F. Ranking of supine chest radiographs for diagnosis and quantification of pleural effusions – checking via sonography. *Fortschr Röntgenstr* 1991; **155**: 323-6.
26. Marks WM, Filly RA, Callen PW. Real-time evaluation of pleural lesions: new observations regarding the probability of obtaining free fluid. *Radiology* 1982; **142**: 163-4.
27. Kocijančič I, Vidmar K, Ivanovi-Herceg Z. Chest sonography versus lateral decubitus radiography in the diagnosis of small pleural effusions. *J Clin Ultrasound* 2003; **31**: 69-74.
28. Wu RG, Yang PC, Kuo SH, Luh KT. "Fluid color" sign: a useful indicator for discrimination between pleural thickening and pleural effusion. *J Ultrasound Med* 1995; **14**: 767-9.