

## Keratocysts in the jaws

Aleksander Lipovec, Nataša Ihan Hren

Clinical Department of Maxillofacial and Oral Surgery, University Medical Centre Ljubljana, Slovenia

---

**Background.** Jaw cysts are a common pathology; among them, the odontogenic keratocysts (OKC) represent a special group because of their aggressive growth and recurrence.

**Patients and methods.** We established retrospectively the epidemiology and clinical characteristics of OKC among all the pathohistologically confirmed jaw cysts that had been surgically cured in the past ten years (from 1994 to 2003) at the Clinical Department of Maxillofacial and Oral Surgery, University Medical Centre in Ljubljana.

**Results.** Among 992 surgically removed jaw cysts, 106 were OKC (10.6% of all). Pathohistological diagnosis of OKC was confirmed in 90 patients, in 51 men (56.7%) and 39 women (43.4%). Mean age of patients with OKC at the time of treatment was 36 years. The youngest one was 7 years old, the oldest one 83 years. Seventy-four (69.8%) of OKC were removed from the lower jaws, 32 (30.2%) from the upper jaws. As to the location, OKC (49 cases - 46.2%) predominated in the angles and vertical branches of the lower jaw. Recurrence rate after the first removal of OKC was 22.2% (in 20 patients). First recurrence occurs most frequently (in 70%) within the first 5 years after primary treatment; the mean time till the first recurrence was 4 years and 7 months. Multiple recurrences of OKC were observed in 9 patients (10% of all patients with OKC). Five of the patients with OKC had the syndrome of basal cell carcinoma (Gorlin-Goltz Sy.). We found out that one third of OKC were clinically unexpected in regard to their untypical locations in the jaws.

**Conclusions.** It is critical for the jaw cysts to be pathohistologically examined. The number of cases of OKC among all jaw cysts in our study is significantly larger (3.5-time) than in the previous epidemiological study in Slovenia; but this may be the consequence of previous underdiagnosis of that pathology entity. Our study is comparative with other similar foreign studies in literature in respect to the patient's sample and epidemiological results.

Key words: jaw cysts – pathology; odontogenic cysts - epidemiology

---

### Introduction

Received 27 May 2004

Accepted 17 June 2004

Correspondence to: Assist. Prof. Nataša Ihan Hren, MD, PhD, Department of Maxillofacial and Oral Surgery, University Medical Centre, Zaloška 2, Ljubljana, Slovenia; Phone: +386 1 522 43 54.

Cysts in the facial bones are similar to other cystic changes elsewhere in the human skeleton regarding their morphology and structure. Because of the presence of the developmental dental and nondental epithelium and

the teeth with surrounding tissues in the jawbone, the cysts are much more common in the jaws than anywhere else. They occur as pathological unicentric or multicentric cavity, where the liquid, solid masses or gas accumulate, but not as the consequence of pus accumulation.<sup>1</sup> The cysts are usually, but not always, surrounded with the epithelium, which differs in morphogenesis and structure.<sup>2</sup> The most common characteristic of cysts is the bone defect – the radiolucent area on X-rays, which can cause different clinical signs predominantly because of their sizes or secondary infections. Other causes of bone defects are odontogenic and bone tumours, but they are much more rare in a jawbone than in other parts of human skeleton.<sup>3</sup> Among them are also very rare bone defects caused by tumour metastases, mostly of adenocarcinomas (tumours in the breasts, bronchus, kidneys).<sup>4</sup> They are so important because they can be the first clinical sign.

Jaw cysts are nonodontogenic and odontogenic; the latter are more common. Two thirds of odontogenic cysts are of inflammatory origin (radicular, residual cysts); follicular cysts (in approximately 15% of all cysts), keratocysts or a few others are rarer.<sup>3</sup>

Odontogenic keratocysts (OKC) were recognized as a special pathologic entity very late. Among the cysts, they are considered as a peculiar group because of their aggressive growth and great recurrence; they therefore require more radical surgical treatment (the removal with surrounding bone) and prolonged clinical follow-up. Pathohistologically, they are divided into para- and ortho-keratinous types of OKC. Regarding their pathogenesis, they are benign neoplasms.<sup>5</sup> Figures 1a and 1b show 2 typical panoramic X-rays of OKC.

In 1945, Robinson described primordial cysts as the consequence of impaired dental enamel organ. Later, their appearance was associated with the developmental disturbance of dental lamina. These cystic bone lesions were first named OKC by Philipsen in 1956, which became also their official term in the WHO classification of cysts in 1971.<sup>1,2</sup>

Among the jaw cysts, the frequency of OKC in different studies ranges from 3.2 to 11.25%.<sup>2,6</sup> The factors which influence the growth and development of OKC are still unknown; they can be either in the epithelium of a cyst or in the connective tissue of its capsula.<sup>6</sup> As OKC are detected in the patients

**Table 1.** The incidence of the pathohistologically proved cysts from 1994 to 2003

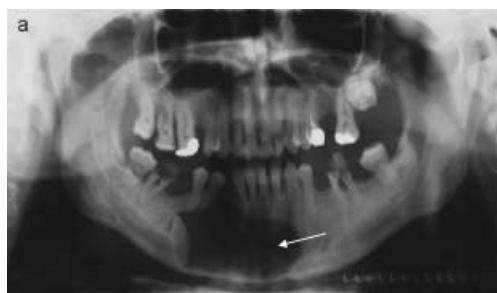| Cyst / Year             | 1994 | 1995 | 1996 | 1997 | 1998 | 1999 | 2000 | 2001 | 2002 | 2003 | Σ   | %     |
|-------------------------|------|------|------|------|------|------|------|------|------|------|-----|-------|
| Radicular               | 17   | 14   | 11   | 18   | 33   | 57   | 86   | 82   | 98   | 114  | 530 | 53.5  |
| Dentigerous             | 9    | 5    | 2    | 2    | 9    | 17   | 16   | 5    | 8    | 16   | 89  | 9.0   |
| Residual                | 2    | 2    | 2    | 1    | 6    | 13   | 19   | 13   | 8    | 15   | 81  | 8.2   |
| Eruption                | 1    | 0    | 0    | 0    | 0    | 0    | 0    | 0    | 1    | 0    | 2   | 0.2   |
| Odontogenic keratocysts | 7    | 1    | 5    | 9    | 7    | 6    | 9    | 16   | 21   | 25   | 106 | 10.6  |
| Gingival cyst of adults | 0    | 0    | 0    | 0    | 2    | 0    | 0    | 0    | 1    | 0    | 3   | 0.3   |
| Lateral periodontal     | 0    | 1    | 0    | 0    | 1    | 0    | 0    | 0    | 1    | 0    | 3   | 0.3   |
| Calcifying odontogenic  | 0    | 0    | 0    | 0    | 0    | 0    | 0    | 0    | 0    | 1    | 1   | 0.1   |
| Solitary bone           | 1    | 0    | 1    | 0    | 2    | 1    | 2    | 1    | 1    | 1    | 10  | 1.0   |
| Pseudocyst              | 0    | 1    | 0    | 0    | 0    | 0    | 1    | 0    | 0    | 0    | 2   | 0.2   |
| Nasolabial              | 0    | 0    | 0    | 0    | 0    | 0    | 0    | 1    | 0    | 0    | 1   | 0.1   |
| Nasopalatine            | 0    | 0    | 0    | 2    | 2    | 1    | 1    | 0    | 3    | 1    | 10  | 1.0   |
| Unknown                 | 16   | 18   | 27   | 21   | 15   | 19   | 11   | 9    | 11   | 7    | 154 | 15.5  |
| Σ                       | 53   | 42   | 48   | 53   | 76   | 114  | 145  | 127  | 153  | 180  | 992 | 100.0 |

aged between 7 and 93 years, they can arise in any life period.<sup>7</sup> The size of OKC is from 0.1 to 10.0 centimetres in diameter, the mean size at the time of their detection is 4 to 5 cm.<sup>8</sup> They grow for 2 to 14 millimetres per year; their growth is slower after the age of 50.<sup>9</sup> In literature, a great possibility of recurrence after the removal of the primary OKC in the same place or in their neighbourhood was described (3 to 62%, mean possibility is 30%).<sup>6</sup>

In 1960, Gorlin and Goltz first described the syndrome of three main signs: multiple cells-cells carcinomas of the skin, multiple jaw OKC and rib changes. OKC are a permanent and clinically important sign. Later, this syndrome was named nevoid basal-cells carcinoma syndrome. It is inherited dominantly autosomally and has a high level of genetic penetrance with prevalence of 1 : 60 000.<sup>6,10</sup>

In the differential diagnosis of OKC before pathohistologic examination, we must also consider tumour ameloblastoma, whose similarity arises from the same origin – the dental lamina; the ameloblastoma can also arise from OKC epithelium.<sup>7</sup> In addition, the transformation in orthokeratinous epithelium of OKC to planocellular carcinoma has also been described.<sup>8</sup>

The purpose of our study was to establish the frequency and characteristics of OKCs, which had been surgically cured in the past ten years (from 1994 to 2003) in Clinical Department of Maxillofacial and Oral Surgery, University Medical Centre in Ljubljana.



**Figure 1a.** Panoramic X-rays of OKC in lower jaw at 37 years-old man.

## Patients and methods

We removed and pathohistologically examined 992 cysts in the lower and upper jaws from 930 patients from the beginning of 1994 to the end of 2003. On the basis of pathohistologic examinations, we retrospectively surveyed all medical documentation of these patients (all diagnostic procedures, treatment and post-operative controls).

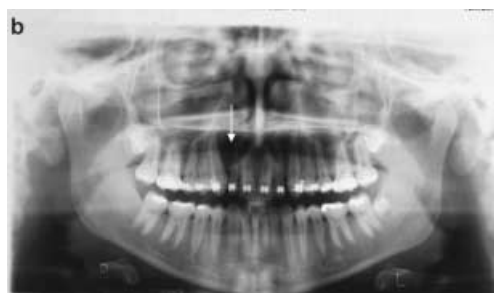We determined the basic statistical characteristics. Table 1 presents the frequency of different cysts in the observed years.

## Results

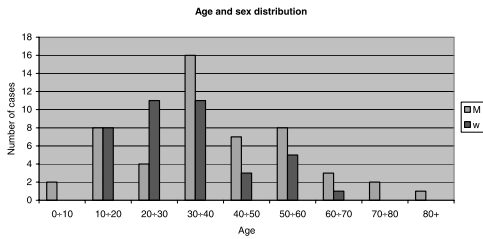
In the period from 1994 to 2003, we surgically removed 992 pathohistologically proved cysts at our department. Of them, 105 were OKC, which represented 10.6% of the cysts of oromaxillofacial region (Figures 1a, 1b).

In the observed period, pathohistological diagnoses of OKC were confirmed in 90 patients. Of them, 51 were in men with the mean age of 39 years and 39 in women with the mean age of 33 years. The mean age of all patients with OKC at the time of treatment was 36 years. The youngest one was 7 years old, the oldest one 83 years. Figure 2 represents the distribution of the observed patients by sex and age.

Seventy four OKC were removed from the lower jaws (69.8% of all OKC) and 32 from the upper jaws (30.2% of all OKC). Regarding



**Figure 1b.** Panoramic X-rays of OKC in upper jaw at 19 years-old woman.



**Figure 2.** Patients with OKC by the sex and age intervals.

the location, they predominated in the angles and vertical branches of the lower jaw (in 49 cases, 46.2% of all OKC). The characteristic cases of that predilection location are shown in Figures 3a, 3b and 3c.

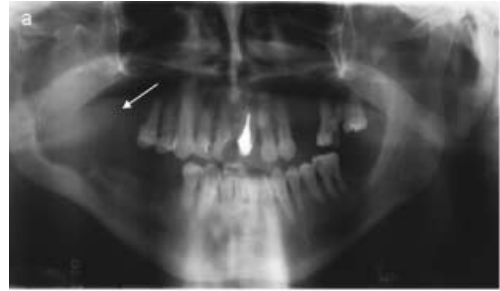Recurrence rate after the first removal of OKC was 22.2% (20 of 90 patients). The first recurrence is the most frequent (in 70%) within the first 5 years after the primary treatment, the mean time until the first recurrence being 4 years and 7 months. The longest time between the first treatment of OKC and diagnosis of its first recurrence was 15 years. Multiple recurrences of OKC occurred in 9 patients (10% of all patients with OKC).

Among the patients with OKC, 5 had the syndrome of basal cell carcinoma (NBCCS, Gorlin-Goltz syndrome). Two of them had multiple basal-cells carcinomas. One patient, 10 years old at the time of diagnosis NBCCS, was hereditarily predisposed, as his mother had the same illness.

We established that, in 31 patients, OKC was clinically unexpected before pathohistologic examination; the pathohistologic examination then confirmed it was OKC.

## Discussion

All the patients examined here were treated at the Clinical Department of Maxillofacial and Oral Surgery, University Medical Centre Ljubljana. At this institution, orodental pathologies of the patients from Ljubljana region are treated and it is also the Slovenian

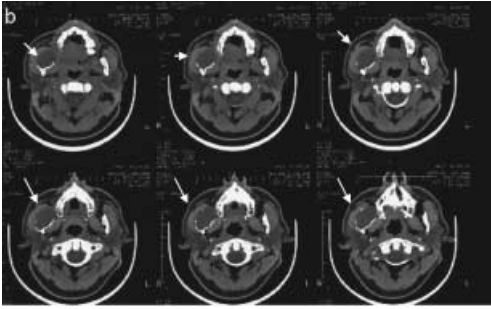


**Figure 3a.** The characteristic tomogram radiograph (panoramic x-ray) of OKC on predilection location (the angles and vertical branches of the lower jaws) in the right side.

referral clinic that treats the most complicated cases of orodental pathologies of the patients from the whole country. All patients treated at our clinic were included into this study, viz. also the patients with extremely large OKC or those with OKC in the neighbourhood of vitally important structures. The consequence of this is that the percentage of OKC among the jaw cysts reported here is greater than that in Slovenia's population.

The smallest OKC in our study are from 0.5 to 1 centimetre in diameter and they predominate in the upper jaws. In clinical and radiological aspects, this means that these OKC are commonly removed as inflammatory odontogenic pathology without being pathohistologically examined. In these cases, OKC are often overlooked. This also means that these overlooked OKC are not treated and controlled adequately.

At our Department, we were already studying the jaw cysts for a ten-year period from 1984 to 1993. Our research was based on pathohistological diagnostics.<sup>11</sup> The present study from 1994 to 2003 is the continuation of that one. We observed 3.5-times more OKC in the last decade than in the former one. During the first study, the OKC pathologies were rarely recognised; they were recognised in fewer cases than expected from the literature data. Interestingly, OKC were first pathohistologically recognised only in 1982.



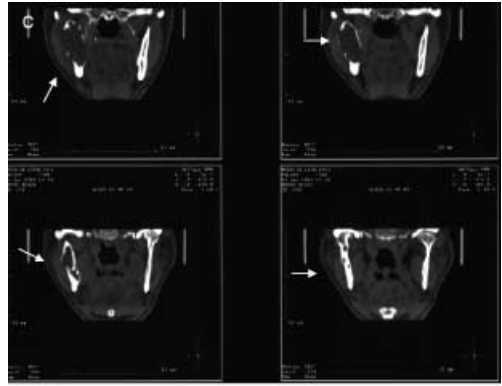
**Figure 3b.** The characteristic computer tomography image (axial CT) of OKC on predilection location (the angles and vertical branches of the lower jaws). CT images show perforation of OKC in the right mandibula ramus.

Among the jaw cysts, the frequency of OKC was 10.6% in the period 1994 -2003. This percentage agrees well with the literature data of 3.2 to 21.8%;<sup>2,6,8</sup> in fact, it is approximately in the middle.

The ratio of men to women with OKC is 1.28 to 1; the predominance of men with OKC is mentioned also by other authors.<sup>7,12,13</sup> The age structure of the patients with OKC in our study is similar to other's data. In 1992, Shear reported that OKC in elderly population was often discovered late because of a few and delayed clinical signs.<sup>2</sup> In our study, 34.4% of patients came in our institution without any clinical signs; later, the cavities in the jaws were accidentally found on the radiographs done by their dentists.

The ratio of OKC in the lower against the upper jaw is 2.3 to 1. The higher occurrence of OKC in the lower jaws is reported throughout the literature. The ratios of OKC location in the lower to the upper jaws are from 1.9 : 1 to 4.9 : 1 according to different authors and our findings are within the described range.<sup>7,14</sup>

The recurrence rates of OKC after the first surgical removal differ from one author to another and are within the range of 10.4%<sup>15</sup> to 39%.<sup>13</sup> During the observed period, the recurrences of OKC were observed in 20 of our patients (22.2% of all OKC patients). The multi-



**Figure 3c.** The characteristic computer tomography image (coronal CT) of OKC on predilection location (the angles and vertical branches of the lower jaws). CT images show perforation of OKC in the right mandibula ramus.

ple recurrences were observed in 9 patients (in 10% of cases). According to the data from literature, multiple recurrences are ranging from 2.8%<sup>7</sup> to 4.6%.<sup>14</sup> The mean time until the first recurrence of OKC in our study is 4 years and 7 months, while Brannon reported that this time was 4 years and 10 months.<sup>7</sup>

The presence of OKC in children or adolescents before the age of 19 is, in 75% of cases, the first sign of NBCCS.<sup>6</sup> Four patients in our study with NBCCS had OKC before the age of 19.

According to literature, the first recurrence is the most frequent within the first 5 years after primary treatment in 75% of cases, whereas according to our data, it occurs in 70% of cases.<sup>3,5</sup> Some authors described the recurrence even 20 years after primary treatment.<sup>2</sup> In our study, the longest time until the first recurrence was 15 years. So, while the regular clinical and radiograph controls of patients with OKC in the first 5 years after the primary surgery are necessary, the patients with NBCCS have to be checked once a year throughout their lifetime.

The treatment of OKC is more radical than of the other jaw cysts. Because of the aggressive nature of OKC, it is necessary to remove the wall of the cyst and all bone adjacent to

the wall colonised by the cysts epithelium islands and buds. When the bone is totally destroyed by the cyst, this can spread to the soft tissue, which must be removed entirely. In order to diminish the cases of unrecognised OKC, the pathohistologic examinations of all cyst tissue is always necessary, as in our study, there were 37 surprise cases of OKC (34.8% of all OKC) discovered through the diagnostic procedures, radiographs and clinical diagnosis of other odontogenic cysts.

Maxillofacial and oral surgeons in Slovenia have approximately 10% possibility that the jaw cyst is OKC. These cysts must be recognised by the pathohistologic examinations to be adequately treated and to assure to the patients to receive adequate clinical follow-up.

### References

1. Kramer IRH, Pindborg JJ, Shear M. *Histological typing of odontogenic tumours*. 2<sup>nd</sup> edition. Berlin: Sprienger-Verlag; 1992. p. 35-6.
2. Shear M. Odontogenic keratocyst (primordial cyst). In: Shear M, editor. *Cysts of the Oral Regions*. 3<sup>rd</sup> edition. Oxford: Butterworth-Heinemann; 1992. p. 4-45; 246-8.
3. Cawson RA, Odell EW. *Essentials of oral pathology and oral medicine*. Toronto: Churchill Livingstone; 1998. p. 132.
4. Sapp JP, Eversole LR, Wsocki GP. *Contemporary oral and maxillofacial pathology*. St Louis: Mosby; 2004. p. 203-4.
5. Shear M. Odontogenic tumors and cysts with both unicystic and multicystic variants. Are the cysts benign tumors? In: *Cystic lesions of the maxillofacial area*. 6<sup>th</sup> Salzburg weekend seminar 1998. p. 47-51.
6. Budnick S. Odontogenic cysts. In: Gale N, Luzar B, editors. 19<sup>th</sup> European Congress of Pathology Pre-meeting. Head and neck pathology proceedings. Ljubljana; 2003. p. 122-32.
7. Brannon RB. The odontogenic keratocyst. A clinicopathologic study of 312 cases. Part I. Clinical features. *Oral Surg Oral Med Oral Pathol* 1976; **42**: 54-72.
8. Verbin RS, Barnes L. Cysts and cyst-like lesions of the oral cavity, jaws and neck. In: Barnes L, editor. *Surgical pathology of the head and neck*. 2nd edition. New York: 2001. p. 1439-555.
9. Shear M. The odontogenic keratocyst. In: *Cystic lesions of the maxillofacial area*. 6<sup>th</sup> Salzburg weekend seminar 1998. p. 34-7.
10. Williams TP, Hellstein JW. Odontogenic cysts of the jaws and other selected cysts In: Fonseca RJ, editor. *Oral and maxillofacial surgery - 5*. Surgical pathology. 1<sup>st</sup> edition. Saunders Co; 2000. p. 310-6.
11. Ihan-Hren N. Pogostnost cist v čeljustih zadnjih 10 let. *Zobozdr Vest* 1995; **50(1-2)**: 13-5.
12. Woolgar JA, Rippin BDS, Browne RM. The odontogenic keratocyst and its occurrence in the nevoid basal cell carcinoma syndrome. *Oral Med Oral Pathol* 1987; **64**: 727-30.
13. Hodgkinson DJ, Woods JE, Dahlin DC, Tolman DE. Keratocysts of the jaw: clinicopathologic study of 79 patients. *Cancer* 1978; **41**: 803-13.
14. Browne RM. The odontogenic keratocyst clinical aspects. *Br Dent J* 1970; **128**: 225-31.
15. Kakarantza-Angelopoulou E, Nicolatou O. Odontogenic keratocysts: clinicopathologic study of 87 cases. *J Oral Maxillofac Surg* 1990; **48**: 593-9.