

## Dedicated small bowel follow-through - experience of Clinical Institute of Radiology in Ljubljana

Mateja Kropivnik and Breda Jamar

Clinical Institute of Radiology, University Medical Centre, Ljubljana, Slovenia

---

**Background.** Small bowel is a difficult part of the alimentary tract to examine. Radiologic modality most commonly used has been the conventional small bowel follow-through (SBFT), which has often been done in a cursory manner, without fluoroscopy and manual palpation. The purpose of our study is to present dedicated SBFT and to assess its sensibility and specificity.

**Patients and methods.** We analysed 35 dedicated SBFT, performed from April to September 2002, in patients. Findings were evaluated according to clinical follow-up, endoscopy and surgery.

**Results.** Our findings were consistent with clinical follow-up, endoscopy and surgery in 33 patients. In 2 patients our findings were false negative. Our results show 89.5 % sensitivity and 100 % specificity.

**Conclusions.** An adequate per-oral examination remains the most reliable tool for diagnostic evaluation of the small bowel.

*Key words:* intestine, small - radiology; barium sulfate; enema; Crohn disease

---

### Introduction

Small bowel is a difficult part of the alimentary tract to examine because of its anatomy. Proximal jejunum and the terminal ileum can also be examined by enteroscopy but the mesenteric small intestine is the part of alimentary tract in which radiologic examinations are dominant diagnostic procedures.<sup>1</sup>

The radiologic examinations of the small

bowel include barium studies and newer imaging methods: ultrasound (US), computerised tomography (CT) and magnetic resonance imaging (MRI).

For many years, the radiologic modality most commonly used to evaluate small bowel disease has been the conventional small bowel follow-through (SBFT). After *per oral* intake of barium suspension, periodic overhead radiographs were made until the barium suspension reached the colon. Spot radiographs were obtained of the terminal ileum and any other areas of abnormality suggested on the overhead radiographs.<sup>2</sup> Fluoroscopy and palpation were used sparingly or not at all.

For dedicated SBFT, larger amounts of barium suspension must be taken to fill all seg-

Received 25 February 2003

Accepted 10 March 2003

Correspondence to: Breda Jamar, M.D., Clinical Institute of Radiology, University Medical Centre, Zaloška 7, 1000 Ljubljana, Slovenia; Email: breda.jamar@kclj.si

ments of the small bowel. Careful fluoroscopy, vigorous manual palpation and appropriate spot radiographs are routine components of the examination.

Enteroclysis, a double contrast examination needs a intubation catheter with a guide-wire positioned just beyond the ligament of Treitz for direct injection of contrast medium into the jejunum.<sup>3</sup> The injection should be fast enough to allow moderate distension without completely abolishing peristalsis.<sup>4</sup> During the filling phase, the different loops are watched for mobility, distension and integrity. Spot films are taken and an overview made when the whole small bowel is filled. Several variations are possible: single contrast enteroclysis or air/water or methylcellulose insufflation for double contrast.<sup>5,6</sup>

Newer imaging methods are valuable tools in assessing intestinal wall and extraluminal involvement.

Gastrointestinal-related disease may be an occasional incidental observation on US examination which should lead to appropriate further investigation.<sup>7</sup> In experienced hands bowel US is an accurate technique for assessing extend and anatomical location of disease within the bowel.<sup>8</sup>

CT has the ability to depict pathology outside the intestinal lumen and in this way contributes to the imaging of the small bowel disease.<sup>7</sup> The accuracy of small-bowel spiral CT studies depends on the presence of well distended loops and adequate endoluminal opacification.<sup>5</sup>

In spiral CT enteroclysis, the administration of water soluble iodinated contrast agent by intubation during fluoroscopy is needed.<sup>9</sup>

MR is not a primary imaging method for the small bowel. It is limited by the mobility of the bowel and by the lack of a reliable intraluminal contrast agent.<sup>7</sup> Owing to excellent soft tissue contrast and multiplanar imaging capabilities, MR imaging could be the optimal imaging method for evaluation of small-bowel in the future.<sup>10</sup>

The aim of our study was to assess the sensibility and specificity of detailed-dedicated SBFT, as performed at our department.

### Patients and methods

From April to September 2002 92 dedicated SBFT were performed at the department of gastrointestinal radiology.

Of these, we analysed 35 consecutive patients who were referred by gastroenterologists because indications were more specific and follow-up was possible.

The average age of the patients was 42 years (range, 23-64 years), 14 were male and 21 female.

The referral diagnoses were: food allergy in 1 patient, abdominal pain in 2, abdominal pain with diarrhoea in 4, coeliac disease in 2, suspected Crohn's disease in 16 and reactivation of known Crohn's disease in 10 patients.

Dedicated small bowel follow-through was performed with oral administration of 4x200 ml diluted barium suspension: 600 ml of water added to 200 ml of Micropaque. Fluoroscopy was done during the ingestion of the first 200 ml of barium. The oesophagus and the stomach were examined fluoroscopically. The first spot radiograph was obtained when suspension reached the duodenojejunal flexure.

The patient was given the second glass of barium and after 15-20 minutes an overhead film was taken, and compression and palpation of all segments, filled with barium, was done during fluoroscopy. After the ingestion of the third and fourth glasses of barium all segments of small bowel were opacified in most cases, as well as the terminal ileum and the caecum. Motility was observed during fluoroscopy and careful manual compression of the small bowel was done, before a spot film was taken, to document radiologic findings.

Our findings were evaluated according to clinical follow-up, endoscopy and surgery.

## Results

We analysed 35 dedicated SBFT. Our results show 89.5% sensitivity and 100% specificity of dedicated SBFT. All of 17 patients with abnormal findings on SBFT were abnormal at confirmation method giving the proportion of correct diagnoses as  $17/17 = 100\%$  (positive predictive value). Similarly, among the 18 patients with normal SBFT the proportion of correct diagnosis was  $16/18 = 88.8\%$  (negative predictive value) (Table 1).

**Table 1.** The accuracy of small bowel follow-through (SBFT)

SBFT	Abnormal	Normal	Total
Abnormal findings	17	0	17
Normal findings	2	16	18
<b>Total</b>	<b>19</b>	<b>16</b>	<b>35</b>

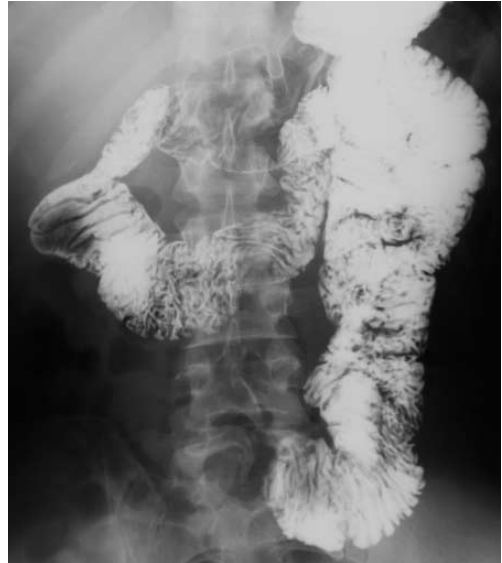The patient with food allergy has normal findings on SBFT. Endoscopic examination and clinical diagnosis was dyspepsia.

In one case of suspected coeliac disease, thickened folds in duodenum were seen on SBFT. Erosive gastritis and duodenitis were found at gastroduodenoscopy. The patient with longstanding coeliac disease had radiologic findings in the small bowel consistent with coeliac disease and lymphoma both confirmed by histology.

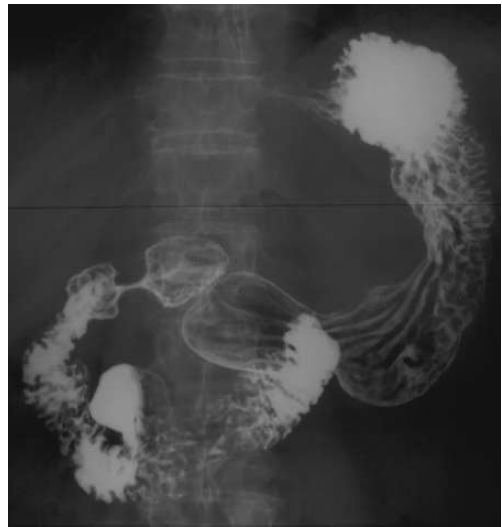Four patients with abdominal pain and diarrhoea had normal radiologic findings. The absence of small bowel pathology was consistent with clinical follow-up.

Two patients had pain in the upper abdomen: in one case the compression of the third part of duodenum, caused by superior mesenteric artery, was found; in the second case, a 4 cm large diverticulum in the second part of duodenum was seen (Figures 1, 2).

Among 16 patients with suspicion of Crohn's disease, the radiologic findings were positive in 5, the diagnosis was later confirmed by endoscopy and biopsy. In 11 patients with negative radiologic findings, en-



**Figure 1.** Compression of pars horizontalis duodeni by superior mesenteric artery.

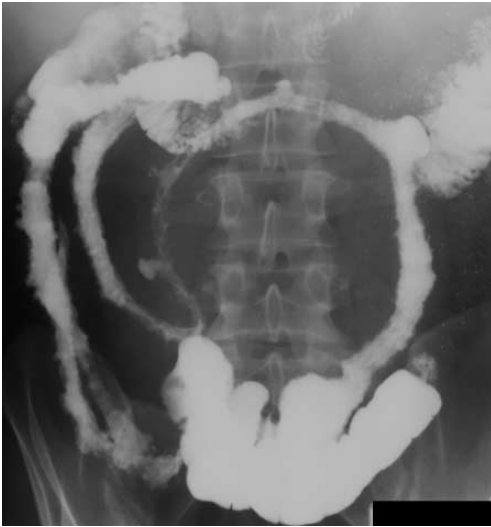

**Figure 2.** Duodenal diverticulum.

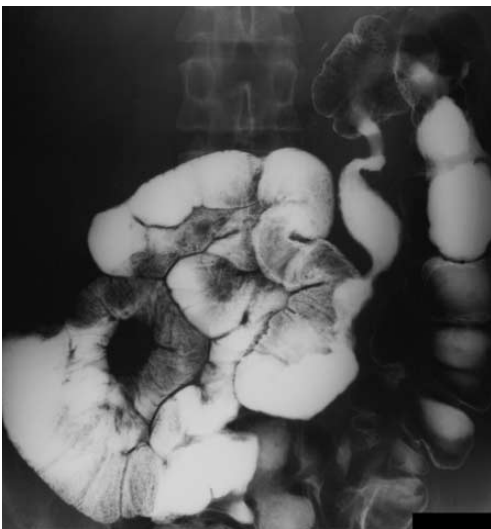
doscopic findings were negative in 9, but in two coloileoscopy with biopsy showed inflammatory changes in the terminal ileum (Figure3).

Ten patients had known Crohn's disease and suspected reactivation. Five of them had previous surgery. In 4 ileotransversoanasto-

mosis stenosis was found on SBFT, confirmed by surgery. One patient had a resection of terminal ileum. Inflammatory changes of distal ileum, seen on SBFT, were confirmed endoscopically (Figure 4). In 2 cases the findings on SBFT were normal; at coloileoscopy the inflammatory changes were seen in transversal part of large bowel, but terminal ileum



**Figure 3.** Crohn's disease of the small bowel.



**Figure 4.** Crohn's disease at ileotransverso-anastomotic site.

was normal. In 3 cases radiologic changes of Crohn's disease were found in terminal ileum and our findings were confirmed on endoscopy.

## Discussion

The prevalence of small-bowel disease is low and the clinical diagnosis is difficult by non-specific symptoms and a low index of suspicion.<sup>1</sup>

In patients with non-specific abdominal complaints US is often the first examining method. The main drawback of US is insufficient visualisation of intestinal lumen due to luminal collapse and presence of gas obscuring the underlying bowel.

The limitations of the radiologic investigation of the small-bowel with oral contrast material have long been recognized.<sup>6</sup>

The dilemma between SBFT as more acceptable to the patient, and the uncomfortable intubation-infusion method (enteroclysis) has not been resolved.<sup>6</sup>

Disadvantage of the conventional SBFT is a risk of overlooking an important abnormality, predominantly on overhead radiographs, which display the opacified small bowel as closely packed, overlapping loops. The major drawback is insufficient use of fluoroscopy and palpation.

Enteroclysis has been promoted as more accurate in the detection of early mucosal changes. The superiority of enteroclysis is controlled introduction of contrast material into the small bowel, luminal distension, small bowel hypotonia secondary to jejunal distension, relative rapidity of completion of the study, and the use of double contrast material.<sup>6</sup> The disadvantages of enteroclysis is the lack of universal availability, higher radiation dose, discomfort during intubation and inability to examine for gastroduodenal disease.

Carefully performed SBFT with frequent

fluoroscopy, manual palpation and appropriate spot radiographs has been shown to achieve results comparable to enteroclysis.<sup>2</sup>

It has some advantages over enteroclysis because of its simplicity, near-universal availability, a high level of patient tolerance, the opportunity to assess the gut in a relatively physiologic state of distension and distensibility, the possibility to evaluate the duodenum and a relatively low radiation dose to the patient.<sup>11</sup>

The sensitivity of enteroclysis in suggested inflammatory bowel disease (IBD) was found to be higher in most of the studies.<sup>12</sup> However, the specificity and the positive predictive value was somewhat higher concerning dedicated follow through examination. Higher sensitivity of enteroclysis probably reflects in a tendency to use it more frequently with specific symptoms of IBD. In the same way dedicated follow-through examination was probably used when symptoms were non-specific.<sup>12</sup>

No gross differences were found in sensitivity, specificity or predictive values, when dedicated follow-through examination and enteroclysis were compared.<sup>4,12</sup>

In our study specificity was 89.5%, because our findings were false negative in two patients. On retrograde evaluation the missed radiologic signs were attributed in one case to overlapping segments of distal ileum and insufficient palpation, in the second case the changes of Crohn's disease were not specific on coloileoscopy, but confirmed by biopsy.

This indicates that the dedicated follow-through technique may be used for screening purposes.<sup>12</sup>

Average skin entry radiation dose for enteroclysis was 1.5 times greater than that for SBFT with upper gastrointestinal examination and almost 3 times greater than for dedicated SBFT.<sup>10</sup>

Enteroclysis is not indicated in young patients with low suspicion of pathology.<sup>11</sup>

It should be borne in mind that bowel US

is highly operator dependent, requiring experience and time to achieve accuracy rates comparable with those published in the literature.<sup>8</sup>

The major disadvantages of CT and MRI are that these modalities are expensive and not universally available.

Factors to be considered when selecting the appropriate technique include the reason for the examination, the age of the patient, time and cost involved, patient acceptance, radiation exposure and accuracy.<sup>13</sup>

## Conclusions

An adequate per-oral examination depends largely on the use of a dedicated small bowel technique, emphasising fluoroscopic observation and spot radiographs of compression of all segments of small bowel.

The dedicated SBFT has a number of advantages for use as a screening examination, including the need for less room and radiologist time, less radiation exposure and high sensitivity when the examination is carefully performed.

Conventional SBFT has no role in present-day small bowel radiology.

## References

1. Maglante DDT, Lappas JC, Kelvin FM, Rex D, Chernish SM. Small bowel radiology: how, when, and why? *Radiology* 1987; **163**: 297-305.
2. Wills JS, Lobis IF, Denstman FJ. Crohn disease: state of the art. *Radiology* 1997; **202**: 597-610.
3. Rosenbuch G, Jansen JBMJ, Reeders JWAJ. Contemporary radiological examination of the small bowel. *Baillieres Clin Gastroenterol* 1994; **8**(4): 863-700.
4. Nolan DJ. Imaging of the small bowel. *Schweiz Med Wochenschr* 1998; **128**(4): 109-14.
5. Maglante DDT, Chernish SM, Kelvin FM, O'Connor KW, Hage JP. Crohn disease of the

- small intestine: accuracy and relevance of enteroclysis. *Radiology* 1992; **184**: 541-5.
6. Cirillo LC, Camera L, Della Noce M, Castiglione F, Mazzacca G, Salvatore M. Accuracy of enteroclysis Crohn's disease of the small bowel: a retrospective study. *Eur Radiol* 2000; **10**: 1894-8.
  7. Gore RM, Levine MS. *Gastrointestinal radiology*. 2nd Edition. Philadelphia: WB Saunders 2000; 67-98.
  8. Cittadini G, Giasoto V, Garlaschi G, De Cicco E, Gallo A, Cittadini G. Transabdominal ultrasonography of the small bowel after oral administration of non-absorbable anechoic solution: Comparison with barium enteroclysis. *Clini Radiol* 2001; **56**: 225-30.
  9. Mazzeo S, Caramella D, Battolla L, Melai L, Masolino P, Bertoni M, et al. Crohn disease of the small bowel: spiral CT evaluation after oral hyperhydration with isotonic solution. *J Comput Assist Tomogr* 2001; **25(4)**: 612-6.
  10. Thoeni RF, Gould RG. Enteroclysis and small bowel series: comparison of radiation dose and examination time. *Radiology* 1991; **178**: 659-62.
  11. Umschaden HW, Szolar D, Gasser J, Umschaden, Haselbach H. Small bowel disease: comparison of MR enteroclysis images with conventional enteroclysis and surgical findings. *Radiology* 2000; **215**: 717-25.
  12. Baath L, Ekberg O, Borulf S, Lindhagen T, Olsson R. Small bowel barium examination in children. *Acta Radiologica* 1989; **30**: 621-5.
  13. Ott DJ, Men Chen Y, Gelfand DW, Van Swearingen F, Munitz HA. Detailed small bowel examination vs. enteroclysis. *Radiology* 1985; **155**: 29-34.