

Endovascular treatment of intracranial arteriovenous malformations

Tomaž Šeruga

Department of Radiology, Teaching Hospital Maribor, Maribor, Slovenia

Background. The aim of the study was the introduction of endovascular interventional treatment of cerebral arteriovenous malformations (AVM) with superselective embolization with cyanoacrylic polymerisation agent.

Case reports. Endovascular embolization was performed in five patients with cerebral AVMs. Three of these patients were presented with intracerebral haematomas whereas in other two patients, cerebral AVM was an incidental finding. Superselective catheterisation of AVMs was performed and acrylic glue was selectively injected into the nidus.

Conclusions. Control cerebral angiography after embolization of AVM showed different results. In one patient, AVM was totally occluded after three sessions and in second case AVM was occluded in a single session. The rate of occlusion in other two cases was estimated between 70% in 80%. Both of these two patients underwent surgery. One patient is still in the process of treatment. Endovascular treatment of cerebral AVMs with superselective embolization with liquid cyanoacrylic adhesive agent is a safe and effective alternative treatment paths next to microsurgery. Endovascular treatment in combination with radiosurgery could become the method of choice in the therapy of cerebral AVMs in the future.

Key words: intracranial arteriovenous malformation; embolization , therapeutic; cyanoacrylic glue; microcatheter

Introduction

For a successful endovascular treatment of intracranial arteriovenous malformations (AVM) their structure and localisation must be examined closely and in detail. Detailed

position is determined only by an examination using a magnetic resonance imaging (MRI). For structure or angioarchitecture examination of AVM, the structure of its nidus must be defined accurately which may be achieved only by selective angiography. Finally, an impeccable microcatheter embolization must be carried out. Various topographic and angiographic factors are very important for choosing either surgical or endovascular treatment. Endovascular treatment can be applied as final treatment, i.e. when the AVM can be completely occluded,

Received 6 August 2002

Accepted 15 August 2002

Correspondence to: Assist. Tomaž Šeruga, M.D., M.Sc., Splošna bolnišnica Maribor, Ljubljanska 5, 2000 Maribor; Phone: +386 2 321 2248; Fax.: +386 2 321 2982; E-mail: tomaz.seruga@sb-mb.si

or when we can use it as initial part of treatment followed by microsurgical operation or radiosurgery with gamma knife.¹ The final aim of embolization is a stable occlusion of the AVM nidus with a preserved normal arterial blood flow in the adjacent brain parenchyma and with preserved venous outflow.

Intracranial AVMs are categorised as lesions of cerebral vasculature and consist of pathological vessel elements, that lead to a direct arteriovenous contact or passage without the usual capillary net. The ethiology of intracranial AVMs formation is not as yet completely established. AVMs have most likely an embryological basis in abnormal development of venous endothelium.² Intracranial AVM was first described by Pfannenstil in 1887 in post-mortem examination record. The first complete surgical excision of first AVM was carried out in 1889 by dr. Pean, a French surgeon.³

The introduction of cerebral angiography by Moniz in 1929 allowed more detailed analysis of the structure and localisation of lesions. On the other hand, new microsurgical technique also required more selective details with more distinctive angiographic analysis of blood flow within the AVM, its relation to the size and position of cerebral AVM and its relation to the circulation in adjacent brain parenchyma. Detailed analysis of AVM's haemodynamics increased the safety and radicality of the operation.

It is estimated that intracranial AVMs can be discovered in 0.2-0.8% of the North American population.⁴ The annual bleeding rate of 4% occurs in non treated AVMs. The probability of rupture and subsequent bleeding is higher when AVM contains an aneurysmal widened vessel and deep venous drainage. The size of malformation does not represent significantly higher risk of bleeding, but in microsurgical treatment there is a greater possibility of complications. Predisposition to epileptic attacks in patients with cerebral AVM is very common, especially

when the AVM lies within the temporal lobe or in motoric strips.^{5,6} Neurological deficits are caused by repeated minute bleeding, haemodynamic blood steal, stenosis of arteries, venous hypertension or mass effect because of venous anomalies. Headaches are very often a consequence of haemodynamic changes in the meningeal circulation connected with AVM, widened meningeal veins or with smaller clinically undetected bleedings.

The location of AVM and arteriovenous structure of the lesion is shown preoperatively by means of selective angiography and MRI evaluation. Angiographic evaluation of intracranial AVM requires a four-vessel angiography and additional projections of external carotid arteries. We must evaluate the feeding arteries, venous part of AVM as well as the rest of venous outflow, the flow velocity inside the lesion and the size of the nidus, its form and vein structure.⁷ MRI examination enables a better understanding of the topographic position, size and geometry of the intracranial AVM as well as spatial evaluation of the main draining veins of the malformation. MR angiography with intravenous contrast application is also of great value in AVM evaluation.

Classification of AVMs

A modification of Yasargil's classification of intracranial AVM divides malformations clinically in convex and deep AVMs.³ Convex AVMs are further subdivided into sulcal and gyral types. Deep AVMs are further divided by their relations to cerebral anatomic structures into ventricular system and deep grey matter nuclei. The cortical brain supply consists of three types of arteries that split rectangular from pial arteries and pass through the brain cortex. Regarding their nutritional role they are divided into cortical, cortico-medullary and medullary arteries.^{8,9}

Topographically, we distinguish three subgroups of convexional AVMs due to their lo-

cation to sulcal, gyral and mixed sulcal-gyral AVMs. In sulcal AVMs, the nidus lies within the subpial space of the sulcus. The AVM adjusts to the form of the sulcus and compresses the adjacent gyrus. So the shape of the malformation is triangular with apex pointed towards the ventricle or skull base. After branching of the pial arteries to the cortical and corticomedular arteries, they terminate in the nidus of the AVM. Gyral AVMs, unlike the sulcal malformations, are fully encircled by the brain parenchyma and cortex. The gyrus grows larger and compresses adjacent sulci. Because of its position inside the gyrus, the malformation outgrows branches over different pial arteries. Smaller lumen and larger number of pial arteries aggravate the access of microcatheter into the feeding artery. Mixed sulcal-gyral type of AVM is larger than both previous ones because of its localisation in subpial space, gyrus and subcortical brain parenchyma. They receive their main blood supply through mixed terminal pial arteries, but are supplied also by meningeal and basal perforating arteries. Subcortical AVM are very rare and represent less than 1 % of all AVM. They lie deep under the cortex and are supplied mostly by corticomedullar and medullar arteries and are drained by deep and surface veins.¹⁰

Deep AVMs are divided by their relation to brain structures. Subarachnoid AVMs lie inside basal cisterns and fissure and are supplied by the cisternal segments of perforating and chorioidal arteries. Parenchymal AVMs lie inside deep nuclei and are supplied mainly by basal perforating and circumferential arteries. Ventricular (plexial) AVMs originate from chorioid plexus and are supplied by terminal parts of chorioidal arteries and from subependymal branches of Willis' circle.⁹

Structure of intracranial AVM

Malformations consist of feeding arteries, nidus and draining veins. They can have one

or more compartments. A compartment consists of one or more angiographically seen feeding arteries and one draining vein. The feeding arteries which supply the major part of the AVM are known as main feeders. Other arteries have less influence on the nidus and are feeding smaller compartments of AVM. The main feeders are of larger diameter; therefore the flow through them is faster than the flow through other supplying arteries. Due to larger diameter, the feeders are more accessible for catheter embolization and have a better therapeutic prognosis. Part of AVM are also the so-called pseudoterminal feeding arteries that do not terminate in the nidus and are visualised during angiography due to suckling effect. This effect is seen as a subtle flush of unopacified blood into AVM. It requires much attention because of possible ischaemic complications that may arise due to haemodynamic changes in blood flow during embolization. The nidus of AVM is a part of malformation located between the farthest feeding artery and the nearest draining vein.^{3,4} The flow patterns of nidus are divided into three types of arteriovenous patterns: plexiform type (36%), fistulous type (11%) and mixed pattern type (53%).^{3,10} A compartment consists of one or more angiographically seen feeding arteries and one draining vein. The draining veins of AVM terminate in the surface or deep venous circulation. Higher pressure on the venous side causes the appearance of venous anomaly and pseudoaneurysms, venous infarcts, venous congestion and mass effect. Rupture of pseudoaneurysm is the most frequent reason of bleeding from AVM (41%).^{11,12} The rupture mechanism probably result from a sudden change of pressure on the arterial side and subsequent venous hypertension.¹³

Endovascular treatment technique

The aim of AVM treatment is the prevention of intracerebral bleeding and elimination of

the malformation from the circulation. When we decide on the way of treatment, we have to consider the risk of treatment, patient's neurological symptoms, general state of health, as well as the patients expectations about the effects of the treatment.^{1,14,15} The purpose of the endovascular treatment is a complete occlusion of AVM and its exclusion from the circulation. When this is not possible we opt for the partial occlusion of AVM, which increases the effectiveness of gamma knife ablation or microsurgical resection.

For the embolization of the AVM nidus, liquid cyanoacrylic polymerisation agent is used. In contact with blood polymerisation occurs and cianoacrylat glue sticks on the vessel wall. The result is a permanent occlusion of the nidus. Particles of polyvinyl alcohol, can be used for blocking the smaller veins after the embolization of the main part of the AVM. Platinum coils can also be used for AVM immobilisation. They are especially effective in the treatment of high flow arteriovenous fistulae. With their use we slow down the flow and thereby enable a safe use of cianoacrylic glue.¹⁶

Complications of endovascular AVM treatment

They are divided into complications that occur during the procedure and post-operational complications. We distinguish ischaemic and haemorrhagic complications.

Ischaemic complications can occur during catheter manipulation where haemorrhagic complications are due damaged wall vessel or disturbances in the venous outflow. When bleeding occurs during the procedure, we can see it as an extravasation of contrast medium and we can react with an instant embolization. Late complications occur within 72 hours after the operation. Sudden deterioration of the neurological status scan be identified by computer tomography examination. Oedema or minor haematomas can be treated conservatively with manitol or, if circum-

stances require, the haemathoma is surgically removed.

Case reports

Case No. 1

A 43-year old patient was submitted to a computerised tomography (CT) examination after his first epileptic attack. CT revealed a hyperdense space occupying lesion, probably a haemathoma in the left parietal lobe. Digital subtractrational angiography (DSA) revealed a large cortical AVM with plexiform type of nidus. Main feeding arteries were branches of the right anterior and posterior cerebral arteries. Venous blood was drained into the deep venous system to internal cerebral veins.

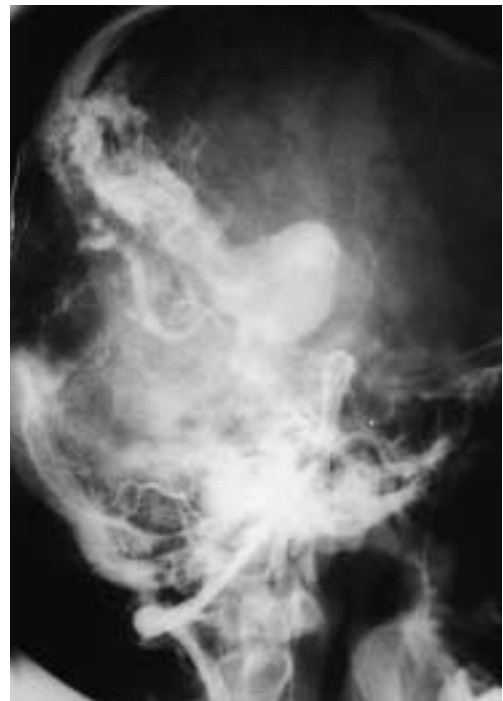

Figure 1. Angiography (without subtraction) of the right vertebral artery in lateral projection revealed large cortical AVM with deep venous drainage. Feeding arteries were branches of the medial cerebral and posterior cerebral artery.

Endovascular embolization was performed with the aim to reduce the volume of the AVM, to enable subsequent radiosurgery with gamma knife. After successful radiosurgical ablation the latest control DSA, 3 years after the last radiosurgery session, revealed a complete AVM occlusion (Figures 1, 2).

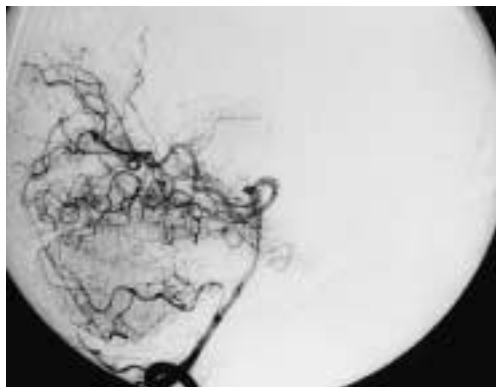


Figure 2. Control digital subtraction angiography DSA of the right vertebral artery in lateral projection 3 years after endovascular embolization of AVM and radiosurgical treatment revealed a complete occlusion of the AVM.

Case No. 2

A 24-year old patient was admitted to our hospital because of sudden onset of headache and nausea. CT examination revealed a small round hyperdense lesion, an intracerebral haemathoma in the temporooccipital part of left hemisphere. The DSA showed a deep AVM with fistulous nidus pattern. A single feeding artery was a branch of the left medial cerebral artery. Venous drainage was superficial to the sigmoid sinus. Endovascular embolization was performed and AVM was completely occluded at the end of the procedure (Figures 3, 4).

Case No. 3

CT examination in a 40 years old male patient with clinical symptoms of intracranial bleeding revealed a minor AVM in the right tem-

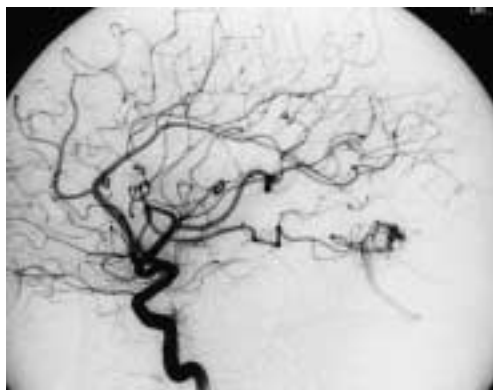


Figure 3. DSA angiography in left lateral projection showed small cortical temporo-parietal AVM with a single feeding artery arising from the left middle cerebral artery with superficial venous drainage to the sigmoid sinus.

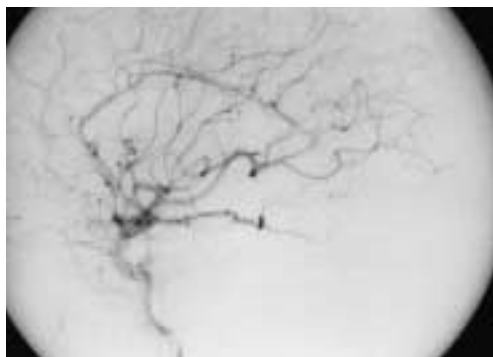


Figure 4. Control DSA after endovascular embolization revealed a completely occluded AVM at the end of the procedure.

poroparietal region. Cerebral DSA showed two feeding arteries, branches of the middle cerebral artery. Venous outflow was of superficial type. After endovascular treatment AVM was partially closed. The patient was later on treated by microsurgical resection.

Case No. 4

CT examination in a 30-year old male patient with sudden onset of headache revealed a larger cortical AVM in the right temporo-parietal region with an extensive intracerebral haemathoma, partially resorbed at the time of

endovascular treatment. Feeding arteries were branches of the right middle cerebral artery. Venous outflow was superficial and drained to the superior sagittal sinus. Superselective angiography revealed that one of the feeding arteries supplied also the adjacent brain parenchyma. It was not suitable for embolization. The other feeding artery was successfully embossed. The rest of AVM was later resected by microsurgical operation (Figures 5, 6).

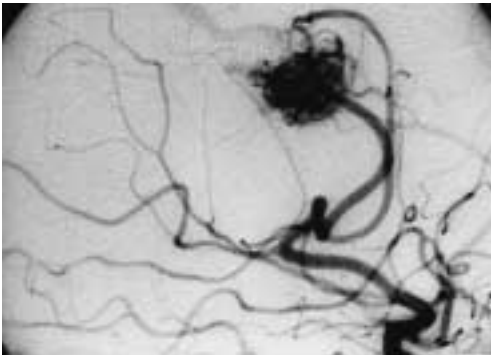


Figure 5. DSA angiography of the right internal carotid artery in a right oblique projection revealed a cortical AVM. Feeding arteries were branches of the right medial cerebral artery, the nidus was of mixed type and venous drainage was superficial to superior sagittal sinus. One of the feeding arteries supplied also the adjacent brain parenchyma and was not suitable for embolization.

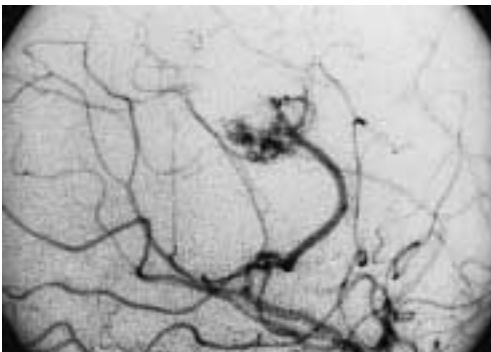


Figure 6. Control DSA in slightly more cranial oblique projection after the embolization reveals an occlusion of one of the feeding arteries with reduced size of AVM.

Case No. 5.

CT examination in a 66-year old female patient revealed an extensive intracranial bleeding in the left cerebral hemisphere. A large deep AVM in the region of corpus callosum above the lateral ventricles with the blood penetrating into the ventricular system was disclosed. Cerebral DSA showed feeding arteries arising from all three main arteries of the left hemisphere. The nidus was of mixed type with plexiform and fistulous pattern. We decided to treat the AVM by endovascular procedure in three sessions. Control DSA after the first treatment showed occlusion of approximately one third of AVM. The plan is to continue with endovascular treatment.

Discussion

Our experiences after treating five patients only are modest. We did not have any immediate or late (up to 72 hours after the procedure) complications.

In 1999, a study from a leading European centre for endovascular AVM treatment in Zurich analysed the results of embolizations carried out between 1987 and 1996.¹⁰ They treated 387 patients with intracranial AVM and carried out 710 operations. Complete obliteration was achieved in 158 cases (40,8%). In 19 cases, more than 90 % obliteration was reached, in 177 cases, the obliteration was partial (up to 50%) and in 30 cases less than 50 % obliteration rate was achieved. So, the 158 patients were treated only by embolization. In 73 cases, microsurgical resection was carried out after the embolization, and in 25 cases, radiosurgery was performed also after embolization. In 69 cases with complex AVM, a partial palliative embolization was carried out for treatment of severe chronic headaches. The remaining 62 patients were called back for further embolizations.

Early haemorrhagic complications occurred in 8 (2.0%) out of 387 patients. In 3

cases the vessel wall was perforated, in other 5 cases, bleeding followed the occlusion of the venous outflow or the rupture of pseudoaneurysm occurred. Late haemorrhagic complications occurred in 11 (2.8%) out of 387 patients. In 6 cases, immediate craniotomy was carried out, because of a rapid deterioration of the neurological status, and 5 patients were treated conservatively. The outcome of early and late complications that occurred in 19 cases was good in 11 (58%) patients, modest in 4 (21%) patients and poor in 1 (5%) case. Three patients died (16%). The analysis of 16 haemorrhagic complications, not linked with the perforation of vessel wall, showed that none of these malformations was completely closed. The most likely reason for bleeding were altered haemodynamic conditions in the venous outflow.

Ischaemic complications were evaluated by MRI in 36 (9.3%) patients out of 387. Five of these patients were asymptomatic, 18 patients had pre-existing neurological deficit. Thirteen patients had permanent neurologic deficit (3.3%). Six of them had minimal deficit, 4 had medium neurological deficit, 2 patients had poor neurological outcome and one patient died.

Conclusions

Endovascular treatment of intracranial AVM requires detailed knowledge of the anatomy of the cerebral arteries and cerebral circulation, of the structure of intracranial AVM and of its topographic position. We can simultaneously follow the changes of blood flow during the embolization and, if circumstances require, change the strategy of embolization procedure.

The success of the treatment depends on the accessibility to the nidus, which depends on anatomic circumstances, as for example, the diameter of the feeding arteries or their tortuosity.

Special preoperative treatment is important in the patients who have the predisposition for thrombotic or haemorrhagic complications. Damages of the vessel wall, which could be caused by the catheter or guide wire, should be avoided. Today, in Slovenia, the majority of AVMs are adequately treated by microsurgical operation. In order to achieve up to date standards, we have to establish the radiosurgery that, together with microsurgery and endovascular embolization, represent a method of choice of treatment of intracranial AVMs.

References

1. Vinuela F, Halbach V, Dion E.J. *Interventional Neuroradiology. Endovascular therapy of the central nervous system*. New York: Raven Press; 1992. p 167-79.
2. Lasjaunias P. A revised concept of the congenital nature of cerebral arteriovenous malformations. *Interventional Neuroradiol* 1997; **3**: 275-81.
3. Yasargil MG. *Microneurosurgery*. Stuttgart: Georg Thieme Verlag; 1987. p. 3-21.
4. Berenstein A, Lasjaunias P. *Surgical neuroangiography*. Vol 4. Heidelberg: Springer; 1991.
5. Ondra SL, Troupp H, George ED, Schwab K. The natural history of symptomatic arteriovenous malformations of the brain: A 24-year follow-up assessment. *J Neurosurg* 1990; **73**: 387-91.
6. Crawford PM, West CR, Shaw MD, Chadwick DW. Cerebral arteriovenous malformations and epilepsy: Factors in the development of epilepsy. *Epilepsia* 1986; **27**: 270-5.
7. Valavanis A. The role of angiography in the evaluation of cerebral vascular malformations. *Neuroimaging Clinics N Am* 1996; **6**: 679-704.
8. Hutchings M, Weller RO. Anatomical relationships of the pia mater to cerebral blood vessels in man. *J Neurosurg* 1986; **65**: 316-25.
9. De Reuck T. The cortico-subcortical arterial angioarchitecture in the human brain. *Acta Neurol Belg* 1972; **72**: 323-8.
10. Valavanis A, Christoforidis G. Endovascular management of cerebral arteriovenous malformations. *Neurointerventionist* 1999; **1**: 34-40

11. Muller-Forell W, Valavanis A. How angioarchitecture of cerebral arteriovenous malformations should influence the therapeutic considerations. *Minim Invasive Neurosurg* 1995; **38**: 32-40.
12. Turjman F, Massoud TF, Vinuela F, Sayre JW, Guglielmi G, Duckwiler G. Aneurysms related to cerebral arteriovenous malformations: Superselective angiographic assessment in 58 patients. *Am J Neuroradiol* 1994; **15**: 1601-5.
13. Willinsky R, Lasjaunias P, Terbrugge K, Pruvost P. Brain arteriovenous malformations: analysis of the angio-architecture in relationship to hemorrhage (based on 152 patients explored and/or treated at the hospital de Bicetre between 1981 and 1986). *J Neuroradiol* 1988; **15**: 225-37.
14. Garcia-Monaco R, Rodesch G, Alvarez H, Iizuka Y, Hui F, Lasjaunias P. Pseudoaneurysms within ruptured intracranial arteriovenous malformations: Diagnosis and early endovascular management. *Am J Neuroradiol* 1993; **14**: 315-21.
15. Marks MP, Lane B, Steinberg GK, Snipes GJ. Intranidal aneurysms in cerebral arteriovenous malformations: Evaluation and endovascular treatment. *Radiology* 1992; **183**: 355-60.
16. Vinuela F, Nombela L, Roach MR, Fox AJ, Pelz DM. Stenotic and occlusive disease of the venous drainage system of deep brain AVMs. *J Neurosurg* 1985; **63**: 180-4.
17. Vinuela F, Drake CG, Fox AJ, Pelz DM. Giant intracranial varices secondary to high-flow arteriovenous fistulae. *J Neurosurg* 1987; **66**: 198-203.