

## Evolving strategies in the treatment of childhood rhabdomyosarcoma: Slovenian experience

Živa Pohar-Marinšek<sup>1</sup>, Jožica Anžič<sup>2</sup>, Breta Jereb<sup>3</sup>

<sup>1</sup>Department of Cytopathology, Institute of Oncology, <sup>2</sup>Hemato-oncological unit, University Children's Hospital, University Medical Center, <sup>3</sup>Institute of Oncology, Ljubljana, Slovenia

---

**Background.** Neoadjuvant chemotherapy (Cht) has changed the treatment of rhabdomyosarcoma (RMS) in children. The purpose of our study was to review the children treated for RMS between 1974 and 1996.

**Patients and methods.** Fifty-one children, 1-15 years old, were included. Primary sites of tumour were: head and neck 15, orbit 6, genitourinary 12, extremity 9, torso 5 and paratesticular 4. Twelve patients were in stage I, 10 in stage II, 26 in stage III and 3 in stage IV. Of 43 histologically confirmed RMS 25 were embryonal, 13 alveolar, 1 botryoid, 1 spindle cell and 3 sarcoma NOS. In 8 patients, only fine needle aspiration biopsy (FNAB) was available. All patients had Cht, 29 neoadjuvant, 20 had surgery first, 40 had irradiation (RT), 2 stage IV patients had bone marrow transplant (ABMT). Multidrug Cht varied: VCR, AMD, and cyclophosphamide (VAC) were used in the 1970s, with Adriablastine (T2), methotrexat (MTX) and/or other drugs (T6, T11) in the 1980s, and in the 1990s, cyclophosphamide was replaced by ifosfamide (VA-IA). The treatment was started with Cht in orbital and head and neck tumours and in the majority of genitourinary tumours, but surgery was first in paratesticular and in the majority of extremity tumours.

**Results.** The 3 patients with stage IV disease died. Of those with localised tumour, 34 (70%) were alive and well 5 years after treatment, 80% stage I, 75% stage II and 61% stage III. One patient died of heart failure, 3 of Cht toxicity and 1 of intercurrent disease.

**Conclusions.** The survival of our patients has improved during the last 2 decades and increased from 57 % to 70 % for patients treated after 1985. It is now comparable to that in other centres. With the introduction of neoadjuvant Cht, surgery and RT have become more conservative and could sometimes even be abandoned, thereby reducing considerably the risk of late sequels. Orbital, genitourinary and paratesticular embryonal RMS of low stages have very good prognosis. Primary tumours of the extremities and head & neck, mainly of alveolar type, have poor prognosis. For alveolar type of RMS and stage IV tumours, the present treatment modalities, including ABMT, are not effective.

*Key words:* rhabdomyosarcoma – therapy, child, survival analysis

---

## Introduction

When treating a child with a malignant tumour we try to achieve a cure with minimal risk for early, as well as late toxic effects of treatment.<sup>1</sup> This aim is easier to reach in early stages of the disease. The cure rate has significantly improved in the last decades with the introduction of multidrug chemotherapy (Cht). This is now used practically in all solid malignant tumours in children.<sup>2,3</sup> With the introduction of neoadjuvant Cht, surgery and radiation therapy have acquired more the role of adjuvant treatment may be more conservative and even be omitted in some cases after a complete response to Cht. The advantages are twofold: the response of the tumour can be evaluated in each particular patient, but not only statistically. Therefore, it can continue and be successful also after surgery. Moreover, Cht can be sufficient as the only treatment.<sup>4,5</sup> A morphological diagnosis to confirm malignancy is required before treatment as well as for the choice of proper Cht.<sup>6</sup> The aim of this study was to review the children with rhabdomyosarcoma (RMS), treated at the Hemato-oncological unit of the University Children's Hospital and at the Institute of Oncology in Ljubljana during a 23-year period.

## Patients and method

Between 1974 and 1996, 51 children aged from 1 to 15 years (median 6) and registered at the Cancer Registry of Slovenia with the diagnosis of RMS, were managed by a team of physicians at the Hemato-oncological unit of the University Children's Hospital and the Institute of Oncology in Ljubljana. Five children with RMS, who were first treated and/or followed outside Slovenia, are not included. Evaluation of the tumour extent included clinical examination, plain radiography computed tomography (CT), magnetic resonance

imaging (MRI), ultrasound, technetium bone scan, bone marrow biopsy, spinal tap in patients with parameningeal disease and those with stage IV tumours. The tumours were staged according to the SIOP-UICC<sup>7</sup> as follows:

Stage I: Tumour restricted to the organ of origin	12
Stage II: Tumour invasion beyond the organ of origin	10
Stage III: Tumour with regional metastases	26
Stage IV: Tumour with distant metastases.	3

The following primary sites were defined:

Head & Neck	15
Parameningeal	8
pterigopalatal fossa	1
nasopharynx	3
maxilla	4
face	5
ear lobe	1
oral cavity	1
Orbit	6
Genitourinary	12
vagina	4
prostate	1
(para)vesicular	7
Paratesticular	4
Extremity	9
lower	5
upper	4
Torso	5

There were 27 boys and 24 girls less than 16 years old at diagnosis (mean 6.9, SD 4.2). The diagnosis was provided by fine needle aspiration biopsy (FNAB) in 20 and by surgical biopsy in 31 patients prior to treatment. Of 43 histologically confirmed RMS, 25 were embryonal, 13 alveolar, 1 botryoid, 1 spindle cell and 3 sarcoma NOS. Multidrug chemotherapy varied. Vincristine, actinomycin D and cyclophosphamide (VAC) were used in the 1970s, VAC in combination with adriablas-

**Table 1.** Chemotherapy according to stage (51 patients)

CHT/ Stage	VAC	T2, VACA & VAIA	T6, T9 & T11	NP*
I	2	6	3	2
II	3	5	1	/
III	2	10	14	/
IV	/	/	/	3(ABMT)
Total	7	21	18	5

\*CIVADIC

tine (T2 -protocol, VACA) and methotrexate (T6 or T11-protocols) in the 1980s. VACA or VAIA (cyclophosphamide replaced by ifosfamide) were used in the 1990s (Table 1).

All 51 patients received Cht; 29 neoadjuvant, 20 had surgery first, in 40, Cht was combined with irradiation (RT). Of the 3 stage IV patients, 2 had bone marrow transplant (ABMT) at first treatment and one had half body RT in combination with Cht (VAIA alternating with VP 16 and cisplatinum) and RT to all involved areas.

The treatment was started with Cht in orbital and head and neck and in the majority of genitourinary tumours, whereas surgery was the first treatment in paratesticular and in the majority of extremity tumours. Twenty-one patients had no surgery (2 stage I, 1 stage II, 15 stage III and the 3 stage IV patients). Surgery was delayed in 10 patients (5 genitourinary, 1 orbital recurrence, one extremity and one torso) (Table 2).

Forty patients received RT to primary or metastatic site (including the 2 who had ABMT). In 2 patients with maxillary primary tumours, RT was given at first treatment, while in 24 patients, after Cht and in 16 also after surgery. The doses of RT varied between 30 Gy and 50 Gy, depending on tumour stage and response to Cht as well as on the experience of an earlier study.<sup>8</sup> Two patients received 60 Gy.

The patients were followed between 5 and 26 years (median 12) from the diagnosis. None were lost from the follow-up. The survival was calculated from the date of the diagnosis until December 31st 2000, when the study was concluded, or until the date of death. It was presented in survival curves according to the Kaplan-Meier method.<sup>9</sup> The statistical significance was calculated using the log rank test.

## Results

Sixty-seven % of all patients included in the study and 70 % of those with locoregional disease were alive and well more than 5 years from diagnosis. The survival of patients treated before 1985 was 57 % (12/21) and 70 % (21/30) of those treated after 1985. Of the 17 patients who died, 13 died of tumour, 4 of complications and one, 18 years after diagnosis, of an intercurrent disease without tumour. Toxicity due to Cht was the cause of death in

**Table 2.** Treatment according to primary site (48 patients, stage IV excluded)

Site	Chemotherapy			Surgery			RT*
	total	1th	2nd	total	1th	later	total
Orbit	6	5	1	2	1	1	6
Head& Neck	13	5	8	6	6	/	13
Genitourinary	12	7	5	10	5	5	8
Extremity	7	4	3	6	3	3	6
Torso	6	5	1	2	1	1	4
Paratestis	4	/	4	4	4	/	/
Total	48	26	22	30	20	10	37

\*radiotherapy

2 patients treated for recurrence and in one stage IV patient. Cardiotoxicity was the cause of death in one patient with stage III alveolar RMS of the anterior thoracic wall 8 years after completed treatment. At the time of death, a recurrence was also present. She was 3 years old at diagnosis. She was treated by Cht according to T2 protocol, including adriablastine and concomitant RT to the thoracic wall (4500 Gy given in split courses during 3 months).

The survival of the patients with stage I and stage II was very good, while it was significantly worse for the patients with stage III and stage IV (Figure 1). None of the stage IV patients survived, all had multiple bone metastases. All patients with orbital tumours and those with paratesticular tumours survived. Of the 12 patients with genitourinary tumours, one with primary tumour of the prostate died. Patients with primary tumours of the head and neck, torso and extremities did poorly. The patients with paratesticular, orbital and genitourinary primary tumours did significantly better than those with tumours of other primary sites (Figure 2). The survival was not different in those patients in whom treatment was started with Cht com-

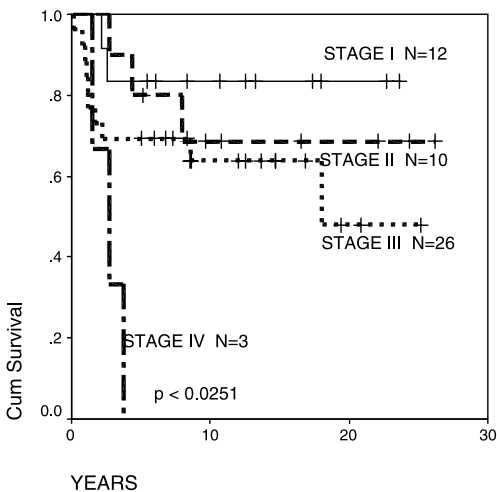
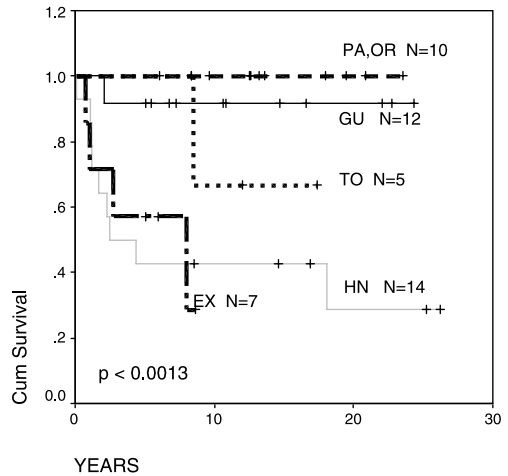


Figure 1. Disease free survival by stage in 51 patients.



PA = paratesticular, OR = orbit, GU = genitourinary, TO = torso, EX = extremity

Figure 2. Disease free survival by tumor site in 48 patients

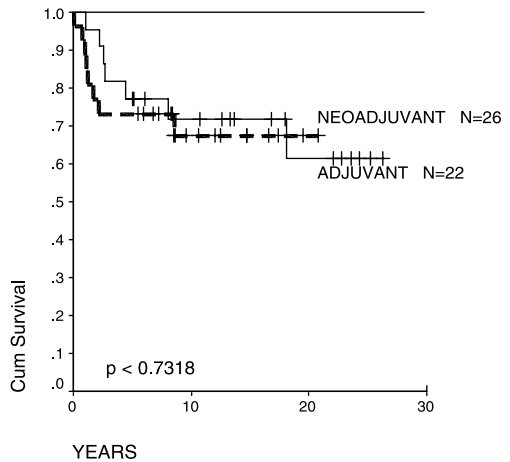
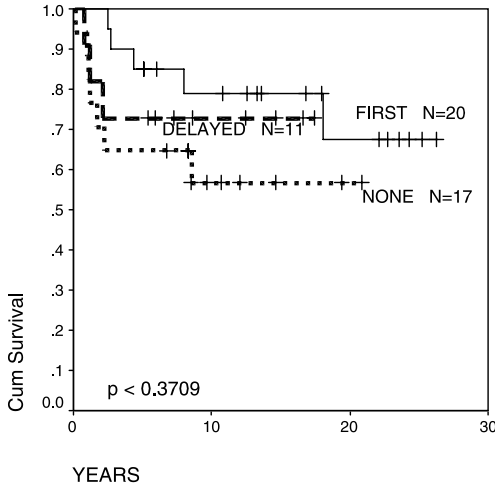
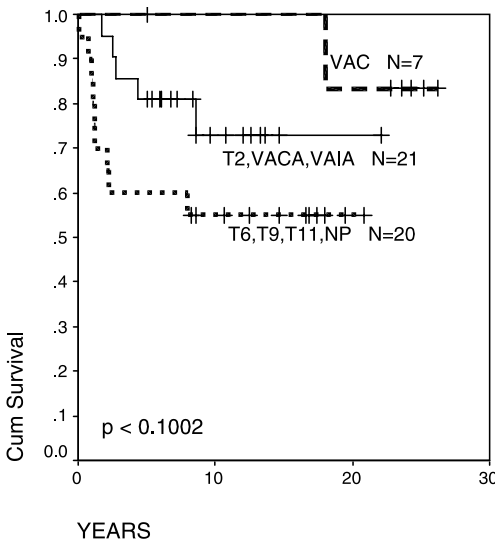


Figure 3. Difference in disease free survival between patients with adjuvant and neoadjuvant chemotherapy (48 patients)

pared to those who received Cht postoperatively (Figure 3). Furthermore, there was no difference in survival between those who had no surgery, delayed surgery or surgery as first treatment (Figure 4). The outcome of the disease in patients who had more intensive Cht



**Figure 4.** Disease free survival by surgery in 48 patients



**Figure 5.** Disease free survival by type of chemotherapy in 48 patients.

was not better compared to those who had VAC (Figure 5). The morphological type of RMS did not significantly influence survival (Figure 6). There were two late deaths after recurrence, both in patients with alveolar type of RMS.

## Discussion

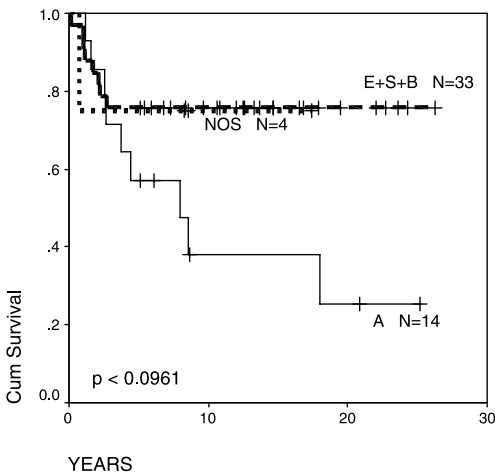
In our series of patients with RMS the distribution of sex, age and primary sites is similar to that of other reported studies. The same is true for the overall 5-year survival, which has improved in Slovenia during the last two decades from 57 % to 70 %.<sup>10,11</sup> The stage of the disease and the site of the primary tumour significantly influence the outcome, as known. Recently, a staging classification, based on the experience of the IRS group, was proposed, with some low stage tumours classified as unfavourable and some tumours of higher stages with expected favourable outcome.<sup>12</sup> In our experience, this has not been entirely confirmed. Patients with primary parameningeal tumours, classified as unfavourable, regardless of the stage, do extremely poorly (only one of the 8 survived) as also reported by others. All 7 patients with vesicular and paravesicular primary tumours, however, are among survivors (Table 3). Only 2 of them had tumours with less than 5 cm in diameter, all embryonal RMS. All patients with genitourinary primary tumours, except one with a primary tumour of prostate, survived.

The influence of tumour morphology on survival could not be statistically confirmed in our small series; however, it was noted that the patients with the alveolar type of tumour did poorly (Figure 6). This finding is consistent with other reports.<sup>13,14</sup> Fourteen patients had alveolar RMS, including 3 stage IV patients and only 5 out of the remaining 11 with locoregional disease are among survivors. Of the 6 who died, 5 had local recurrence (one died of cardiotoxicity with the tumour still present). They died 3, 4, 6 and 8 years after diagnosis. The results of the IRS studies II and III differ regarding the influence of tumour morphology on survival. It has therefore been suggested that the primary site, correlated to the histological type, is the prevailing and independent prognostic fac-

**Table 3.** Patients with primary tumours of the bladder or tumours invading the bladder

Pt I	Sex	Age in years	Year of diagnosis	Prim. site	Stage	Type	Surgery	RT	Cht	Late effects
I.P.	M	5	1976	paravesicular	T2 N1 M0	S	TR	48Gy	VAC	elevated FSH, soft tissue atrophy, recurrent cystitis
M.P.	M	2	1978	bladder	T1N0M0	E	Cystectomy	none	VAC	stoma, recurrent uroinfections
K.Ž.	F	5	1984	paravesicular	T2N0M0	E	STR	46	T11	soft tissue atrophy, amenorrhoe
M.J.	F	1.5	1990	paravesicular	T2N0M0	E	STR	none	T2	none
R.U.	M	7	1993	paravesicular	T2N0M0	E	STR	30*	VACA	none
B.K.	M	2	1994	bladder	T2N0M0	E	none	37.5	VACA	none
A.M.	F	2	1995	bladder	T1N0M0	E	TUR	39**	VACA	none

\*Hyperfractionation, \*\*Transperineal implant, Ir 192, TR = Total resection with partial cystectomy, TUR Transurethral resection, STR Subtotal resection, S = spindle cell RMS, E = embryonal RMS, FSH = follicle stimulating hormone



**Figure 6.** Disease free survival by morphological type in 51 patients. (A = Alveolar, E = Embryonal, B = Botryoid, S = spindle cell, NOS= RMS not otherwise specified)

tor.<sup>15</sup> It might also be possible that the morphology of the tumour did not influence the outcome significantly because the patients with alveolar tumours received more intensive Cht. In our series, the primary site and the type of the tumour were correlated (Table 4). All tumours of the extremities were of the

**Table 4.** Primary site versus morphological type

Primary site	Alveolar	Embryonal and other
Orbit	1	5
Head & neck	6	9
Genitourinary	0	16
Paratestis	0	4
Extremity	5	0
Torso	2	3
Total	14	37

alveolar type and all genitourinary and paratesticular tumours were of nonalveolar type.

The survival of patients in our study was not influenced by different schedules of Cht (Figure 5), which was probably too aggressive for some groups of patients. At least 3-drug combinations were used, often 4 or even more. ABMT has not been reported as successful in patients with RMS,<sup>16</sup> which was also true in our 3 stage IV patients who all had bone metastases.

The group of patients with bladder and paravesicular tumours, presented in Table 3, reflects the development of treatment approaches during the two decades, for the entire series. Radical surgery and high dose RT

were applied in the 1970s and very aggressive and Cht with more conservative surgery and lower doses of RT in the 1980s. Later, surgery and RT were more conservative, while 4-drug Cht was still used. With equal results in terms of survival, the consequences of treatment are considerably reduced.

The survival curves for those patients who were first treated with surgery and those who had neoadjuvant Cht and delayed, more conservative surgery are identical (Figure 6). The patients who had no surgery at all did not do significantly worse, even with the inclusion of the patients with high-risk parameningeal tumours.

### Conclusions

During the period under investigation, the methods of treatment of children with RMS have evolved. With the introduction of neoadjuvant Cht, surgery and RT have become more conservative or were even abandoned, thereby reducing the risk of late sequelae. The survival of our children with RMS has improved during the period under investigation and is now comparable to that in other centers. Orbital, genitourinary and paratesticular embryonal RMS of low stages have very good prognosis and may be cured with conservative treatment and less toxic chemotherapy. Primary tumours of the extremities and head and neck, mainly of alveolar type, have poor prognosis with present treatment modalities. Hopefully, new Cht schedules, will prove more effective. For alveolar type of RMS and stage IV tumours the present treatment modalities, including ABMT, are not effective; therefore, new approaches should be considered.<sup>17</sup>

### References

1. Tefft M, Lattin PB, Jereb B, Cham W, Ghavimi G, Rosen G, et al. Acute and late effects on normal tissues following combined chemo- and radiotherapy for childhood rhabdomyosarcoma and Ewing's sarcoma. *Cancer* 1976; **37**: 1201-13.
2. Taub JW. Factors in improved survival from paediatric cancer. *Drugs* 1998; **56**: 757-65.
3. Donaldson SS, Anderson J. Factors that influence treatment decisions in childhood rhabdomyosarcoma. Intergroup Rhabdomyosarcoma Study Group of the Children's Cancer Group, the Pediatric Oncology Group, and the Intergroup Rhabdomyosarcoma Study Group Statistical Center. *Radiology* 1997; **203**: 17-22.
4. Oberlin O, Rey A, Anderson J, Carli M, Raney RB, Treuner J, et al. Treatment of orbital rhabdomyosarcoma: Survival and effects of treatment – Results of an international workshop. *J Clin Oncol* 2001; **19**: 197-204.
5. Hays DM. Bladder/Prostate Rhabdomyosarcoma: Results of the multi-institutional trials of the Intergroup Rhabdomyosarcoma Study. *Sem Surg Oncol* 1993; **9**: 520-3.
6. Sommelet D, Pinkerton R, Brunat-Mentigny M, Farsi F, Martel I, Philip T, et al. Standards, options and recommendations (SOR) for clinical care of rhabdomyosarcoma (RMS) and other soft tissue sarcoma in children [Article in French]. *Bull Cancer* 1998; **85**: 1015-42.
7. Rodary C, Flamant F, Donaldson SS. An attempt to use a common staging system in rhabdomyosarcoma: A report of an international workshop initiated by the International Society of Pediatric Oncology (SIOP). *Med Pediatr Oncol* 1989; **17**: 210-5.
8. Jereb B, Ghavimi F, Exelby P, Zang E. Local control of embryonal rhabdomyosarcoma in children by radiation therapy when combined with chemotherapy. *Int J Rad Oncol Biol Phys* 1980; **6**: 827-33.
9. Kaplan EL, Meier P. Nonparametric estimation from incomplete observations. *J Am Stat Assoc* 1958; **53**: 457-81.
10. Dagher R, Helman L. Rhabdomyosarcoma: an Overview. *Oncologist* 1999; **4**: 34-44.
11. Crist W, Gehan EA, Ragab AH, Dickman PS, Donaldson SS, Fryer C, et al. The Third Intergroup Rhabdomyosarcoma Study. *J Clin Oncol* 1995; **13**: 610-30.

12. Baker KS, Anderson JR, Link MP, Grier HE, Qualman SJ, Maurer HM, et al. Benefit of intensified therapy for patients with local or regional embryonal rhabdomyosarcoma: Results from the Intergroup Rhabdomyosarcoma Study IV. *J Clin Oncol* 2000; **18**: 2427-34.
13. Pappo AS, Anderson JR, Crist WM, Wharam MD, Breitfeld PP, Hawkins D, et al. Survival after relapse in children and adolescents with rhabdomyosarcoma: A report from the Intergroup Rhabdomyosarcoma Study Group. *J Clin Oncol* 1999; **17**: 3487-93.
14. Wolden SL, Anderson JR, Crist WM, Breneman JC, Wharam MD Jr, Wiener ES, et al. Indications for radiotherapy and chemotherapy after complete resection in rhabdomyosarcoma: A report from the Intergroup Rhabdomyosarcoma Studies I to III. *J Clin Oncol* 1999; **17**: 3468-75.
15. Kodet R, Newton WA Jr, Hamoudi AB, Asmar L, Wharam MD, Maurer HM. Orbital rhabdomyosarcomas and related tumors in childhood: relationship of morphology to prognosis—an Intergroup Rhabdomyosarcoma Study. *Med Pediatr Oncol* 1997; **29**: 51-60.
16. Boulad F, Kernan NA, LaQuaglia MP, Heller G, Lindsley KL, Rosenfield NS, et al. High dose induction chemotherapy followed by Co autologous bone marrow transplantation as consolidation therapy in rhabdomyosarcoma extra-osseous Ewing's sarcoma, and undifferentiated sarcoma. *J Clin Oncol* 1998; **16**: 1697-706.
17. Pappo AS, Lyden E, Breneman J, Wiener E, Teot L, Meza J, et al. Up-front window trial of topotecan in previously untreated children and adolescents with metastatic rhabdomyosarcoma: An Intergroup Rhabdomyosarcoma Study. *J Clin Oncol* 2001; **19**: 213-9.