

MRI macromolecular contrast agents as indicators of changed tumor blood flow

Teodora Ivanuša¹, Katarina Beravs², Maja Čemažar³, Vladimir Jevtič⁴,
Franci Demšar¹, and Gregor Serša³

² "Jozef Stefan" Institute Ljubljana, ¹ Veterinary Faculty, University of Ljubljana,
³ Institute of Oncology Ljubljana, ⁴ Medical Center Ljubljana, Slovenia

Background. A rapid mapping technique derived from dynamic contrast enhanced MRI data was used to identify and characterize reduction of blood flow in fibrosarcoma SA-1 tumors treated either by application of electric pulses or vinblastine.

Materials and methods. Tissue permeability surface area product (PS) and fractional blood volume (BV) were calculated on a pixel-by-pixel basis using dynamic MRI intensity data after administration of gadomer-17 or polylysine-Gd-DTPA; prototypic macromolecular contrast agents designed for blood pool enhancement. PS and BV values of untreated tumors were compared to those of tumors treated by local application of 8 electric pulses (amplitude/distance ratio, 1300 V/cm; duration, 100 μ s, frequency, 1 Hz) percutaneously to the tumor or by systemic administration of vinblastine (2.5 mg/kg).

Results. Both treatments transiently, but significantly reduced tumor blood flow, application of electric pulses to the tumors being by 40% more effective in reducing tumor blood flow than systemic administration of vinblastine. PS and BV values derived with polylysine-Gd-DTPA-enhanced MRI were lower compared to those with gadomer-17, due to larger molecular size. Interestingly, Gd-DTPA-enhanced MRI did not show any significant changes of PS and BV between untreated and treated tumors.

Conclusion. This study demonstrates that dynamic contrast enhanced MRI can be effectively used to qualitatively monitor tumor blood flow, and quantitatively by means of BV and PS.

Key words: sarcoma experimental - therapy - blood supply; vinblastine; electroporation; magnetic resonance imaging; contrast media; macromolecular systems

Received 3 May 2001

Accepted 5 June 2001

Correspondence to: Katarina Beravs, Ph.D., "Jozef Stefan" Institute, Jamova 39, SI-1000 Ljubljana, Slovenia.
Phone: +386 31 313 806; Fax: +386 1 251 93 85; E-mail: Katarina.Beravs@ijs.si

Introduction

Tumors are physiologically different compared to normal tissues. Tumors are usually poorly perfused, have low oxygen tension and lower pH, due to chaotic vascularization. If the blood flow is chronically impaired, a cascade of tumor cell death occurs due to the lack of nutrients and accumulation of catabolic products. Therefore, the knowledge of tumor physiology is important for understanding of tumor growth.¹

Knowledge about tumor perfusion and its consequences on tumor cells' oxygenation is also important for planning of different treatments.² Radiation therapy requires good tumor oxygenation; adequate tumor perfusion is also important for successful delivery of chemotherapeutic drugs to tumor cells. Many anticancer agents and therapies in current use have been shown to have tumor blood modifying effect, and exert their antitumor action also by compromising tumor vascular function.³

In order to measure tumor blood flow several techniques have been developed.² One of imaging techniques that have already significantly contributed to better tumor visualization is magnetic resonance imaging (MRI). The use of contrast-enhancing agents in conjunction with MRI provides an opportunity to non-invasively extract physiological information, in addition to anatomical data offered by unenhanced images.² Contrast agents that are being developed nowadays are designed to define the physiology and pathophysiology in various tissues. In general, they can be divided into two groups: low-molecular-weight contrast agents and macromolecular contrast agents. Low-molecular-weight contrast agents, represented in one study by Gd-DTPA, have proved to be clinically useful in detecting abnormalities in blood-brain barrier.⁴ Unfortunately their performance is limited by rapid clearance from the blood into the extra-vascular compartment.⁵ Macromolecu-

lar contrast agents are being developed to investigate blood pool, to specifically enhance the blood pool and evaluate capillary integrity.^{6,7} Multiple applications of these contrast agents have been tested, including assessment of relative tissue blood volume and abnormal capillary permeability.^{8,9}

The aim of this study was to demonstrate the potential of dynamic contrast tissue-enhanced MRI to evaluate changes in tumor perfusion by calculating permeability surface area product (PS) and fractional blood volume (BV) on a pixel-by-pixel basis.^{10,11} We hypothesized that estimates of permeability and blood volume based on dynamic contrast tissue-enhanced MRI data should reliably describe the changes in tumor blood flow. For this purpose two tumor blood flow modifying approaches were used, a chemical agent given systemically, and a physical approach applied locally. Vinblastine is a chemotherapeutic agent, used in treatment of cancer. Besides direct effect on tumor cells, it also has tumor blood flow modifying effect, inducing profound, but transient reduction in tumor blood flow.^{12,13} Local application of electric pulses to the tumors also induces transient, but even greater reduction in tumor blood flow compared to vinblastin.^{14,15} Furthermore, macromolecular agents gadomer-17 and the new polylysine-Gd-DTPA were used to more accurately quantify the reduction of tumor blood flow due to their specific enhancement of tumor blood pool in contrast to Gd-DTPA, that readily diffuses across endothelium of normal and neoplastic microvessels.

Materials and methods

Animals and tumors

An inbred strain of A/J mice was used. They were maintained at a constant room temperature (22°C) with natural day and night light cycle in conventional animal colony. Before the experiment, the mice were subjected to

an adaptation period of at least 10 days. Mice in good condition, without fungal or other infections, and 10-20 weeks of age were included in experiment. Fibrosarcoma SA-1 tumor (The Jackson Laboratory, Bar Harbor, ME) syngeneic to A/J mice was used as a tumor model. Tumor cells were obtained from the ascitic form of the tumors in mice serially transplanted every 7 days. Solid subcutaneous tumors located dorsolaterally were induced by an injection of 5×10^5 SA-1 cells in 0.1 ml of 0.9% NaCl solution. The viability of the cells was over 95% as determined by trypan blue dye exclusion test. Tumors were imaged 6-8 days after implantation (app. 7 mm diameter).

Treatment of tumors

Eight square-wave electric pulses, divided in two sets of 4 pulses in opposing directions, of 1040 V amplitude (amplitude/distance ratio 1300 V/cm), with pulse width of 100 μ s and repetition frequency 1 Hz were delivered by two flat, parallel stainless-steel electrodes 8 mm apart (two stainless-steel strips: length 15 mm, width 7 mm with rounded corners), which were placed percutaneously at the opposite margins of the tumor. Good contact between the electrodes and the skin was assured by the means of a conductive gel. Electric pulses were generated by an electroporator Jouan GHT 1287 (Saint Herblaine, France). Treatment was performed without anesthesia and was well tolerated. Vinblastine (Lilly France S.A., Fegersheim, France) was administered intraperitoneally in a dose of 2.5 mg/kg. Thereafter, animals were anesthetized with a mixture of Domitor (1.0 mg/kg body weight) (Pfizer GmbH, Karlsruhe, Germany) and 10% ketamine (75.0 mg/kg body weight) (Veyx-Pharma GmbH, Schwartzenborn, Germany) administered intraperitoneally. During anesthesia, body temperature was kept at physiological values. Both treatments were applied 5-10 min prior to imaging.

MRI

MRI was performed on a 2.35 T Bruker Biospec system with horizontal bore magnet. First, a pre-contrast image (complete k-space data set) was acquired using standard spin-echo technique with the following imaging parameters: $T_R = 600$ ms, $T_E = 18$ ms, matrix 256×256 , slice 2 mm, field of view 7 cm and acquisition time 5 min. Subsequently, contrast agent was administered, and a small, central data subset of the k-domain (in the phase-encoding direction) with dimensions 32×256 k-space data points was acquired repetitively for 60-100 min (80-100 "key" images). Each "key" image was acquired with 32 phase encoding steps that took 38 s. Before the reconstruction, dynamically acquired data subset was first completed in remaining k-space points (which were not included in temporal acquisition) with the data from the first acquisition. This was followed by the dynamical image reconstruction with 2D inverse Fourier transformation.

MR contrast agent

Clinically available Gd-DTPA (Magnevist[®], Schering AG, Berlin, Germany) was used as a small-molecular-size contrast agent, administered to a subgroup of 5 animals, in a dose of 0.1 mmol Gd/kg. Gadomer-17 (Schering AG, Berlin, Germany) was used as an intermediate molecular size contrast agent, but still macromolecular compared to Gd-DTPA. The size of the agent is approximately 30 kDa, allowing its complete renal elimination. Gadomer-17 was administered to a second sub-group of 5 animals. The new polylysine-Gd-DTPA (Schering AG, Berlin, Germany) was used as a representative macromolecular contrast agent (≈ 50 kDa). Similarly, polylysine-Gd-DTPA was administered to a third subgroup of 5 animals. Both macromolecular agents were administered in a dose of 0.025 mmol/kg and were well tolerated. Because of the increased relaxation potency

of gadolinium in the macromolecule compared to that in the small-molecular contrast agent, this lower dose gives approximately equal initial blood enhancement. All three contrast agents were administered in a bolus via 23-gauge intravenous cannula (Vygon 247 Venoflux infusion set, France) that was inserted into a tail vein.

Postprocessing

Magnetic resonance signal was measured in a region of interest (tumor) in precontrast images and at least 80 postcontrast images at each timepoint. Signal was corrected for signal variations against water phantom. From the measured signal, tissue contrast agent concentration (C_T) was calculated with a subtraction of precontrast signal from postcontrast signals on a pixel-by-pixel basis. Contrast agent concentration in a slowly flowing vessel (C_B), such as inferior vena cava was obtained in a similar way, only within the inferior vena cava. The linearity of the C_T / C_B fit was checked for the first 30-50 points. Statistical analysis using a paired t-test was applied to compare values and significance concluded if $P < 0.01$.

Data analysis

Fractional blood volume BV and permeability surface area product PS were calculated using the method described previously.^{8,16-18} Briefly, BV is estimated as a ratio of tissue signal intensity C_T at time t divided by signal intensity for blood C_B in slowly flowing vessels such as the inferior vena cava. On a pixel-by-pixel basis, BV was calculated as:

$$BV \approx \frac{C_T(t)}{C_B(t)} - PS' \quad [1]$$

where C_T is tissue contrast agent concentration, C_B blood contrast agent concentration and PS' :

$$PS' \approx \frac{\left[\frac{C_T(t_2)}{C_B(t_2)} - \frac{C_T(t_1)}{C_B(t_1)} \right]}{t_2 - t_1} \quad [2]$$

For the vascular permeability, a two-compartment, one directional flow model was adopted for the movement of the macromolecular contrast agent from the blood to the interstitial space.¹⁷ PS was calculated using equation:

$$PS = PS'(1-Hct) \quad [3]$$

where Hct is the measured hematocrit of the blood (47% for tumor in animals).

Results

Qualitative MRI data in Figure 1 showed that untreated tumors enhanced heterogeneously with contrast agents used; highly vascular rim enhancing more than the partly vascular, partly necrotic tumor center. Enhancement with Gd-DTPA was prompt and included the whole tumor, but tended to decline after the first minute, due to rapid transendothelial diffusion and rapid renal elimination (Fig. 1a; left column). Prompt and marked enhancement of the highly vascularized tumor rim was also observed with polylysine-Gd-DTPA and was less pronounced with gadomer-17 (Fig. 1 b, c; left column). The enhancement of subcutaneously implanted tumors increased gradually with both macromolecular agents, reflecting diffusion from blood into the interstitial space. Tumors treated with vinblastine or application of electric pulses showed little or no enhancement of the tumor within the first hour after the treatment, due to reduced blood flow (Fig. 1, middle and right column). Afterwards, enhancement started to increase since the reduction in tumor blood flow was transient. Enhancement with Gd-DTPA was not significantly affected by both treatments.

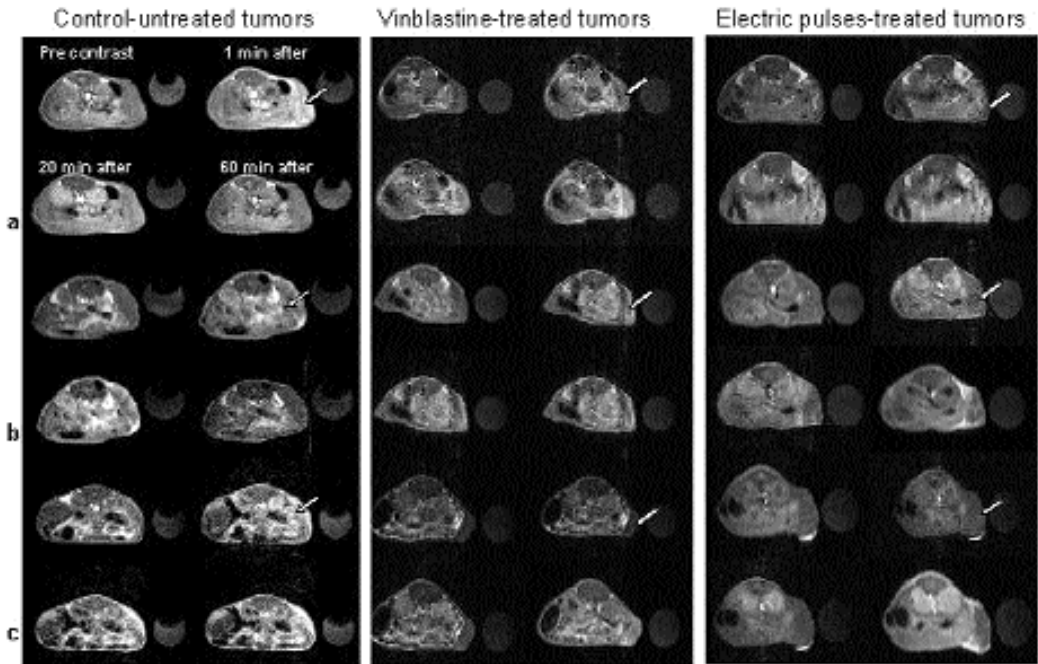


Figure 1. Representative dynamic images of tumors in untreated animals, and those treated with vinblastine or application of electric pulses. Clusters of four images depict each combination of tumor and contrast agent; images in each cluster are arranged as: pre-contrast, 1 min, 20 min and 60 min post-contrast. (A) Cluster was obtained with Gd-DTPA, (B) with gadomer-17 and (C) with polylysine-Gd-DTPA. Note the difference in contrast agent accumulation between untreated and treated tumors and between contrast agents themselves (arrows).

The time course of gadomer-17 and polylysine-Gd-DTPA accumulation (described as C_T) in the untreated tumors and tumors treated with vinblastine or application of electric pulses is shown in Figure 2. In untreated tumors, concentration of the gadomer-17 (C_T) increased gradually over the first 10 minutes indicating microvascular leak and accumulation of the agent in the interstitial space of the tumor and then started to decrease at 20 min due to the clearance (Fig. 2 a). The C_T data for polylysine-Gd-DTPA also increased substantially over the time, again indicating microvascular leak and longer accumulation of the agent in the interstitial space of the tumor, due to its large molecule (Fig. 2 b). After both treatments, vinblastine or application of electric pulses, tumor blood flow was reduced

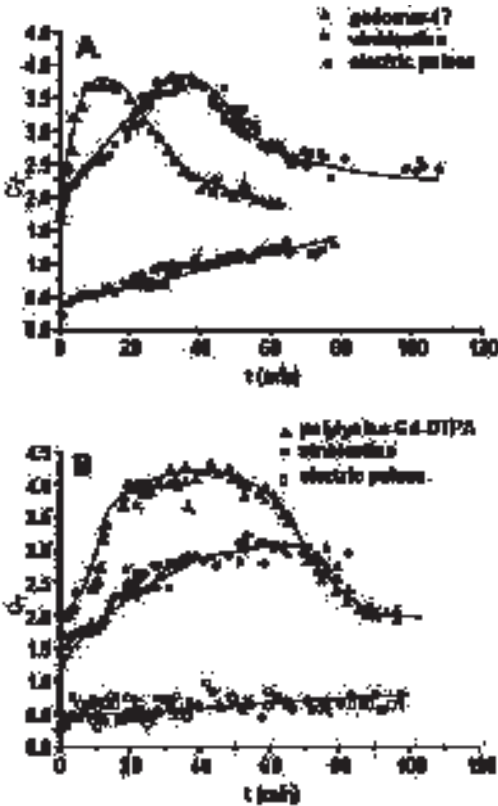
and consequently also contrast agents accumulation. The effect of vinblastine was less pronounced than that of application of electric pulses (Fig. 2)

High mean BV and PS values in untreated tumors, obtained with Gd-DTPA indicated rapid transendothelial equilibration (Table 1). Approximately equal mean BV and PS values that were obtained with gadomer-17 and polylysine-Gd-DTPA, but lower compared to Gd-DTPA, indicated slow diffusion of both agents from blood into the interstitial space due to larger molecular size. Large molecular size impairs passage through vascular endothelium compared to the small Gd-DTPA, inspite of the intercellular gaps. Within the first hour after the application of electric pulses, calculated BV and PS values from data obtai-

Table 1. Fractional blood volume BV and permeability surface area product PS values of untreated and tumors treated by vinblastine or application of electric pulses

	gadomer-17		polylysine-Gd-DTPA		Gd-DTPA	
	BV (%)	PS (μl/cc/h)	BV (%)	PS (μl/cc/h)	BV (%)	PS (μl/cc/h)
Untreated tumors	8.8 ± 1.3	680 ± 30.1	8.6 ± 1.1	510 ± 27.3	20 ± 2.3	4710 ± 45.8
Electric pulses	0.5 ± 0.03	72.3 ± 16.1	0.27 (0.06	58 (18.1	12.7*	4040*
Vinblastine	4.0 ± 1.13	359 ± 50.4	1.37 ± 0.22	231.4 ± 60.7	19.8*	4180*

* one data set only

**Figure 2.** Time course of (A) gadomer-17 and (B) polylysine-Gd-DTPA accumulation in untreated and vinblastine or electric pulses treated tumors.

ned with both macromolecular contrast agents dropped on average to 10% or less, compared to those of untreated tumors. After treatment with vinblastine, calculated BV and PS values of gadomer-17-enhanced MRI were

higher for approximately 65% and 35%, respectively, compared to BV and PS values of polylysine-Gd-DTPA-enhanced MRI.

Discussion

Results of this study demonstrate that dynamic contrast enhanced MRI can be effectively used to qualitatively monitor tumor blood flow, and quantitatively by means of BV and PS from the gadomer-17 and polylysine-Gd-DTPA enhanced MRI. In order to determine the value of contrast enhanced MRI, two approaches were used to reduce tumor blood flow, treatment with vinblastine and application of electric pulses to the tumors. Tumor blood flow in both cases rapidly decreased with a slow recovery. Relatively high BV and PS values of untreated tumors were due to microvascular abnormalities - vascular leakage in the tumor region. Both treatments also resulted in reduced BV and PS values, treatment with vinblastine was less effective in reducing tumor blood flow than application of electric pulses. The data support the evidence on tumor blood flow modifying effect of these two treatments, provided with other methods.¹²⁻¹⁵

Changes in endothelial cells of microvessels manifest as contraction of these cells, forming intercellular gaps, allowing intravascular fluids and macromolecular solutes to leak into the interstitial space.¹⁹ Gd-DTPA in general promptly enhances tumors.²⁰ Due to its

rapid equilibration between intra- and extravascular compartments, enhanced tumor vessels could not be distinguished. With macromolecular contrast agent such as gadomer-17 or polylysine-Gd-DTPA, transendothelial passages depend on the size of the molecule. Larger molecules stay within the vessel for a longer period of time, thus enabling differentiation of the tumor vessels from the extravascular compartments. This is shown on Figure 1, where highly vascularized tumor rim was enhanced for a longer period due to the large molecular size of polylysine-Gd-DTPA.

Tumor blood flow modifying effect of electric pulses has already been described. It was shown that application of electric pulses locally to the tumor reduces tumor blood flow transiently, returning to almost pretreatment value within 24 hours.^{14,15} The reduction in tumor blood flow was very quick, reaching 30% pretreatment value within 1 hour after application of the same set of pulses as used in this study. These data were obtained with rubidium extraction technique, a pharmacological technique measuring plasma flow through the tumor. Confirmed were the data by Patent blue staining technique, which also estimates tumor blood flow. Vinblastine also perturbs tumor blood flow.^{12,13} Studies demonstrated that with the same dose of vinblastine as used in this study, the onset of reduced tumor perfusion after vinblastine was fast, maximal reduction was observed by 1 hour after the treatment, thereafter tumors gradually started to reperfuse. Reperfusion was not completed by 48 hours. The data obtained in the present study on tumor blood flow modifying effect of electric pulses and vinblastine are in accordance with the data in the literature.¹²⁻¹⁵ After both treatments, blood flow was reduced and consequently also contrast agent accumulation. The effect of vinblastine was less pronounced than that of applied electric pulses; the degree and duration of tumor blood flow reduction was smaller. Since the reduction of blood flow with

vinblastine was not as severe as with electric pulses, the difference in gadomer-17- and polylysine-Gd-DTPA-enhancement was not as pronounced.

Besides gadomer-17- and polylysine-Gd-DTPA-enhanced MRI, Gd-DTPA was also used to evaluate tumor BV and PS in untreated and tumors treated with vinblastine or application of electric pulses. In the treated tumors, BV and PS values failed to highlight the reduction of tumor blood flow. This is also in accordance with literature data.^{20,21} The accuracy of the maps in tissues outside central nervous system is questionable because of the high and variable permeability of Gd-DTPA even in normal tissue.^{20,21}

Earlier reports have described the value of pixel-by-pixel mapping of parameters derived from MRI signal intensity data.^{8,20} Parameters mapped included T_1 , T_2 , proton density, diffusion coefficient²², oxygenation²³, temperature²⁴, magnetization transfer²⁵, chemical shift²⁶, susceptibility²⁷, electric current²⁸, blood flow²⁹, and contrast media.^{30,31} Our results are based on the use of macromolecular contrast agents, gadomer-17 and polylysine-Gd-DTPA respectively, that allow quantitative estimation of PS and BV. Small paramagnetic Gd-chelate distribution (Gd-DTPA) can only give qualitative impression.²¹ It's difficult to speculate, which macromolecular contrast would give better estimate of tumor blood flow reduction, however due to the complete renal clearance gadomer-17 might provide better basis for use in clinical practice.

In conclusion, dynamic contrast enhanced MRI showed qualitatively that application of electric pulses to the tumors and systemic treatment of animals with vinblastine induced reduction of tumor blood flow, and quantitatively by means of BV and PS calculations. From the enhancement curves as well as from the BV and PS values, the decrease in tumor blood flow was approximately 40% more pronounced with electric pulses compared to vinblastine. Dynamic contrast enhanced MRI

also showed that this reduction was transient, but did not completely return to the values of untreated tumors during the observation time. This approach could therefore be used for monitoring the time window and the extent of the tumor blood flow reduction in the tumor after tumor blood flow modifying therapies.

Acknowledgement

This work was supported by the Ministry of Education, Science and Sport of the Republic of Slovenia.

References

1. Brown JM, Giaccia AJ. The unique physiology of solid tumors: Opportunities (and problems) for cancer therapy. *Cancer Res* 1998; **58**: 1408-16.
2. Molls M, Vaupel P. *Blood perfusion and microenvironment of human tumors. Implications for clinical radiobiology*. Berlin, Heidelberg, New York: Springer; 2000.
3. Chaplin DJ, Hill SA, Bell KM, Tozer GH. Modification of tumor blood flow: Current status and future directions. *Semin Radiat Oncol* 1998; **8**: 151-63.
4. Brasch RC, Weinmann HJ, Wesbey GE. Contrast-enhanced NMR imaging: animal studies using gadolinium-DTPA complex. *Am J Roentgenol* 1984; **142**: 625-30.
5. Weinmann HJ, Laniado M, Mutzel W. Pharmacokinetics of Gd-DTPA/dimeglumine after intravenous injection into healthy volunteers. *Physiol Chem Phys Med NMR* 1984; **16**: 167-73.
6. Shames D, Kuwatsuru R, Vexler V, Muehler A, Brasch R. Measurement of capillary permeability to macromolecules by dynamic magnetic resonance imaging: a quantitative non-invasive technique. *Magn Reson Med* 1993; **29**: 616-22.
7. Kuwatsuru R, Shames D, Muhler A, Mintorovich J, Vexler V, Mann JS, Cohn F, Price D, Huberty J, Brasch RC. Quantification of tissue plasma volume in the rat by contrast-enhanced magnetic resonance imaging. *Magn Reson Med* 1993; **30**: 76-81.
8. Demšar F, Roberts TPL, Schwickert HC, Shames DM, van Dijke CF, Mann JS, Saeed M, Brasch RC. A MRI spatial mapping technique for microvascular permeability and tissue blood volume based on macromolecular contrast agent distribution. *Magn Reson Med* 1997; **37**: 236-42.
9. Gossmann A, Okuhata Y, Shames DM, Helbich TH, Roberts TPL, Wendland MF, Huber S, Brasch RC. Prostate cancer tumor grade differentiation with dynamic contrast-enhanced MR imaging in the rat: comparison of macromolecular contrast media-preliminary experience. *Radiol* 1999; **213**: 265-72.
10. Serša I, Medič J, Beravs K, Demšar F. Fast keyhole MR imaging using optimized k-space data acquisition. *Electro Magnetobiol* 1998; **17**: 307-21.
11. Medič J, Tomažič S, Serša I, Demšar F. Contrast and resolution considerations in keyhole MRI: application to dynamic studies of contrast media kinetics. *Electro Magnetobiol* 1998; **17**: 323-31.
12. Hill SA, Sampson LE, Chaplin DJ. Anti-vascular approaches to solid tumour therapy: evaluation of vinblastin. *Int J Cancer* 1995; **63**: 119-23.
13. Serša G, Kržič M, Šentjerc M, Ivanuša T, Beravs K, Čemažar M, Auersperg M, Swartz HM. Reduced tumor oxygenation by treatment with vinblastine. *Cancer Res* 2001; **61**: 4266-71.
14. Serša G, Čemažar M, Parkins CS, Chaplin DJ. Tumour blood flow changes induced by application of electric pulses. *Eur J Cancer* 1999; **35**: 672-7.
15. Serša G, Čemažar M, Miklavčič D, Chaplin DJ. Tumour blood flow modifying effect of electrochemotherapy with bleomycin. *Anticancer Res* 1999; **19**: 4017-22.
16. Larsson HB, Stubgaard M, Frederiksen JL, Jensen M, Hensriksen O, Paulson OB. Quantification of blood-brain barrier defect by magnetic resonance imaging and gadolinium-DTPA in patients with multiple sclerosis and brain tumors. *Magn Reson Med* 1990; **16**: 117-31.
17. Patlak C, Blasberg R, Fenstermacher J. Graphical evaluation of blood-to-brain transfer constants from multiple time uptake data. *J Cerebr Blood Flow Metab* 1983; **3**: 1-7.
18. Demšar F, Shames DM, Roberts TPL, Stiskal M, Roberts HC, Brasch RC. Kinetics of MRI contrast agents with size ranging between Gd-DTPA and albumin-Gd-DTPA: use of cascade-Gd-DTPA-25-polymer. *Electro Magnetobiol* 1998; **17**: 283-97.

19. Cotran PS, Kumar V, Robbins SL. Inflammation and repair. In: Robbins SL, Kumar V, eds. *Pathologic basis of diseases*. Vol. 2, 4th ed, Philadelphia: Saunders, 1989.
20. Raimo S, Young IR, Wesbey GM. Contrast-enhanced NMR imaging: animal studies using gadolinium-DTPA complex. *AJR* 1984; **142**: 625-30.
21. Su MY, Jao JC, Nalcioğlu O. Measurements of vascular volume fraction and blood tissue permeability constants with a pharmacokinetic model: studies of rat muscle tumors with dynamic Gd-DTPA enhancement MRI. *Magn Reson Med* 1994; **32**: 714-24.
22. Taylor DG, Bushell MC. Spatial mapping of translation diffusion coefficients by NMR technique. *Phys Med Biol* 1985; **30**: 345.
23. Lewa CJ, Majewski Z. Temperature relationship of proton spin-lattice relaxation time T1 in biological tissues. *Bull Cancer* 1980; **67**: 525.
24. Disckinson RJ, Hall AS, Hind AJ. Measurements of changes in tissue temperature using MR imaging. *J Comput Assited Tomogr* 1986; **10**: 468.
25. Vahlensieck M, Dombrowski F, Leutner C, Wagner U. Magnetization transfer contrast (MTC) and MTC-subtraction-enhancement of cartilage lesions and intracartilaginous degeneration in vitro. *Skeletal Radiol* 1994; **23**: 535-39.
26. Dixon WT. Simple proton spectroscopic imaging. *Radiology* 1984; **153**: 189.
27. Weisskoff RM, Kihne S. MRI susceptometry-image-based measurement of absolute susceptibility of MR contrast agents and human blood. *Magn Reson Med* 1992; **24**: 375-83.
28. Beravs K, Frangež R, Gerkis AN, Demšar F. Radio-Frequency current density imaging of kainate evoked depolarization. *Magn Reson Med* 1999; **42**: 136-40.
29. Dumoulin CL, Hart HR. Magnetic resonance angiography. *Radiology* 1986; **161**: 717.
30. Hanna SL, Reddick WE, Parham DM, Gronemeyer SA. Automated pixel-by-pixel mapping of dynamic contrast enhanced MR images for evaluation of osteosarcoma response to chemotherapy - preliminary results. *J Magn Reson* 1993; **3**: 849-53.
31. Kuwatsuru R, Liu T, Cohen F, Shames DM, Osorio RW, Mann J, Rosenau W, Muhler A, Neuder MS, Roberts JP, Brasch RC. Early detection of endothelial leak in a rat model using magnetic resonance imaging and a macromolecular contrast medium. *Invest Radiol* 1994; **29**: S297-S99.