

review

Magnetic resonance of cardiac tumors and masses

Pavel Berden

Clinical Institute of Radiology, University Medical Center, Ljubljana, Slovenia

Cardiac tumors are rare and should be differentiated from nontumoral cardiac masses because of different therapeutic approach. For this purpose, spin-echo (SE) technique and gradient-echo (GE) technique are used in magnetic resonance imaging (MR). The first provides anatomic evaluation of the heart and tissue characterization, while the second provides dynamic information on the blood flow and heart contraction. Cardiac myxoma is differentiated from thrombus by paramagnetic contrast agent administration. Their mobility is evaluated with GE technique. Lipomas and subacute hemorrhage have the same, high signal intensity on T1-weighted spin-echo image, therefore, the fat suppression technique is appropriate to recognize them. MR is used in evaluating the response of the malignant tumor to chemotherapy. GE MR is useful to differentiate between the thrombus and slow-flowing blood; the administration of gadolinium helps to distinguish the thrombus from the tumor. In patients suspected of having a cardiac tumor, echocardiography is the first method of choice. MR is used to confirm the findings of echocardiography, to determine precisely the tumor location, extent, and its tissue characterization, to follow up patients under treatment, and to detect early tumor recurrence.

Key words: heart neoplasms; magnetic resonance imaging

Introduction

Cardiac tumors are rather rare entities. Because of their rarity and the nonspecific symptomatology, their diagnosis may be delayed. Cardiac surgery is still the preferred therapeutic approach for cardiac tumors. Nontumoral cardiac masses are much more

frequent than true cardiac tumors and usually require medical treatment or no treatment at all.¹ Thus, accurate differentiation between the two conditions is highly important. The diagnosis of cardiac tumors and masses was very difficult before the availability of transthoracic (TTE) and transesophageal echocardiography (TEE), computed tomography (CT), and magnetic resonance imaging (MR). With the advent of modern imaging techniques abnormal masses are much more easily and frequently detected. As normal cardiac structures may be interpreted as abnormal by inexperienced people, precise knowledge of the normal cardiac anatomy and its variants

Received 15 May 2000

Accepted 30 May 2000

Correspondence to: Pavel Berden, M.D., Clinical Radiology Institute, University Medical Centre Ljubljana, Zaloška 7, SI-1525 Ljubljana. Phone: +386 1 5408 400; Fax: +386 1 133 31 044; E-mail: pavel.berden@mf.uni-lj.si

is required. We wish to highlight the role of MR in the detection and differentiation of cardiac masses to stress the diversity of cardiac tumors, nontumoral masses, and normal variants, and to present our experience with MR in evaluating cardiac masses.

MR techniques of imaging cardiac tumors and masses

MR is one of the preferred imaging modalities in the evaluation of the patients with suspected cardiac masses.

Two types of ECG-triggered sequences are used for the evaluation of suspected cardiac masses with MR. The first is the spin-echo (SE) technique (dark blood), the second is the gradient-echo (GE) technique (bright blood).

The SE sequence can be T1- or T2-weighted. It provides excellent anatomic evaluation of the heart. The differentiation between benign and malignant neoplasms based on the pattern of signal intensity is still not possible, although a combination of T1- and T2-weighted measurements allows better description of the composition of cardiac masses.

Most soft tissue tumors have relaxation times shorter than fluid, and produce a relatively low signal on T1-weighted images and a relatively high signal on T2-weighted images.² Cystic fluid (pericardial cyst) has a very low signal on T1-weighted images and a very high signal on T2-weighted images. The masses with lipomatous composition (lipomas) have a relatively high signal on T1-weighted sequences and an intermediate signal on T2-weighted sequences. Fat suppression techniques selectively saturate the signal coming from the fat and can be used to prove the fatty composition of cardiac masses. Calcifications and mature fibrotic tissue have few mobile protons, resulting in low signal in both T1- and T2-weighted MR, while subacute and chronic hemorrhage shows a high signal intensity in both sequences.³

Many tumors have similar signal intensity as normal myocardium and the distinction between them is difficult.⁴ Paramagnetic contrast agents, such as gadoliniumdiethylene triamine penta-acetic acid (Gd-DTPA), may be administered to improve discrimination. Gd-DTPA usually accumulates in the vascularized tissues or in tissues that contain higher proportion of interstitial space. Necrotic or cystic areas of a tumor do not accumulate contrast medium. This may help in the differential diagnosis or valuation of the efficacy of nonsurgical treatment on the follow-up. Acute and subacute thrombus does not have vascularization and therefore cannot be enhanced by Gd-DTPA, which may help to differentiate them from tumor. Chronic thrombi can rarely be enhanced after the administration of contrast medium.⁵

Gradient-echo MR is generally applied as a single-slice multiphase sequence. Images are obtained at different time points during the cardiac cycle in a single tomographic section. These images can be looked in a cine mode providing dynamic information on the blood flow and heart contraction (cine MR). It does not provide real-time imaging, but it is a very useful technique to evaluate the mobility of cardiac masses and to differentiate slow flow from thrombus.

Normal cardiac anatomy and variants

Several normal intracardiac structures can mimic pathologic masses.

False chordae or false tendons are sometimes found as normal variants in left ventricle. They are linear structures attached at both ends to the endomyocardium and are usually detected accidentally.

The moderator band is a thin muscular band extending from the midinterventricular septum and is attached to the free wall of the right ventricle near the base of the anterior papillary muscle. It may become very promi-

nent and may be mistaken for the right ventricular thrombus or tumor. It is unique for the right ventricle, which can be very helpful in differentiating the right from the left ventricle in congenital heart malformations.

Nodular thickening of the posterior right atrial wall corresponds to the *crista terminalis*. It is a prominent muscular ridge that extends along the posteriolateral wall of the right atrium between the orifices of the superior and inferior venae cavae. These structures have a similar signal intensity as myocardial tissue and should not be mistaken for neoplasm or thrombosis.

Primary cardiac tumors

Primary cardiac tumors of the heart and pericardium are extremely rare. They can be an incidental finding on chest radiography or cardiovascular diagnostic test. Clinical findings (flow disturbance, thromboembolism, arrhythmias, etc.) are determined primarily by the anatomic location of the tumor. Seventy-five percent of the primary tumors are benign. Nearly half the benign tumors are

myxomas and predominate in adults, whereas rhabdomyomas predominate in children.

Benign cardiac tumors

Cardiac myxoma (Figure 1) is an intracavitary neoplasm that can occur anywhere in the heart. Seventy-five percent of myxomas occur in the left atrium, and, usually, have a pedunculated attachment to the atrial septum near the fossa ovalis. Systemic embolism occurs in 20% to 25% of patients with myxomas.

The signal characteristics of myxomas on MR depend on the tumor composition. The areas of low signal intensity correspond with calcification (30% of myxomas) or deposition of hemosiderin; the areas of high signal correspond with subacute intratumoral hemorrhage.⁶ The surface of the tumor is often covered by thrombus. Myxomas are highly vascular showing significant enhancement after the administration of paramagnetic contrast agents (Gd-DTPA); the enhancement can be of a homogeneous or heterogeneous pattern. The areas of enhancement correspond with histologic tumor cells, while unenhanced regions reflect necrosis. Myxomas have a low

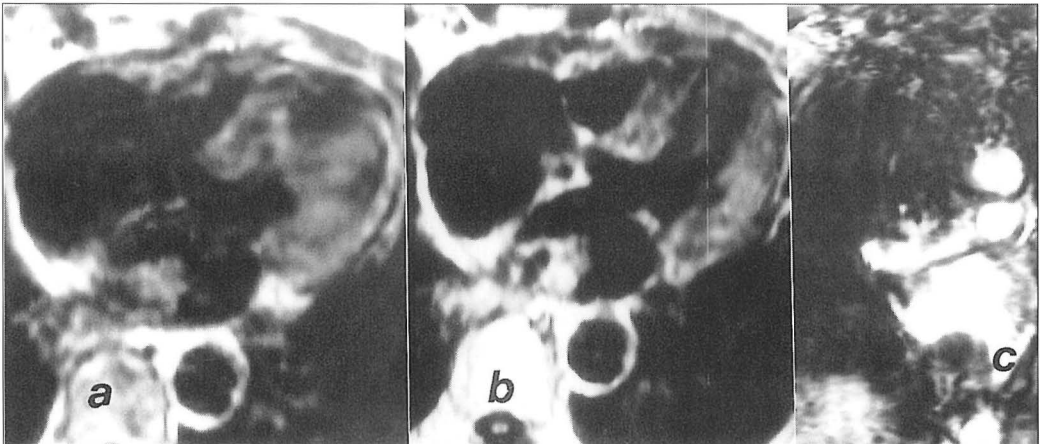


Figure 1. Left atrial myxoma. T1-weighted axial SE images before (a) and after (b) the administration of Gd-DTPA. There is a well-defined inhomogeneous mass in the left atrium attached to the posterior wall. The tumor demonstrates an inhomogeneous enhancement pattern after contrast administration with no enhancement in the medial part. This part has very low signal on the precontrast image, which corresponds with calcification. c Coronal GE image: the myxoma appears strongly hypointense, surrounded by the bright intracavitary blood.

signal intensity on cine MR; this technique may be used to detect atrioventricular tumor entrapment.

The differential diagnosis of myxoma includes other benign and malignant primary tumors, metastatic tumors, organized atrial thrombi, valvular vegetations and normal variants that may mimic cardiac masses.

Cardiac lipomas are benign tumors of encapsulated mature adipose cells and represent approximately 10% of all cardiac neoplasms. They can be intracavitary, intramyocardial, or intrapericardial, and are most frequently located in the left ventricle and right atrium. Lipomas are usually asymptomatic and in most cases require no treatment. MR shows the nature, size and location of the tumor. The differential diagnosis includes subacute hemorrhage because both entities have a high signal intensity on T1-weighted MR. Fat suppression techniques can differentiate fatty tissue from subacute hemorrhage. T2-weighted MR is useful, too, because lipomas have an intermediate signal intensity on T2, whereas subacute hemorrhage has a high signal intensity.

Rhabdomyoma represents 75% of all primary cardiac tumors in early childhood and may regress spontaneously by the age of 2 years. They are frequently multiple, involve both atria and ventricles, and can have an intracavitary location. Differential diagnosis includes fibromas, which are infrequently multiple or located in the atria. A most important differential feature is the association of rhabdomyomas with tuberous sclerosis. Cardiac rhabdomyomas have a median to high signal intensity on T1-weighted MR and an intermediate signal intensity on T2-weighted images. The postcontrast enhancement of the tumor is similar to the surrounding myocardium.⁷

Malignant cardiac tumors

Primary malignant cardiac tumors consist of sarcomas, lymphomas, and mesotheliomas.

Soft tissue sarcomas are the most common malignant neoplasms of the heart, pericardium, and great vessels.⁸ Among them, angiosarcoma and rhabdomyosarcoma are the most frequent. Occasionally, other rare primary sarcomas like liposarcomas, fibrosarcomas, leiomyosarcomas, etc. are found. Liposarcomas are usually diffuse and involve the right ventricle. The signal intensity is lower than that of fat on T1-weighted images. Leiomyosarcomas (Figure 2) predominate in the muscular arteries and great veins. When located in the inferior or superior vena cava, they may directly involve the right atrium.

Angiosarcoma. One-third of primary malignant cardiac tumors in adults are angiosarcomas. This highly aggressive malignant tumor can develop from the endothelium of the lymphatics, (lymphangiosarcoma), or blood vessels (hemangiosarcoma). Most cardiac angiosarcomas occur in the right atrium as single or multiple nodules infiltrating the myocardium and pericardium. The pericardial sac is filled with the blood. On MR, the angiosarcomas are usually seen as heterogeneous masses with characteristic mosaic pattern of increased and median signal intensity on T1-weighted images. The high signal areas result from intratumoral hemorrhage. T2-weighted images or gadolinium administration usually better delineate the tumor from the normal myocardium.

Rhabdomyosarcoma is the second most frequent primary malignant tumor of the heart and occurs anywhere in the heart. In about 40% of the cases, the pericardium is involved by direct extension from the myocardium. On T1-weighted image, rhabdomyosarcoma appears as homogeneous mass, isointense or minimally hyperintense to the muscle. On T2-weighted images, the tumor is hyperintense to muscle. MR is used in evaluating the response of the tumor to chemotherapy.

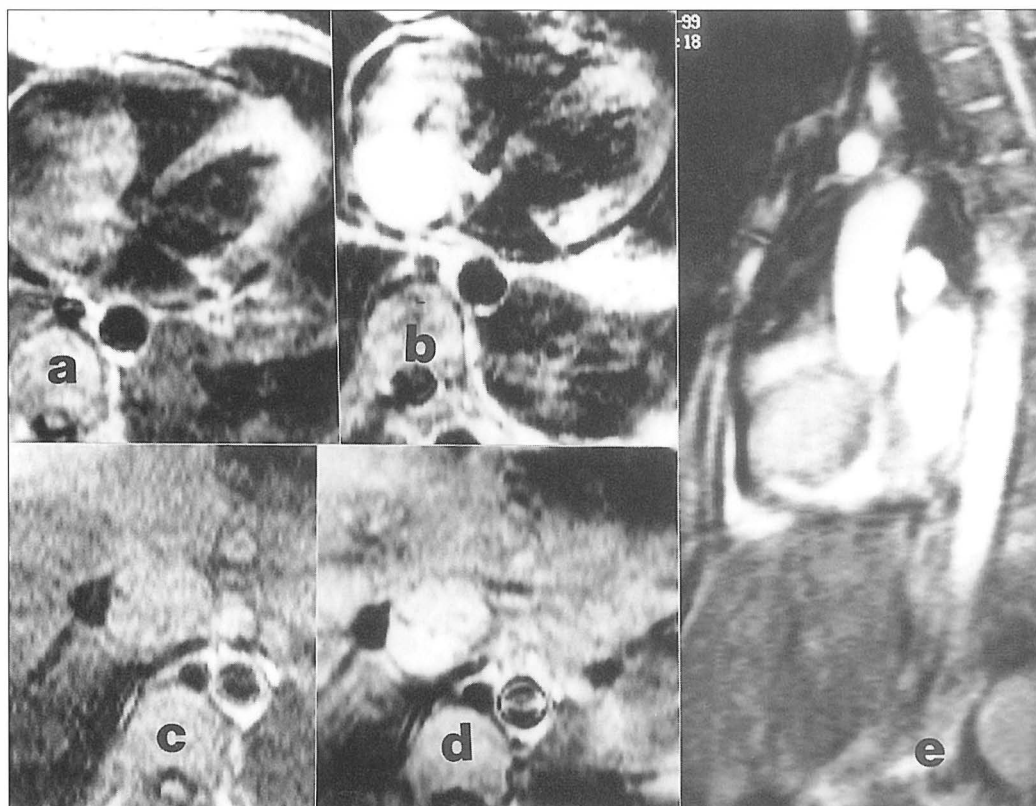


Figure 2. Leiomyosarcoma of the inferior vena cava extending to the right atrium. T1-weighted axial SE images before (a and c) and after (b and d) the administration of Gd-DTPA. The tumor almost completely fills the right atrium, bulges to the right ventricle and blocks VCI. Extensive enhancement after contrast administration (b and d); it is clear that the mass in VCI is not a thrombus but a tumor. e - GE in sagittal plane. A mass of intermediate signal intensity surrounded by the bright intracavitary blood. We performed transjugular biopsy to determine the tumor nature.

Secondary cardiac tumors

Secondary tumors of the heart are approximately 30 times more frequent than primary tumors. Tumors originating in the lung, mediastinum, or breast can directly invade the pericardium or the heart. The most common tumors that metastasize (Figure 3) to the heart are of bronchial and breast origin, followed by melanomas, lymphomas (Figure 4), and leukemia.

Intracaval extension can occur in adrenocortical, hepatocellular, renal-cell and some other carcinomas. It can cause caval obstruction, extension of the tumor thrombus to the

heart causing atrial occlusion, and tumor embolization. Accurate identification is essential to plan treatment and MR can show the extension of an intracaval tumor thrombus. The differentiation between the tumor component and the accompanying bland thrombus is still difficult. Gadolinium administration is helpful because the contrast usually accumulates in the tumor and, to lesser extent, in an old organized thrombus. Lymphomas can spread to the heart via the lymphatic vessels.

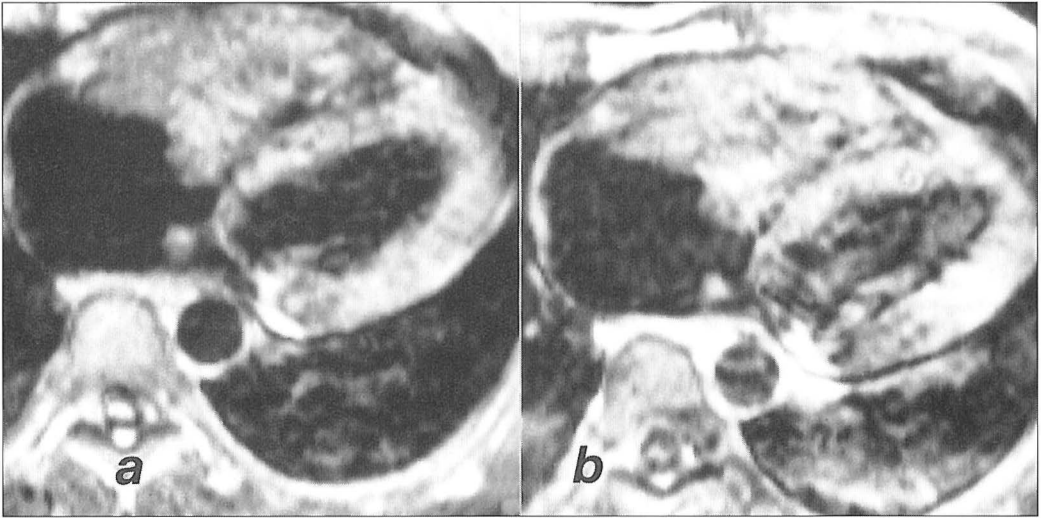


Figure 3. Metastatic seminoma to the right ventricle. T1-weighted axial SE images before (a) and after (b) the administration of Gd-DTPA. The right ventricle is almost completely filled with the tumor-thrombus, that can not be differentiated from the anterior ventricular wall (tumor ingrowth). On operation, anterior wall was invaded and the tumor could not be excised completely.

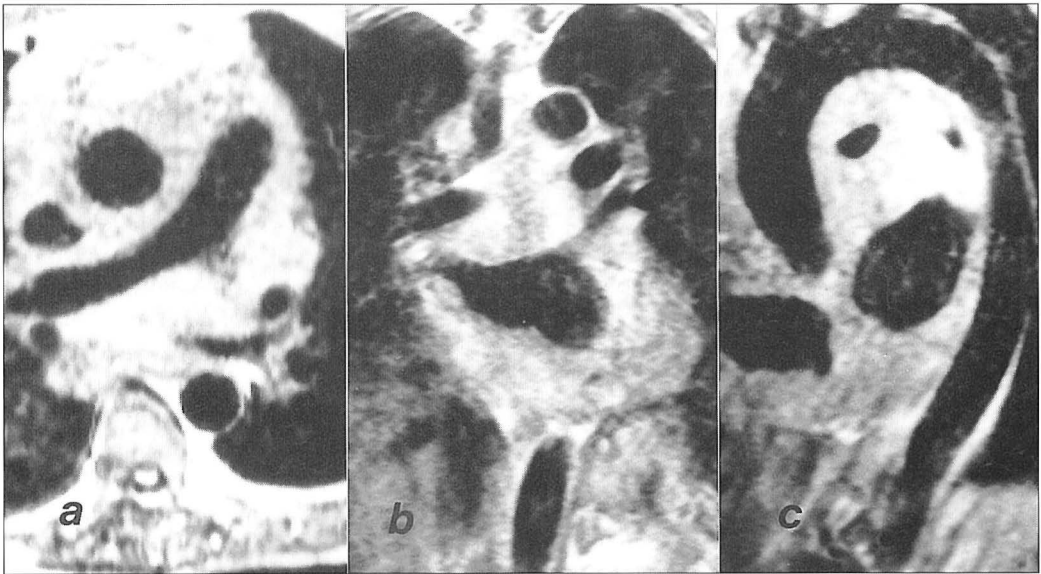


Figure 4. High-grade mediastinal lymphoma diffusely infiltrating the heart. T1-weighted SE images in a - axial, b - coronal, c - LAO plane. The lymphomatous tissue surrounds the ascending aorta, pulmonary arteries and veins. There is a narrowing of the right pulmonary artery and left atrium due to a tumoral thickening of the atrial wall.

Nontumoral cardiac masses and mimics

Cardiac thrombi

Cardiac thrombi are much more frequent than cardiac tumors and usually occur in patients with regional or global wall motion abnormalities (atrial fibrillation, myocardial infarction, dilated cardiomyopathy). Thrombi are mostly found in the atria. The left atrial thrombi are generally attached to the posterior left atrial wall by a broad base. The right atrial thrombi are found in patients with generally poor condition often associated with central venous catheter. Ventricular thrombi are rare in patients with normal cardiac function.⁹

The cardiac thrombi usually have higher signal intensity than the normal myocardium on SE MR. Differentiation between thrombus and slow-flow may be difficult on SE, because of the increased MR signal produced by slow-flowing blood. On gradient-echo (GE), the thrombus always shows a lower signal intensity than does the flowing blood⁴, but is iso- to hyperintense compared with myocardium. That is why the differentiation between thrombus and myocardium on GE is more difficult. The thrombus and the signal intensity change according to its age and degree of organization (loss of water, condensation of paramagnetic iron complexes, calcifications).

The majority of thrombi are immobile. If they are pedunculated and mobile, it may be difficult to distinguish them from a myxoma. Gadolinium administration is helpful because myxomas are highly vascular showing significant enhancement after paramagnetic contrast agents administration. Therefore, GE MR is useful to differentiate between the thrombus and slow-flowing blood, whereas gadolinium administration is helpful to distinguish the thrombus from the tumor.

Lipomatous hypertrophy

Lipomatous hypertrophy of the atrial septum is not a true neoplasm. It is a hypertrophy of preexisting fat and not infrequently associated with increased epicardial fat.¹⁰ The fat accumulates within the interatrial septum, usually in front of the fossa ovalis. The typical appearance is high signal intensity on T1-weighted MR. The differential diagnosis includes lipoma, liposarcoma, and nonacute hematoma. Liposarcoma has a lower signal intensity and inhomogeneity. Fat suppression techniques can be used to differentiate lipomatous hypertrophy of the atrial septum from nonlipomatous tumors and conditions.

Conclusions

With the new cardiac imaging modalities such as echocardiography, CT, and MR, normal anatomic heart structures can be very well recognized and differentiated from pathologic structures.

In patients suspected of having a cardiac tumor, echocardiography is the first method of choice. MR is used to confirm the findings of echocardiography, to determine precisely the tumor location, extent, and its tissue characterization, to follow up of patients under treatment, and to detect early tumor recurrence.

Major advantages of this technique are the excellent spatial resolution, large field of view, natural contrast between the flowing blood and the surrounding heart walls or tumor masses, multiplanar imaging capability, and use of paramagnetic contrast agents for better visualisation of the tumor borders. The large field of view is a clear advantage over echocardiography, while the multiplanar imaging capability without radiation is a clear advantage over CT. On the other hand, MR lacks the ability for real-time imaging though it may become clinically available in the near future.

With MR, cardiac masses can be very accurately depicted or ruled out. MR can be helpful in tissue characterization; however, the differentiation between tumor and nontumoral conditions, or between benign and malignant tumors, is often not possible without histology.

References

1. Hartnell GG. Great vessels of the chest. In: Bogaert J, Duerinckx AJ, Rademakers FE, eds. *Magnetic resonance of the heart and great vessels*. Berlin: Springer; 1999. p.245-62.
2. Gamsu G, Starck D, Webb WR, Moore EH, Sheldon PE. Magnetic resonance of benign mediastinal masses. *Radiology* 1984; **151**: 709-13.
3. Mitchell DG, Burk DL, Vinitski S, Rifkin MD. The biophysical basis of tissue contrast in extracranial MR imaging. *Am J Roentgenol* 1987; **149**: 831-7.
4. Funari M, Fujita N, Peck WW, Higgins CB. Cardiac tumors: assessment with Gd-DTPA enhanced MR imaging. *J Comput Assist Tomogr* 1991; **15**: 953-8.
5. Johnson DE, Vacek J, Gollub SB, Wilson DB, Dunn M. Comparison of gated cardiac magnetic resonance imaging and two-dimensional echocardiography for the evaluation of right ventricular thrombi: a case report with autopsy correlation. *Cathet Cardiovasc Diagn* 1988; **14**: 266-8.
6. Menegus MA, Greenberg MA, Spindola-Franco H, Fayemi A. Magnetic resonance imaging of suspected atrial tumors. *Am Heart J* 1992; **123**: 1260-8.
7. Semelka RC, Shoenuit JP, Wilson ME, Pellch AE, Patton JN. Cardiac masses: signal intensity features on spin-echo, gradient-echo, gadolinium enhanced spin-echo and Turbo FLASH images. *J Magn Reson Imaging* 1992; **2**: 415-20.
8. Burke AP, Cowan D, Virmani R. Primary sarcomas of the heart. *Cancer* 1992; **69**: 387-95.
9. Chin WW, Van Tosh A, Hecht SR, Berger M. Left ventricular thrombus with normal left ventricular function in ulcerative colitis. *Am Heart J* 1988; **116**: 562-3.
10. Meany JFM, Kazerooni EA, Jamadar DA, Korobkin M. CT appearance of lipomatous hypertrophy of the interatrial septum. *Am J Roentgenol* 1997; **168**: 1081-4.