

Transjugular intrahepatic portosystemic shunt (TIPS)

Miloš Šurlan¹ and Janez Jereb²

¹Clinical Institut of Radiology, ²Gastroenterology Department of Internal Clinic, Clinical Centre, Ljubljana, Slovenia

Background. A clear presentation of TIPS indications and contraindications, which can be divided into absolute and relative, is given. Absolute indications are fresh and renewed bleeding of varices and inveterate ascites. Relative indications, on the other hand, are splenomegaly with hypersplenism, Budd-Chiari syndrome, liver transplantation and hepatorenal syndrome. Absolute contraindications are severe liver dysfunction and right heart failure, while the relative ones are polycystic liver degeneration, neoplasm, obstruction of the portal vein and severe local and systemic infection. Before the TIPS procedure, the level of dysfunction of the liver, right heart and kidneys is determined. Biochemical and blood tests, including a blood coagulation test, are made, the ammonia level in the serum is determined and possible obstructions/strictures of the portal vein are checked. A detailed description of the procedure, a care for patient and a postoperative monitoring are given. The success rate of the procedure is between 93 % and 100 % and the mortality rate within 30 days because TIPS is between 1 % and 3 %. The hemorrhage is stopped in 95 % to 100 %, the ascites is improved in 87 % to 92 % and the kidney function in 81 %. In case of hypersplenism the trombocytopenia is improved in 75 % and leucopenia in 50 % of patients. There are relatively few complications during the procedure. Postoperative complications are more frequent due to the stricture and obstruction of the shunt. After a two-year treatment the shunt is passable in 50 % of patients. Thus, in a group of 29 patients, who were treated in the period of four years with an average monitoring period of two years, 22 patients (75,9 %) are still alive and only 7 died (24,1 %). Six of the dead patients suffered from alcoholic cirrhosis of the liver. In two cases the cause of death was not related to the TIPS and the cirrhosis of the liver.

Conclusions. TIPS is an efficient method in stopping recent varicose bleeding, unsuccessfully treated with endoscopic sclerosation or medicaments. It is the most efficient method to lower portal pressure before liver transplantation and ensures safe waiting for liver transplantation and improves conditions for its success.

Key words: protosystemic shunt, transjugular intrahepatic

Received 22 May 2000

Accepted 5 June 2000

Correspondence to: Prof. Miloš Šurlan, M.D., Ph.D.,
Clinical Institut of Radiology, Clinical Centre, Zaloška
c. 7, SI-1000 Ljubljana, Slovenia.

Introduction

The creation of TIPS is a procedure of interventional radiology to lower the portal pressure and treat or avoid complications of the portal hypertension due to liver cirrhosis.

The portal hypertension is defined as a pressure in the portal vascular system over 10-12 mm Hg, or 17-20 cm H₂O.

Due to a high portal pressure, several complications are obtained: GI bleeding, ascites, splenomegaly with hypersplenism and liver encephalopathy. Complications can be treated conservatively, with endoscopic sclerostation and operative procedures - ligation of varicose veins, portal and mesocaval shunts and splenorenal shunts, and nowadays with TIPS.

The first report on TIPS was given by Rosch in 1969¹, and it was clinically introduced by Colopinto in 1982.²

After the use of a metallic stent for forming the shunt by Richter in 200 patients, the procedure became used more often.³ Colopinto used only a balloon dilatation for the shunt formation through the liver tissue before that.

In Slovenia we performed our first TIPS in 1994 in a patient with re-bleeding from varicose veins.

Indications

Indications for TIPS are complications of portal hypertension due to liver cirrhosis. We divide them into absolute and relative. Absolute indications are acute bleeding from varicose veins, in cases where other less invasive methods are unsuccessful, varicose veins re-bleeding and ascites and/or hydrothorax unsuccessfully treated conservatively.^{3,5-7} Relative indications are hypersplenism, avoidance of complications before and after liver transplantation, Budd-Chiari syndrome and hepatorenal syndrome.^{3,5-7}

Contraindications

Contraindications are also divided into absolute and relative. Absolute are profound liver dysfunction and right heart failure.⁵⁻⁷ Relative contraindications are polycystic liver disease, portal vein thrombosis, liver neoplasm, profound liver encephalopathy and systemic or local liver infection.⁵⁻⁷

Preprocedure patient preparation

Before performing TIPS we grade the liver dysfunction according to Child-Pugh, evaluate the right heart function and the renal function because of the use of contrast media. Laboratory liver tests are performed, with serum NH₃ measurement. Basic lab tests of prothrombin time and partial thrombin time are done. We determine the patients' blood group and Rh factor.

With a Doppler US or an indirect portography we obtain the portal vein patency.

Patients' clinical state must be stable. In case of active bleeding the Blakemore's tube is placed to compress the varicose veins.

Technique

A patient is introduced with the plan and the purpose of the procedure. Most procedures are performed in general anesthesia with intubation. The procedure is performed with DSA equipment. The patient is in supine position, with head turned slightly to the left. The right side of the neck is sterile washed, the upper part of the body and head are then sterile covered.

We use transjugular approach, with the puncture of right internal jugular vein with 18 gauge puncture needle. The puncture is controlled by US, which is especially important in coagulopathies. A guide-wire of 0,035 inches is entranced into the right or intermediate liver

vein with the help of curved catheter of 5 F. A catheter sheath of 10F and 40 cm long, with a haemodynamic valve is introduced over guide-wire in the liver vein. A balloon catheter is entranced to close the hepatic vein and 20 ml of CO₂ is injected to obtain a portal venography with DSA. This is important for the determination of the direction and the site of the puncture of the portal vein. We introduce the catheter needle set for the puncture of one of portal veins into the chosen hepatic vein. It contains Teflon tapered catheter of 9 F, with Colapinto needle of 14 gauge inside. The needle has a curved edge to point the direction of the portal vein. The angiographic catheter of 5 F is introduced into the Colapinto needle, to help us, under the support of guide-wire, to introduce a quite rigid needle through the catheter sheath into the hepatic vein. At the puncture site, which is 2-3 cm away from hepatic vein branching, we remove the guide -wire and the catheter. The Colapinto needle is rotated, so its edge is pointed toward a chosen portal vein close to the bifurcation. This is controlled by fluoroscopy in a side projection. If the needle is in the right hepatic vein, the edge is rotated anteriorly and if it is placed in the intermediate vein, it is rotated posteriorly because the intermediate vein lies more anterior than the bifurcation of portal veins. The puncture is performed with a long, sharp needle coated in 5F smooth, Teflon catheter. The needle is 8 cm longer than the Colapinto needle. The distance between a puncture site and big branches of the portal vein is usually 4-6 cm. The puncture is blind or performed under the control of Doppler US. After the puncture, the needle and the catheter are removed slowly, with aspiration. When we aspirate greater amount of blood, we inject contrast. If we, therefore, see one of bigger portal veins, we introduce guide-wire, usually Terumo »J« 0,035 inches or Teflon wire of the same diameter with a very soft edge. The guide-wire is introduced into the superior mesenteric or splenic vein. The

catheter is then pushed into a portal vein stem. Through this catheter the guide -wire is exchanged, for 180 cm long, with 0,035 inches diameter, firmer, for better support during the further catheterisation. The first catheter is exchanged for the aortographic catheter through which we measure the portal pressure and perform the portography. After removing the Colapinto needle and the catheter we perform a dilatation of the tract between the portal vein and hepatic veins in the liver tissue with the use of two balloon dilatation catheters, with 8 and 10 mm in diameter. The length of the tract is measured, and a metallic stent of 12 mm in diameter is placed into it. The metallic stent can reach as deep in the right portal branch as is the bifurcation and 0,5-1 cm deep into the hepatic vein. If the hepatic veins' orifice is narrowed, the stent is placed deep into the veins towards the orifice (Figures 1a, 1b). We mostly use self-expanding stents-Wallstents for TIPS, because it is flexible, with grate radial force.⁸ Its disadvantage is the uneven shortening of the stent while expanding, so the precise positioning is demanding. It has been improved lately, but not completely. After the stent placement the aortography catheter is introduced and the control portography is obtained (Figure 2), with the measurement of the portal pressure. If the shunt is adequate on portogram, with smooth contours, and without grater flow through varicose veins, the portal pressure is usually satisfactory. If not, a dilatation is repeated with a balloon dilatation of 10 mm, in particular the sites of a passage through the vein wall. If the bifurcation of hepatic veins is narrowed, and the portal pressure is therefore still high, due to regenerated liver tissue pressure, another stent is placed into the stenosis (Figures 1a, b). When the portal pressure is satisfactory, which is usually between 20-28 mm Hg, the procedure is finished and the catheter sheath is removed from the jugular vein.

Patients, who are coagulopaths of under-vent complications during the procedure, are

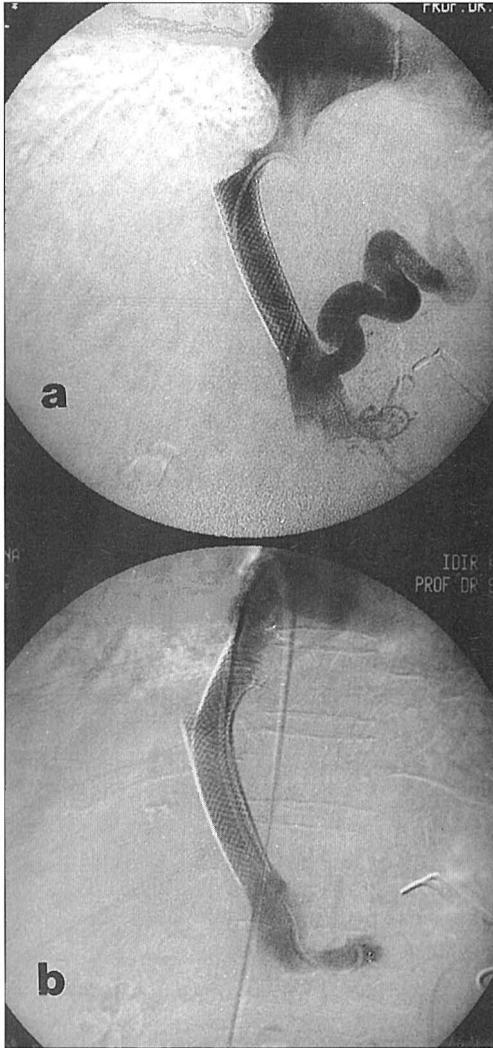


Figure 1a, 1b. Control portography and pressure measurement in portal vein.

a. Ostial stenosis of hepatic veins and hepatic segment of VCI, caused by regenerated liver tissue in cirrhotic liver and fibrosis. Pressure drop in portal vein to 30 cm H₂O was insufficient for the ascites treatment. This was confirmed with a collateral blood flow.

b. With a dilatation of stenosis we showed that stenosis was elastic. After the additional Wallstent placement the pressure in the portal vein dropped to 20 cm H₂O and the vein collateral system was not seen any more. With a diuretic support ascites resolved.

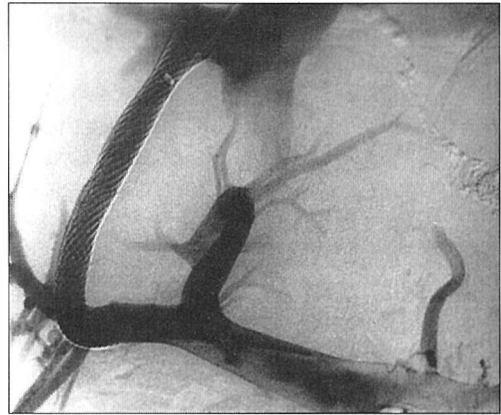


Figure 2. TIPS was performed in a patient with recurrent bleeding from varicose veins. Quite a long shunt created with Wallstent connects the right branch of the portal vein with hepatic veins close to its orifice. A stent is placed in the portal vein peripheral from the bifurcation. Portal blood flow through the branches is preserved. Collateral blood flow is not seen.

transported to the intensive care unit, and otherwise into the half-intensive care for the first 24 hours. During hospitalization the control laboratory liver tests are performed and serum NH₃ level is measured. The control Doppler US is performed to obtain blood flow in the shunt and portal vein.

Long term TIPS patency

TIPS patency is first controlled after 3 months and then every 6 months. The patency is diagnosed with Doppler US and portal venography. Doppler US is a very reliable method.^{9,10} The signs of the shunt malfunction are drop of shunt velocity below 90 cm/sec, change in blood flow direction, and greater drop in portal vein velocity. According to US, we can decide to do the venography with the pressure measurement, which is a golden standard for the definitive diagnosis of the shunt patency.

The shunt occlusion is important if stenosis over 50% of pressure gradient between the portal vein and the right atrium is greater than 15 mm Hg and if varicose veins are fulfilled

again. Varicose vein bleeding or any other clinical sign is, of course, the sign of shunt occlusion. Patients suffering with shunt occlusion have clinical problems in 25%.¹¹

A success rate in TIPS

TIPS is successfully performed in 93-100%. The mortality rate is inside first 30 days approximately 10%,¹¹ due to TIPS procedure in 1-3% of cases. TIPS does not effect the original disease. The survival rate is not only dependent on the shunt function, but also on the liver function and original disease.

Success rate in different indications

Varicose veins bleeding is stopped in 90-100%. Re-bleeding after TIPS occurs in 20% of cases in longer time period.¹¹

Re-bleeding can be stopped with sufficient procedures on TIPS - dilatation, thrombolysis, thrombectomy, another stent placement and additional TIPS. Inveterate ascites and hydrothorax, unsuccessfully treated conservatively are improved in 87-92%.¹² Secondary hypersplenism is improved in 30 days after TIPS, thrombocytopenia in 75%, leucopenia in 50% and both together in 33%.¹³ In hepatorenal syndrome the kidney function is improved in 81% after TIPS.¹⁴

Complications

A bigger haematoma due to arterial puncture in coagulopathy is obtained.

Severe cardiac arrhythmia is experienced due to guide-wire and catheter entrance through the right atrium.

Due to almost blind puncture of the portal vein, hepatic artery injury, biliary tract injury, or hepatic capsular damage and consequently abdominal bleeding can occur.

Pneumothorax and right atrium injury can occur. To avoid these complications an experienced radiologist is essential. The stent can be misplaced or moved by itself or can bent during the entrance and shunt can be occluded by additional thrombosis.

Late complications

Late complications are related to the shunt patency, which progressively lowers with time, due to intimal hyperplasia in the parenchymal part of the shunt and/or neointimal hyperplasia in the hepatic vein. The patency after first 6 months is 71%,¹¹ after 12 months 58-66%^{11,15} after 2 years 42-49%.^{11,15} One of the main reasons for intimal hyperplasia in the shunt is biliary fistula. The entrance of bile and thrombogenic mucin into the shunt accelerates thrombosis and hyperplasia. Some authors, therefore, suggest the exchange of the stent for endoprosthesis.¹²

The causes of neointimal hyperplasia are probably hepatic vein reaction on the injury during the shunt performance, chronic irritation due to the stent placement, and change in haemodynamics in the hepatic vein due to the stent placement.¹⁶ In our cases stenosis in the upper part of the shunt was caused by too low placement of the stent or by stenosis of veins at or around bifurcation, due to the regenerated liver tissue in the cirrhotic liver.

TIPS and liver encephalopathy

After TIPS the liver encephalopathy occurs in 12-36% of cases.^{11,17} It is often hard to find out if the complication preexisted or not.¹⁸ The causes of higher probability for the development of encephalopathy are: preexisting liver encephalopathy, non-alcoholic liver disease, a grade of liver dysfunction, age over 60 years, shunt diameter, gradient pressure between the portal and the systemic vein blood flow.^{7,8,19,20}

Experience of The Clinical Institute of Radiology in Ljubljana with TIPS

In The Clinical Institute of Radiology we treated 41 patients between March 1994 and December 1998, mostly from The Internal Clinic of Gastroenterology in Ljubljana.

The procedure was successful in all cases. We have known data for 29 patients, treated and followed between March of 1994 and March 1998, with average follow up time of 2 years. The cause of the portal hypertension was alcoholic liver disease in 15 patients (50,4%), inflammatory liver cirrhosis in 13 patients (44%) and Budd-Chiari syndrome in one patient (3,4%). According to Child-Pugh's clinical grading, 3 patients (10,3%) were in group A, 12 (41,3%) in group B and 14 (48,2%) in group C.

The indication for TIPS was in 24 (82%) re-bleeding from varicose veins. 3 (10,3%) needed TIPS due to inveterate ascots. In one case TIPS was performed before the liver transplantation to avoid complications before and during the transplantation. In a young patient, 23 years old, we performed TIPS because of hepatic vein thrombosis and saved her life.

Treatment evaluation

Out of 29 patients 22 are still alive (75,1%), 7 patients died. Four patients haven't survived 6 months. One of those, 34 years old alcoholic died 3 month after in a car accident, and 23 years old patient died from bleeding out from the undiagnosed aortic aneurysm of descending aorta. Six out of 7 patients, who died, were alcoholics.

Complications

Two patients had severe bleeding after TIPS. One was bleeding into the pleural space one day after the procedure. The bleeding started after the removal of a portal vein catheter, used for the portography during TIPS. The

other was bleeding due to, probably, the injured liver capsule. Both received transfusion. In the first case thoracic drainage was performed. Both patients were alcoholics, age 34 and 35. The first lived 2 years after TIPS. In the second patient the shunt occluded due to stent bending. He refused the additional TIPS, and died 2 months after leaving the hospital, probably from varicose vein bleeding.

We had 3 late complications with the shunt occlusion, in 2 patients we performed the dilatation and in the third we placed a stent. Occlusion was diagnosed with Doppler US in 2 patients, and in one the varicose bleeding occurred.

Conclusion

TIPS is an efficient method in stopping the recent varicose bleeding, unsuccessfully treated with the endoscopic sclerosation or medicaments. It is usually the bleeding from gastric varicose veins. Most often we lower the portal pressure in re-bleedings and inveterate ascites. Shunt stenosis or occlusion prevents the primary long or life lasting pressure control in the portal system. The secondary shunt patency can improve that, but for that we need a good follow up of patients, which is especially hard in patients with alcoholic liver disease. TIPS is the most efficient method to lower the portal pressure before the liver transplantation and ensures the safe waiting for the liver transplantation and improves conditions for its success.

References

1. Rosch J, Hanafee WN, Snow H. Transjugular portal venography and radiologic portocaval shunt: an experimental study. *Radiology* 1969; **92**: 1112-4.
2. Colapinto RF, Stronell RD, Birch SJ, Langer B, Blendis LM, Greig PD, et al. Creation of an intrahepatic portosystemic shunt with a Gruntzig balloon catheter. *Can Med Assoc J* 1982; **126**: 267-8.

3. Richter GM, Noeldge G, Roessle M, Siegerstetter V, Franke M, Palmaz JC, et al. Transjugular intrahepatic portosystemic stent shunt (TIPSS). *Radiology* 1990; **174**: 1027-30.
1. Šurlan M. Transjugularni intrahepatični portosistemski spoj (TIPS) [abstract]. 1. kongres radiologov Slovenije (z mednarodno udeležbo); 1996 10-12 Oct; Portorož, Slovenia; 1996. p. 42.
5. Namyslowski J. Transjugular intrahepatic portosystemic shunt: Indications, technique and short-term results. 5th International Workshop on Interventional Radiology [abstract]. Prague: Dotter interventional institute, Portland, Oregon & Section of interventional radiology of teh Czech radiological society; 1998. p. 218-20.
6. Lakin PC, Saxon RR, Barton RE. TIPS: Indications and techniques. *Semin Intervent Rad* 1995; **12**: 347-54.
7. Roessle M, Haag K, Ochs A, Sellinger M, Noldge G, Perarnau JM, et al. The transjugular intrahepatic portosystemic stent-shunt procedure for variceal bleeding. *N Engl J Med* 1994; **330**: 165-71.
8. La Berge JM, Ring EJ, Gordon RL, Lake JR, Doherty MM, Somberg KA, et al. Creation of transjugular intrahepatic portosystemic shunts with teh wallstent endoprosthesis: results in 100 patients. *Radiology* 1993; **187**: 413-20.
9. Ferral H, Foshager MC, Bjarnason H, Finlay DE, Hunter DW, Castaneda-Zuniga WR, et al. Early sonographic evaluation of the transjugular intrahepatic portosystemic shunt (TIPS). *Cardiovasc Intervent Radiol* 1993; **16**: 275-9.
10. Zemel G, Katzen BT, Grubbs GE, et al.: Sonographic indicators of unsuccessful transjugular intrahepatic portosystemic shunts. *Radiology* 1994; **193**(P):167.
11. Barton R, et al. TIPS: Short and long term results: A survey of 1750 patients. *Semin Intervent Rad* 1995; **12**: 364-83.
12. Ochs A, Rossle M, Haag K, Hauenstein KH, Deibert P, Siegerstetter V, et al. Teh transjugular intrahepatic portosystemic stent-shunt procedure for refractory ascites. *N Engl J Med* 1995; **332**: 1192-7.
13. Pursnani KG, Sillin LF, Kaplan DS. Effect of transjugular intrahepatic portosystemic shunt on secondary hypersplenism. *Am J Surg* 1997; **173**: 169-73.
14. Brensing KA, Textor J, Strunk H, Klehr HU, Schild H, Sauerbruch T. Transjugular intrahepatic portosystemic stent-shunt for hepatorenal syndrome. *Lancet* 1997; **349**: 697-8.
15. LaBerge JM, Somberg KA, Lake JR, Gordon RL, Kerlan RK Jr, Ascher NL, et al. Two year outcome following transjugular intrahepatic portosystemic shunt for variceal bleeding: results in 90 patient. *Gastroenterology* 1995; **108**: 1143-51.
16. Saxon RR, Mendel-Hartvig J, Corless CL, Rabkin J, Uchida BT, Nishimine K, et al. Bile duct injury as a major cause of stenosis and occlusion in transjugular intrahepatic portosystemic shunts: comparative histopathologic analysis in humans and swine. *J Vasc Interv Radiol* 1996; **7**: 487-97.
17. Saxon RS, Ross PL, Mendel-Hartvig J, Barton RE, Benner K, Flora K, et al. Transjugular intrahepatic portosystemic shunt patency and the importance of stenosis location in the development of recurrent symptoms. *Radiology* 1998; **207**: 683-93.
18. Sanyal AJ, Freedman AM, Shiffman ML, Purdum PP, Luketic VA. Portosystemic encephalopathy following transjugular intrahepatic portosystemic shunt (TIPS): results of prospective controlled study. *Hepatology* 1994; **20**: 46-55.
19. Sahagun G, Benner KG, Saxon R, Barton RE, Rabkin J, Keller FS, Rosch J. Outcome of 100 patients after transjugular intrahepatic portosystemic shunt (TIPS) for variceal hemorrhage. *Am J Gastroenterol* 1997; **92**: 1444-52.
20. Somberg KA, Riegler JL, LaBerge JM, Doherty-Simor MM, Bachetti P, Roberts JP, et al. Hepatic encephalopathy after transjugular intrahepatic portosystemic shunts: incidence and risk factors. *Am J Gastroenterol* 1995; **90**: 549-55.