

## A paraungual tumor? - No, just tungiasis

Rastko Golouh, Marko Špiler

Institute of Oncology, Ljubljana, Slovenia

---

**Background.** *Tunga penetrans* is a burrowing flea that is prevalent in Central and South America, the Caribbean, tropical Africa, India and Pakistan. Tungiasis results from cutaneous infestation by gravid female flea, *Tunga penetrans*.

**Case report.** We report a case of tungiasis in a male who had been on a tourist expedition to Bolivia and Peru. The condition had manifested as a paraungual infiltration of a toe, that was clinically suspicious for tumor.

**Conclusions.** Microscopic examination of the lesion and travel history led to the diagnosis of tungiasis. This is the first case report of *Tunga penetrans* infestation in Slovenia.

**Key words:** tungiasis; *tunga penetrans*; South America; travel; surgical pathology

---

### Introduction

Tungiasis is an unusual zoonosis. In non-endemic countries, it might be misdiagnosed by unaware clinicians and it can even mimic a neoplastic process. For the pathologist, evidence of parasitic infestation in the skin specimen is easily identified. However, the exact typing of the parasite is more difficult.

### Clinical history

The patient was a 46-year-old male who presented with a pea sized induration with a central black pit in paraungual skin of the first

right toe of one month duration. Clinically, a tumor was suspected, and an excisional biopsy was performed.

### Pathological findings

Grossly, the specimen consisted of a wedge excision of the skin measuring 8×6×3mm.

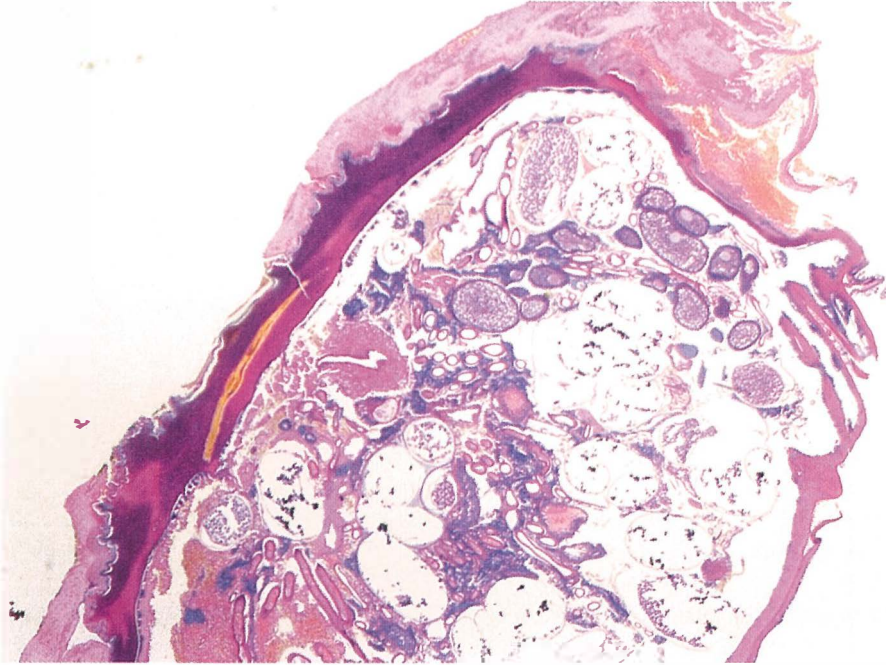
Microscopically, in the epidermis and dermis an organism is found, measuring 6 mm in the largest diameter and covered by a layer of parakeratotic cells (Figure 1).

After studying HE slides, the patient was interviewed again. It became evident that he had recently returned from Bolivia and Peru, having spent two months on trekking there. During this time, he often walked barefoot along the lake sandy beaches. On clinical reexamination, no other skin lesions were discovered.

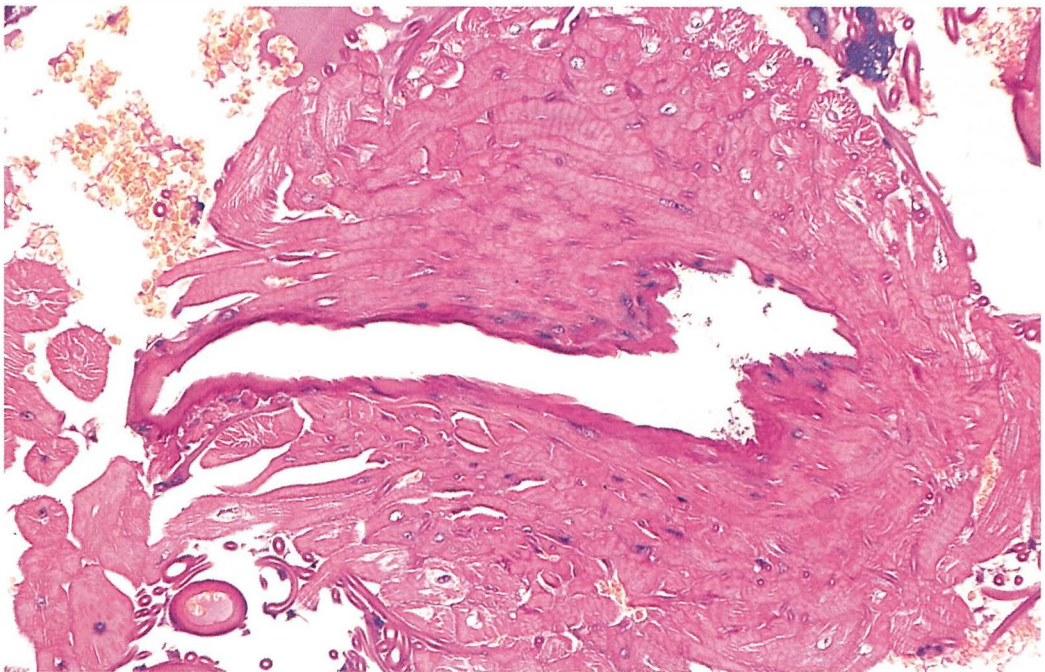
Received 3 November 1999

Accepted 20 December 1999

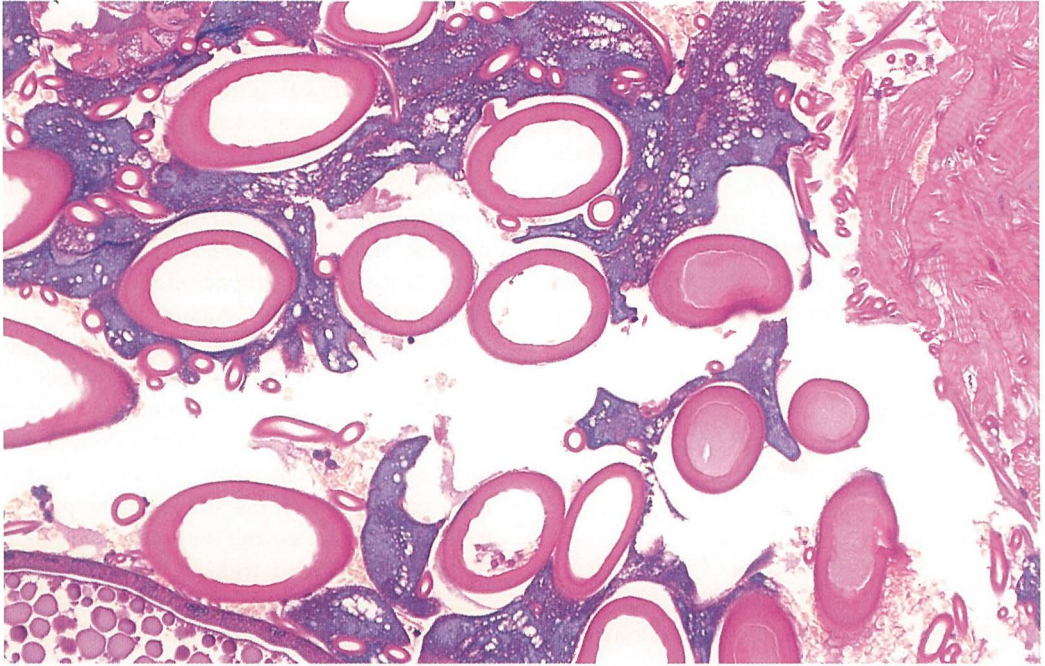
Correspondence to: Prof. Rastko Golouh, PhD, MD, Institute of Oncology, Zaloška 2, 1000 Ljubljana, Slovenia; Fax: 386 61 1314 180.



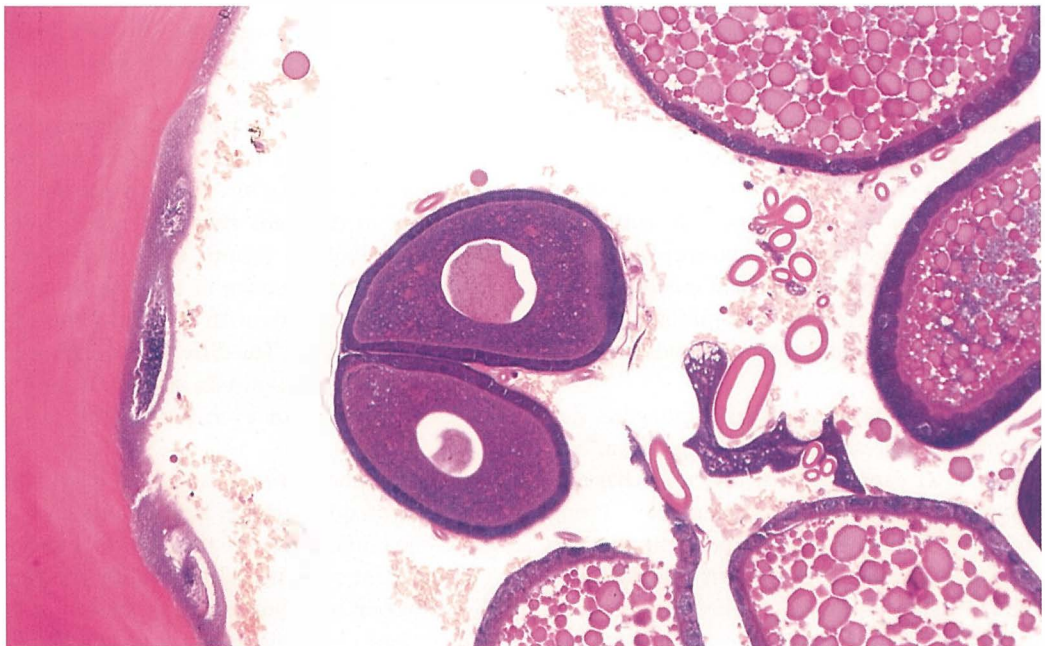
**Figure 1.** By exoskeleton supported body of the insect is localized in the epidermis and upper dermis, 20x.



**Figure 2.** Well developed buccal apparatus with skeletal muscle fibers, 200x.



**Figure 3.** Inside the flea body are typical annular shaped respiratory organs - tracheids, 200x.



**Figure 4.** Eggs of *Tunga penetrans* in different stages of development are mostly oval with thickened wall and a pale center. Some of them superficially mimic Reed-Sternberg cells, 200x.

As we could not identify the parasite, we sent the frozen microscopic pictures using telepathology and Internet to the Armed Forces Institute of Pathology, Washington, and histological slides to Memorial Sloan-Kettering, New York, USA, for consultation. Both consultants (Peter L McEvoy, and Juan Rosai, respectively) independently agreed on the diagnosis of cutaneous tungiasis. Features of the parasite include an exoskeleton, some striated muscle (Figure 2), numerous tracheids - breathing tubes (Figure 3), and many developing eggs (Figure 4). All these features, together with rounded configuration of the organism, are typical of *Tunga penetrans*.

### Discussion

The present case is the first case of tungiasis reported in Slovenia and neither clinician nor pathologist could state the correct diagnosis. The diagnostic dilemma was finally solved by consultation.

Tungiasis is an inflammatory condition of the skin caused by the flea *Tunga penetrans*. Tungiasis is prevalent in Central and South America, the Caribbean Islands, tropical Africa, the Seychelles, Pakistan and along the west coast of India. Typically, Europeans get infested after a visit to endemic countries. Therefore, it should not be too surprising that tungiasis was first reported in crewmen who sailed with Christopher Columbus on the ship *Santa Maria* and were stationed on Haiti in 1492.<sup>1</sup>

The life cycle of this hematophagous flea comprises four stages: adult, egg, larva, and pupa. After copulation the male flea dies and a merry widow begins a pattern of jumping up to 35 cm above the ground until she also dies or succeeds to burrow in the skin of a human being or animal, embedding its head in the dermis and its posterior segment parallel to the skin surface. Through this posterior segment, feces and eggs are extruded and res-

piration is accomplished. After invading the skin, her abdomen swells, the pregnant flea becomes spherical and eventually reaches about 1cm in diameter. Over 1-2 weeks, approximately 200 eggs are extruded. When the eggs are laid the female flea dies and shrivels up. The larvae then undergo two molting stages. Two weeks after hatching from its cocoon, the pupa undergoes development to the final adult stage in 7 days.<sup>2</sup>

Preferred habitats of *Tunga penetrans* include warm, dry, shady, and sandy soil. In humans, the unprotected feet and legs are most exposed to the infestation. When fleas attack they tend to concentrate on the toes, on areas between the toes, in the subungual or periungual areas, the instep and the ankle. Infestation is usually associated with local inflammation and frequently accompanied by intense irritation, tenderness, and even pain. Heavy infestation may lead to ulceration and fibrosis. Clinical features consist initially of pruritic, tender, or painful erythematous papule with a central black dot produced by the posterior part of the flea's abdominal segments. The fully developed lesion is a white pea-sized nodule with a central black pit or plug.<sup>3</sup>

Accurate parasite diagnosis depends on the identification of its ova and body parts. Microscopically, specific findings consist of oval eggs in different stages of maturation, measuring 0.05 to 0.1mm in diameter, tracheids and the presence of the flea, embedded in the epidermis with its head penetrating into the dermis. The differential diagnosis includes viral warts, myiasis, scabies, tick bite, ingrown toenail<sup>4</sup> or even paraungual melanoma as in our case.

The complications of tungiasis, although rare, can be quite severe. Among others, gas gangrene and tetanus are the most dramatic.<sup>4</sup>

Treatment consists of removal of the flea by extraction with sterile needle or by curettage. A topical antibiotic ointment and sterile dressing is then applied. Tetanus prophylaxis should be considered.<sup>5</sup>

According to the literature, tungiasis is rare in Central Europe and only exceptional cases have been reported by Italian<sup>6-11</sup> and German<sup>12-15</sup> authors.

### References

1. Hoeppli R. Early references to the occurrence of *Tunga penetrans* in tropical Africa. *Acta Trop* 1964; **20**: 143-53.
2. Connor DH. Tungiasis. In Binford CH, Connor DH, eds. *Pathology of tropical and extraordinary diseases*; vol 2. Washington, DC. Armed Forces Institute of Pathology; 1976. p. 610-4.
3. Sanusi ID, Brown EB, Shepard TG, Grafton MD. Tungiasis: report of one case and review of the 14 reported cases in the United States. *J Am Acad Dermatol* 1989; **20**: 941-4.
4. Burke W, Jones BE, Park HK, Finley J. Imported tungiasis. *Int J Dermatol* 1991; **30**: 881.
5. Lowry MA, Ownbey JL. A case of tungiasis. *Military Medicine* 1996; **161**: 128-9.
6. D'Antuono A, Gatti M, Negosanti M, Passarini B, Pauluzzi P, Reggiani M. Tungiasis. A clinical case. *G Ital Dermatol Venereol* 1990; **125**: 259-61.
7. Veraldi S, Schinanchi R. Guess what? Tungiasis. *Eur J Dermatol* 1999; **9**: 57-9.
8. Fimiani M, Reimann R, Alessandrini C, Miracco C. Ultrastructural findings in tungiasis. *Int J Dermatol* 1990; **29**: 220-2.
9. Trevisan G, Puluzzi P, Kokelj F. Tungiasis: report of a case. *J Eur Acad Dermatol Venereol* 1992; **1**: 73-5.
10. Carabelli A, Di Vincenzo R, Vanotti P, Bertani E. La tungose. *Nouv Dermatol* 1992; **11**: 826.
11. Veraldi S, Camozzi S, Scarabelli G. Tungiasis presenting with a sterile pustular lesions on the hand. *Acta Derm Venereol (Stockh)* 1996; **76**: 495.
12. Baurle G, Stroothenke M. Tungiasis - eine "Urlaubsdermatose". *Hautarzt* 1981; **32**: 372-3.
13. Peschlow I, Schlenzka K, Merk G, Neumann HJ. Tropendermatosen aktuell Tungiasis, Ulcus tropicum, Leishmaniase Beobachtungen aus der Praxis. *Dermatol Monatsschr* 1983; **169**: 120-4.
14. Schuller-Petrovic S, Mainitz M, Bohler-Sommeregger K. Tungiasis - an increasingly frequent vacation dermatosis. *Hautarzt* 1987; **38**: 162-4.
15. Schmidt C, Ulrich G, Bersch W. Tungiasis - a middle European rare skin parasitosis. A case report. *Pathologe* 1993; **14**: 221-2.