

## Adenocarcinoma skin metastases treated by electrochemo-therapy with cisplatin combined with radiation

Gregor Serša, Maja Čemažar, Zvonimir Rudolf and Albert P. Fras

*Institute of Oncology, Ljubljana, Slovenia*

---

**Background.** The aim of this study was to determine the interaction between electrochemotherapy as a means of facilitated cisplatin delivery into the cells and irradiation of adenocarcinoma skin metastases.

**Case report.** A patient with progressive disease presenting skin metastases of tubal dedifferentiated papillary adenocarcinoma was enrolled in the study. Skin metastases were treated by electrochemotherapy with intratumoral injection of cisplatin. Its antitumor effectiveness was compared to that of combined treatment of irradiation with electrochemotherapy. After a two week observation time, the response to treatment was comparable between the electrochemotherapy and electrochemotherapy combined with irradiation. Both of these treatments were more effective than irradiation alone. Furthermore, antitumor effectiveness of the combined electrochemo- and radiotherapy was found to be quicker than that of electrochemotherapy alone.

**Comment.** This study shows that electrochemotherapy with cisplatin is also effective in the treatment of adenocarcinoma skin metastases. In spite of the short observation time, positive interaction between radiotherapy and electrochemotherapy with cisplatin was found.

*Key words:* skin neoplasms - secondary - therapy; adenocarcinoma; electric stimulation therapy; cisplatin; electrochemotherapy

---

### Introduction

Cisplatin has been reported to enhance the cytotoxicity of radiation in many preclinical studies, *in vitro* on cells, as well as in tumor bearing animals.<sup>1-6</sup> In addition, cisplatin is used in combination with radiotherapy in treatment of a number of solid tumors.<sup>6</sup>

Since the presence of cisplatin during irradiation is essential for radiosensitization of tumor cells, several drug delivery systems were employed in order to increase intracellular accumulation of the drug.<sup>2-4</sup> Among the drug delivery systems that have been tested *in vivo* is also electroporation.<sup>7</sup> This is a physical method of drug delivery that temporarily and reversibly increases plasma membrane permeability and thereby facilitates intracellular accumulation of molecules such as drugs, dyes, antibodies and DNA.<sup>8</sup> When electroporation is combined with chemotherapeutic drugs, the treatment is termed electrochemotherapy.<sup>8</sup>

Received 30 September 1999  
Accepted 29 October 1999

Correspondence to: Gregor Serša, Ph.D., Institute of Oncology, Zaloška 2, SI-1000 Ljubljana, Slovenia.  
Tel./Fax: +386 61 133 74 10; E-mail: gserša@onko-i.si

Electrochemotherapy is effective for drugs with a hampered transport through the plasma membrane, but are very cytotoxic once reaching their intracellular targets. Due to the increased accumulation of bleomycin and cisplatin in tumors, which were exposed to electric pulses, the potentiation of bleomycin and cisplatin antitumor effectiveness was demonstrated on several animal tumor models.<sup>8-12</sup> These two drugs also proved their clinical application in electrochemotherapy protocols both being very effective in the treatment of different cutaneous tumor nodules in cancer patients.<sup>13-19</sup>

Our previous report also indicates that the delivery of cisplatin into the cells by electroporation of tumors increases radiosensitizing effect of cisplatin.<sup>7</sup> Therefore, the aim of this study was to determine the interaction between electrochemotherapy as a means of cisplatin delivery into the cells and irradiation of adenocarcinoma skin metastases.

### Case report

In February 1993 a 53-year old woman was admitted to the Institute of Oncology. After diagnostic laparoscopy, where right adnexal mass was found together with elevated CA 125, she was initially surgically treated. Total abdominal hysterectomy and bilateral salpingo-oophorectomy (TAHBSO), appendectomy, subtotal resection of omentum, and resection of sigmoid colon were performed. No peritoneal implants were present at the time of surgery. Pathohistology of the resected tissue was tubal dedifferentiated papillary adenocarcinoma directly invading omentum, and resected colon. Postoperatively, she continued with cytoxan/paraplatin chemotherapy. On completion of six courses two months later, at second look laparoscopy no residual tumor was present.

Three years later, CA 125 was elevated to 284.6 U/ml. CT scan showed a mass in the

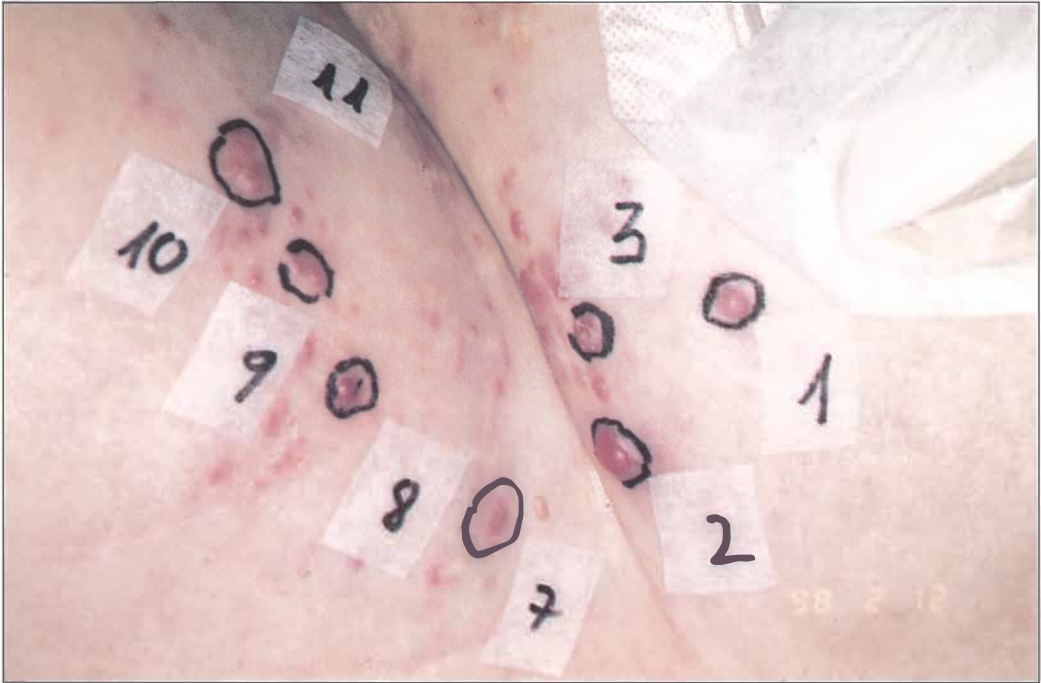
true pelvis left. An ultrasound guided aspiration biopsy was made, and in the bioptic material, malignant metastatic cells were present. A second line chemotherapy cytoxan/paraplatin was introduced. As after six courses of the second line chemotherapy CA 125 did not return to normal value, she was given high voltage irradiation of iliac and paraaortal lymphatic chain. Cumulative dose of 43.5 Gy was delivered in seven weeks. At the end of radiotherapy, CA 125 was still elevated to 108.0 U/ml. She continued with low dose chemotherapy for six months, when supraclavicular metastatic nodes appeared. This region was irradiated with cumulative dose 21 Gy in seven days.

Shortly after the irradiation of supraclavicular nodes, iliac and paraaortal lymphatic chain was irradiated again. The pain in the left leg, indicating on the progression of the disease diminished after 39 Gy irradiation given in three weeks. Three months later suprapubic skin metastases appeared. Skin metastatic spread was observed also in bilateral inguinal regions. Palliative treatment of skin metastases was planned. With progression of recidivant mass in true pelvis ureteral obstruction progressed and one month later the patient died.

Skin metastases were palliatively treated by electrochemotherapy with cisplatin combined with irradiation. Due to a large number of metastases which were up to 20 mm in diameter, it was possible to select groups of metastases that were treated by each modality of the combined treatment (Figure 1). National ethics committee approval and informed consent from the patient was obtained before the beginning of treatment.

Several metastases could not be treated, therefore served as control nodules. Since the observation time was only 11 days, some of them moderately increased in size, whereas in the rest there was no increase.

Electrochemotherapy was performed by the injection of cisplatin to the tumor nodule,

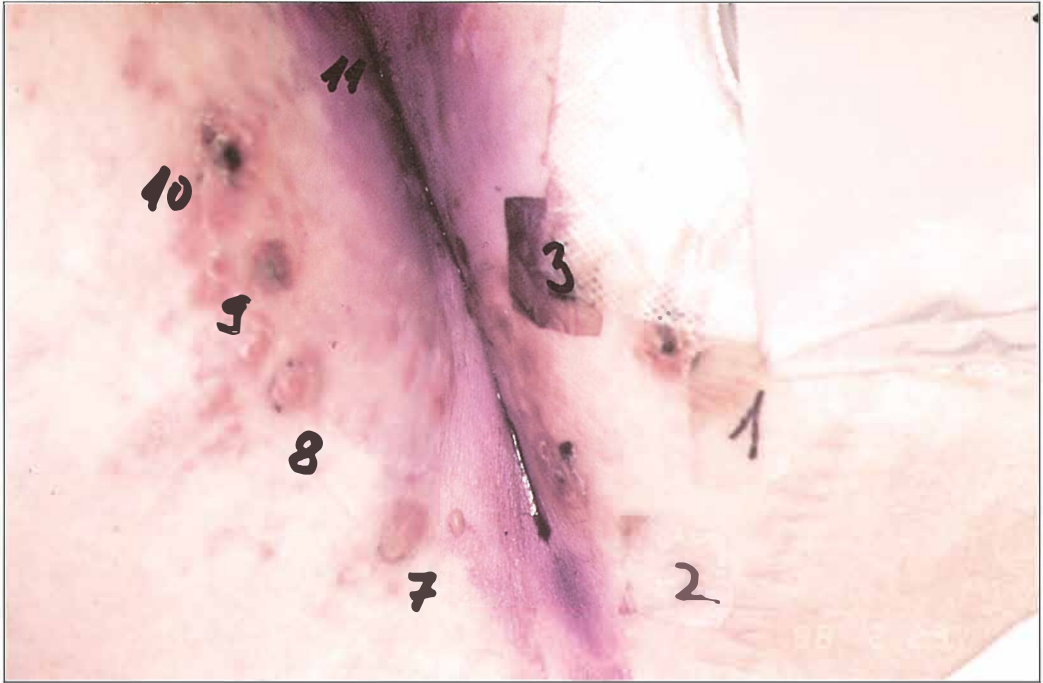


**Figure 1.** Photograph of tumor nodules on the leg before treatment. Nodules 1,2,3 were treated with electrochemotherapy combined with local tumor irradiation, nodule 7 was treated with electric pulses combined with irradiation, nodule 8 was treated with irradiation as single treatment, nodules 9 and 10 were treated with electrochemotherapy and nodule 11 with electric pulses alone. Several unmarked nodules are also present, that were not treated and served as controls.

one to two minutes thereafter electric pulses were applied to the tumor. Cisplatin (Platamine, Pharmitalia) was given at the dose of  $1\text{mg}/100\text{ mm}^3$  tumor volume. Square wave electric pulses of  $100\ \mu\text{sec}$ ,  $910\ \text{V}$  amplitude (amplitude to electrode distance ration  $1300\ \text{V}/\text{cm}$ ), frequency  $1\ \text{Hz}$  were delivered through two parallel stainless steel electrodes (thickness,  $1\ \text{mm}$ ; width,  $7\ \text{mm}$ ; length,  $14\ \text{mm}$ , with rounded tips and inner distance between them  $7\ \text{mm}$ ) with an electropulsator Jouan GHT 1287 (Jouan, France). Each run of electric pulses was delivered in two trains of four pulses, with one second interval in between the two trains, in two perpendicular directions. Good contact between the electrodes and skin was assured by conductive gel. Eleven days after the treatment, the metastases that were treated by cisplatin

alone or exposed to electric pulses alone, were the same size as before the treatment. When both treatments were combined in electrochemotherapy protocol, the treated nodules responded well. They reduced in size, so that under the scab no tumor tissue was palpable, and after 11 days the response to the treatment was evaluated as complete (Figure 2).

Irradiation of tumor nodules was performed by therapeutic X-ray. The dose of  $15\ \text{Gy}$  was moderated by the tubus of the suitable size. Irradiation of the tumor nodules, as single treatment, had no effect on the growth of the tumor nodules (Figure 2). No effect of the treatment was observed either when irradiation was combined with each of the modalities that were used in electrochemotherapy; cisplatin, and application of electric



**Figure 2.** Photograph of the same tumor nodules 11 days after the treatment. Nodules that were treated with electrochemotherapy combined with irradiation responded to the treatment quick. The scab that was formed within two days after the treatment on the tumor nodule 2 and 3 fell off already before day 11. Nodules that were treated with electrochemotherapy (nodules 9,10) also responded well, however the scab is still present. No effect on growth of tumor nodules was observed after irradiation alone, or when combined with application of electric pulses (nodules 7,8).

pulses (Figure 2). Whereas, when electrochemotherapy was combined with irradiation, quick and complete reduction of the size of the treated nodules was observed, within the observation time (Figure 2). Although in both, electrochemotherapy alone and combined with irradiation, the response to the treatment was complete, the effect was found to be quicker after electrochemo-radiotherapy.

### Comment

This case report demonstrates that electrochemotherapy with cisplatin is effective in treatment of adenocarcinoma skin metastases. In spite of the short observation time, positive interaction between electrochemotherapy with cisplatin and radiotherapy was found.

Electrochemotherapy has already proved to be effective in the treatment of cutaneous and subcutaneous tumor nodules of different tumor types. In several studies, it was shown that electrochemotherapy with bleomycin is effective in the treatment of adenocarcinoma, however this is the first report demonstrating antitumor effectiveness of electrochemotherapy with cisplatin on this tumor type.<sup>13</sup>

Electrochemotherapy combines electroporation as a drug delivery system with local or systemic drug administration. If the drug used is cytotoxic, when reaching its intracellular targets, increased cytotoxicity is observed. This was demonstrated in the electrochemotherapy with cisplatin *in vitro*, on experimental tumor models in mice and in patients with cutaneous tumor nodules.<sup>10-12,15,17</sup>

If the drug used in electrochemotherapy is also radiosensitizer, its increased accumulation in tumor cells may lead to better antitumor effectiveness of radiotherapy. In our previous study, we demonstrated that electroporation of mouse tumors increases radiosensitizing effect of cisplatin by 20%. The number of complete responses was increased from 73% in the group of mice treated by cisplatin and irradiation to 92% when electroporation was used as drug delivery for cisplatin combined with irradiation.<sup>7</sup> Treatment of this patient was planned on these preclinical data. Due to a large number of skin tumor nodules, it was impossible to treat them all, and this enabled us to have also pertinent control groups, treated as single or in combination of the two modalities.

This three modality treatment proved its effectiveness in the treatment of adenocarcinoma skin metastases, and form the basis for further studies elaborating electroporation as a nonspecific drug delivery for radiosensitizing and bioreductive drugs in radiotherapy.

### Acknowledgement

This work was supported by research grant from the Ministry of Science and Technology of the Republic of Slovenia.

### References

1. Britten RA, Evans AJ, Allalunis-Turner MJ, Pearcey RG. Effect of cisplatin on the clinically relevant radiosensitivity of human cervical carcinoma cell lines. *Int J Radiat Oncol Biol Phys* 1996; 34: 367-74.
2. Yapp DTT, Lloyd DK, Zhu J, Lehnert SM. Tumor treatment by sustained intratumoral release of cisplatin: Effects of drug alone and combined with radiation. *Int J Radiat Oncol Biol Phys* 1997; 39: 497-504.
3. Theon AP, Madewell BR, Ryu J, Castro J. Concurrent irradiation and intratumoral chemotherapy with cisplatin: A pilot study in dogs with spontaneous tumors. *Int J Radiat Oncol Biol Phys* 1994; 29: 1027-34.
4. Begg AC, Deurloo MJ, Kop W, Bartelink H. Improvement of combined modality treatment with cisplatin and radiation using intratumoral drug administration in murine tumors. *Radiother Oncol* 1991; 31: 129-33.
5. Geldof AA, Kruit A, Newling DW, Slotman BJ. Synergism between cisplatin and radiotherapy in an *in vitro* prostate tumor cell line. *Anticancer Res* 1999; 19: 505-8.
6. Dewitt L. Combined treatment of radiation and cis-diamminedichloroplatinum (II): A review of experimental and clinical data. *Int J Radiat Oncol Biol Phys* 1987; 13: 403-26.
7. Serša G, Kranjc S, Čemažar M. Improvement of combined modality therapy with cisplatin and radiation using electroporation of tumors. *Int J Radiat Oncol Biol Phys* 1999; in press.
8. Mir LM, Orłowski S. Mechanisms of electrochemotherapy. *Adv Drug Deliver Rev* 1999; 35: 107-18.
9. Mir LM, Orłowski S, Belehradek JrJ, Paoletti C. Electrochemotherapy potentiation of antitumor effect of bleomycin by local electric pulses. *Eur J Cancer* 1991; 27: 68-72.
10. Serša G, Čemažar M, Miklavčič D. Antitumor effectiveness of electrochemotherapy with cis-diamminedichloroplatinum(II) in mice. *Cancer Res* 1995; 55: 3450-5.
11. Čemažar M, Miklavčič D, Ščančar J, Dolžan V, Golouh R, Serša G. Increased platinum accumulation in SA-1 tumor cells after *in vivo* electrochemotherapy with cisplatin. *Br J Cancer* 1999; 79: 1386-91.
12. Čemažar M, Milačič R, Miklavčič D, Dolžan V, Serša G. Intratumoral cisplatin administration in electrochemotherapy: antitumoreffectiveness, sequence dependence and platinum content. *Anti-Cancer Drugs* 1998; 9: 525-30.
13. Mir LM, Glass LF, Serša G, Teissie J, Domenge C, Miklavčič D, et al. Effective treatment of cutaneous and subcutaneous malignant tumors by electrochemotherapy. *Br J Cancer* 1998; 77: 2336-42.
14. Rudolf Z, Štabuc B, Čemažar M, Miklavčič D, Vodovnik L, Serša G. Electrochemotherapy with bleomycin: The first clinical experience in malignant melanoma patients. *Radiol Oncol* 1995; 29: 229-35.

15. Serša G, Štabuc B, Čemažar M, Jančar B, Miklavčič D, Rudolf Z. Electrochemotherapy with cisplatin: Potentiation of local cisplatin antitumor effectiveness by application of electric pulses in cancer patients. *Eur J Cancer* 1998; **34**: 1213-18.
16. Heller R, Gilbert R, Jaroszeski MJ. Clinical applications of electrochemotherapy. *Adv Drug Deliver Rev* 1999; **35**: 119-29.
17. Serša G, Štabuc B, Čemažar M, Miklavčič D, Rudolf Z. Electrochemotherapy with cisplatin: Clinical experience in malignant melanoma patients. *Clin Cancer Res* in press
18. Panje WR, Harrell E, Hier M, Goldman A, Garman GR, Bloch I. Electroporation therapy of head and neck cancer. *Ann Oto Rhinol Laryn* 1998; **107**: 779-85.
19. Kubota Y, Mir LM, Nakada T, Sasagawa I, Suzuki H, Aoyama N. Successful treatment of metastatic skin lesions with electrochemotherapy. *J Urol* 1998; **160**: 1426.