

Ultrasound diagnosis of gallstone ileus - a case report

Dubravka Vidmar¹, Stane Repše²

¹Institute of Radiology, University Medical Centre Ljubljana, ²Department of Gastroenterologic Surgery, Division of Surgery, University Medical Centre Ljubljana

Background. The diagnostic method of choice for ileus was a plain abdominal film. However, in the recent years, x-ray has been increasingly replaced by ultrasonography which, in experienced hands, can reveal ileus at an earlier stage and also identify the cause and site of obstruction.

Case report. We reported about a male patient who was admitted to the Department of Gastroenterologic Surgery with severe abdominal pain and vomiting. A plain abdominal film showed an obstructive ileus and pneumobilia. Ultrasound examination of the abdomen confirmed the presence of ileus of the small intestine and demonstrated a gallstone impacted in the distal ileum. It also disclosed a distorted gallbladder adhering to the duodenum. The patient was treated surgically and had an uneventful postoperative course.

Conclusions. Ultrasonography, in addition to diagnosing the ileus caused by an ectopic gallstone, is also able to identify the aetiology and site of obstruction.

Key words: cholelithiasis, intestinal obstruction-ultrasound, gallstone ileus

Introduction

Gallstone ileus (GI) is a form of obstructive ileus in which the obstruction is caused by gallstones that have passed into the bowel through a fistula between the gallbladder and the duodenum.¹ GI accounts for less than 3% of all cases of obstructive ileus, yet this figure is significantly higher in patients over 65 years of age, in whom gallstones are responsible for as many as 25% of cases of bowel obstruction.^{1,2} The most frequent site of obstruction is the terminal ileum (60%), fol-

lowed by other parts of the small intestine, whereas the colon, most frequently the sigmoid, is involved in less than 5% of cases.³ The condition is more common in women than in men, the ratio ranging from 4:1 to 16:1 in various series.² Advanced GI requires immediate surgical treatment; the mortality is five times higher than in bowel obstruction from other causes. Until recently, the diagnostic method of choice was the plain abdominal film. However, plain radiography has several limitations: it fails to show bowel obstruction when the bowel loops are filled with fluid (without gas); it usually cannot detect gallstones as most are not sufficiently calcified; and it does not show minor pneumobilia. Therefore, in the recent years, x-ray has been increasingly replaced by ultrasonography which, in experienced hands, can

Received: 12 November 1998

Accepted 30 December 1998

Correspondence to: Assist. Dubravka Vidmar, MD, Institute of Radiology, University Medical Centre Ljubljana, Zaloška 7, SI-1525 Ljubljana, Slovenia; Phone. +386 61 325 570

reveal ileus at an earlier stage and also delineate gallstones, thereby identifying the cause and site of obstruction. We describe a patient in whom GI was correctly diagnosed by ultrasound and surgical treatment was successful.

Case report

A 47-year-old man was admitted with a 2-day history of upper abdominal pain and vomiting. He was not jaundiced and had a normal temperature. He was constipated for the past few days. Three years before, he was treated in hospital for obstructive jaundice associated with fever. At that time, ultrasound examination demonstrated acute calculous cholecystitis and dilatation of intra- and extra-hepatic bile ducts due to a gallstone lodged in the distal common bile duct. Endoscopic retrograde cholangiopancreatography (ERCP) and papillectomy (EPT) were performed, and a 7 mm stone was removed from the common bile duct. The cholecystitis responded to antibiotic treatment. By the time of discharge, the fever and jaundice had subsided. A cholecystectomy that would be expected to follow the primary operation was not undertaken for unknown reasons. On the present admission, a plain abdominal film showed signs of obstructive ileus and pneumobilia (Figure 1). Ultrasonography performed a few hours later provided evidence of advanced ileus; it showed dilated fluid-filled loops of the small bowel with thickened walls, swollen mucosal folds and absence of peristalsis (Figure 2). Several solid echogenic structures with distal acoustic shadowing suggestive of calculi were visible in the distal ileum (Figures 3a,b). The gallbladder was small and shrunken, it had a thickened wall and adhered firmly to the duodenum (Figure 4). The bile ducts contained air (Figure 5). The liver displayed structural changes compatible with a diffuse parenchymal lesion. There was no free fluid in the peritoneal cavity. These findings spoke in favour

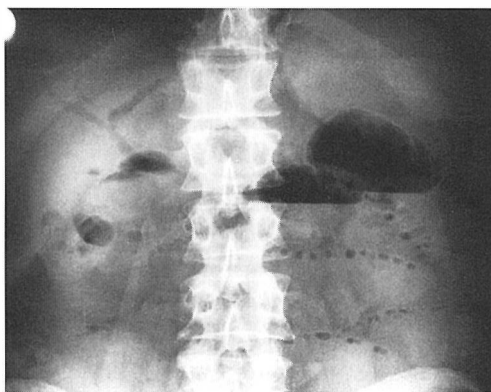


Figure 1. A plain abdominal film on the admission showing obstructive ileus and pneumobilia.

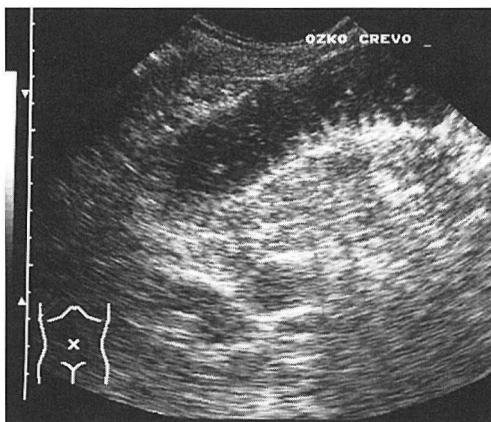


Figure 2. Ultrasonogram showing dilated fluid-filled loop of the small bowel with thickened wall and swollen mucosal folds.

of GI with occlusion in the distal ileum. The patient was immediately prepared for surgery. At operation, the bowel was found to be severely distended to a level about 40 cm proximal to Bauhin's valve, where a hard mass was palpated within its lumen. On enterotomy this proved to be a large gallstone, measuring 2.5 by 2.5 by 5 cm (Figure 6), and two smaller ones. The operation also disclosed adhesions to the liver, a shrunken gallbladder and a fistula, about 2 cm in diameter, between the gallbladder and the duodenum. The gallstones were removed from the ileum, a cholecystectomy was performed, and the

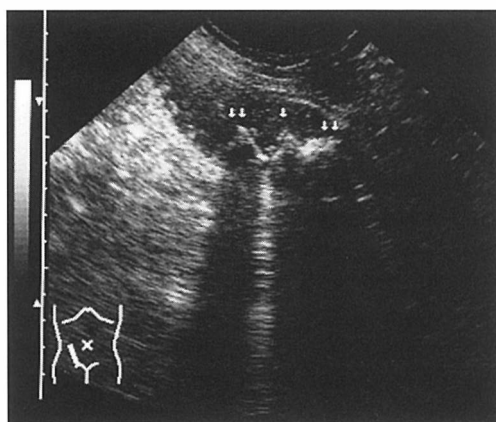
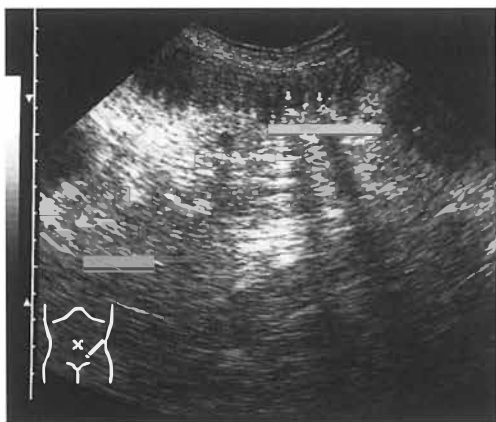


Figure 3a,b. Ultrasonogram showing calculi in the distal ileum.

defect in the duodenum was closed. Postoperatively the patient remained in the intensive care unit for 5 days. His condition was good. On the 7th day, the sutures were removed and he was discharged from the hospital.

Discussion

Gallstone ileus is a form of obstructive ileus that develops as a result of the impaction of gallstones in the gut, mostly in the distal ileum.³ A special form of GI is the so-called Bouveret's syndrome, caused by calculi lodged in the duodenum and obstructing the

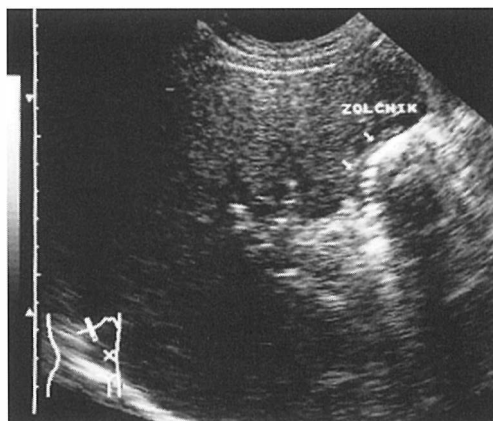


Figure 4. Ultrasonogram showing small, shrunken gallbladder with thickened wall and adhered firmly to the duodenum.

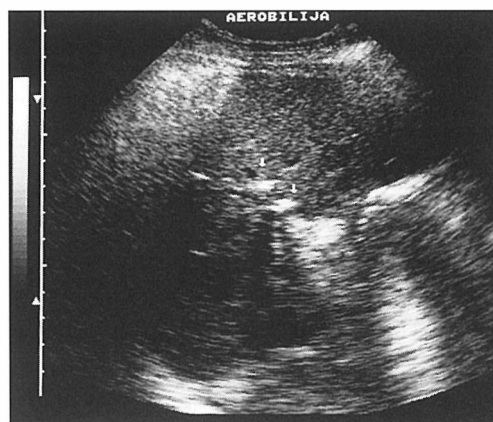


Figure 5. Ultrasonogram showing pneumobilia.

gastric outlet, which accounts for less than 10% of cases.⁴ The calculus enters the intestine through a fistula connecting the gallbladder mostly with the duodenum¹ or, exceptionally, with the colon.⁵ In our patient, the obstruction was located in the distal ileum, and a 2 cm wide fistula was found between the gallbladder and the duodenum. Gallstone ileus typically occurs in elderly women.² So our patient, a 47-year-old man, represents an exception which could be misleading and therefore underscores the need for proper diagnostic evaluation. Many patients are unaware of harbouring gallstones and experi-



Figure 6. A large gallstone, removed from the ileum.

ence no symptoms prior to the development of GI.^{1,2} However, our patient was treated three years previously for acute calculous cholecystitis and obstructive jaundice due to a gallstone in the common bile duct. The cholecystitis was cured and the stone was removed by EPT during ERCP, but there are no data to explain why a cholecystectomy was not performed subsequently. Until recently the diagnosis of GI was based on plain abdominal films demonstrating Riegler's triad of signs: gas in the gallbladder or bile ducts or both, an ectopic gallstone, and partial or complete obstruction of the bowel.^{2,4} However, radiography is sufficiently sensitive in only about a third of cases¹ as (a) it does not show distended bowel loops if they are filled with fluid (unlike ultrasound, which provides excellent visualisation of fluid-filled structures), (b) it demonstrates only about 10% of gallstones, which are adequately calcified, and (c) it does not detect small amounts of air within the bile ducts. In our patient, radiography demonstrated small bowel ileus. Also pneumobilia was clearly visible on the film, undoubtedly as a result of the papillotomy performed three years before, but the stone that caused the obstruction was not apparent. Ultrasound has opened new possibilities in the diagnosis of GI, as in many other areas. Ultrasonography provides reliable detection of (a) dilated fluid-filled bowel loops, (b) all gallstones regardless of their composition, (c) small amounts of gas within

the bile ducts, and (d) a distorted gallbladder displaying even more pronounced changes in gallstone ileus than in cholecystitis or carcinoma.² All these features were present in our patient. Thus, ultrasound examination in GI can diagnose ileus at an early stage and can also identify the cause and site of obstruction, thereby enabling the surgeon to minimise the surgical trauma. It can detect any additional stones which must be removed promptly in order to prevent recurrent obstruction of the bowel. In the literature, a pitfall in ultrasound diagnosis is illustrated by a patient in whom ileus was caused by adhesions, while the presumed stone visible in the right lower quadrant was in fact a calcified mesenteric lymph node.¹ In our opinion, such errors are unlikely since an experienced examiner will readily locate a gallstone within a dilated bowel loop. The appraisal of a severely altered, emptied gallbladder, firmly adhering to the duodenum, may present some more difficulties since the presence of air within the connecting fistula precludes a clear view. However, the main shortcoming of ultrasonography is that its diagnostic yield continues to depend to a large extent on the examiner's skill. Contrast studies, computed tomography (CT) and endoscopy play a minor role in the diagnosis of GI. Attempts at endoscopic extraction of the stone may be successful mainly in Bouveret's syndrome.^{1,2,4-7}

The treatment of GI is almost exclusively surgical. Spontaneous excretion of the stone is extremely rare^{2,4} but successful removal by endoscopic short wave lithotripsy has been reported.⁶ At operation the ileus must be released. If the patient's condition permits, cholecystectomy is also performed and the fistula is repaired at the primary operation, as was done also in our patient. In this way, recurrent ileus caused by additional stones present in the gallbladder, as well as recurrent cholecystitis, cholangitis and malignant transformation of a persistent fistula can be avoided.² Since GI mostly occurs in elderly

patients, the mortality is high, which is attributed mainly to long delays before admission and before the diagnosis is established, dehydration due to vomiting, and a deterioration of coexisting diseases that are common in the elderly.² Our patient was relatively young and his general condition was good; he experienced no complications during the operation, which comprised also a cholecystectomy and fistula repair, and he had an uneventful postoperative course.

Conclusions

Ultrasound examination affords rapid and reliable diagnosis of gallstone ileus and identifies the site of intestinal obstruction. This shortens the time to surgery, reduces the operative risk and contributes to a favourable outcome of this serious condition.

Our patient was relatively young and his general condition was good; he experienced no complications during operation, which comprised also a cholecystectomy and fistula repair, and he had an uneventful postoperative course.

References

1. Davies RJ, Sandrasagra FA, Joseph AEA. Ultrasound in the diagnosis of gallstone ileus. *Clinical Radiology* 1991; **43**: 282-4.
2. Lason A, Loren I, Nilsson A, Nirhov N, Nilsson P. Ultrasonography in gallstone ileus: a diagnostic challenge. *Eur J Surg* 1995; **161**: 259-63.
3. Catalano O, Rotondo A. Ileo biliare del sigma: diagnosi ecografica. *Radiol Med* 1994; **87**: 519-20.
4. Košorok P. Bouveretov sindrom- visoki biliarni ileus. *Med Razgl* 1996; **35**: 421- 8.
5. Swinnen L, Sainte T. Colonic gallstone ileus. *J Belge Radiol* 1994; **77** (6): 272- 4.
6. Sackmann M, Holl J, Haerlin M, Sauerbruch T, Hoermann R, Heinkelein J. Gallstone ileus successfully treated by shock- wave lithotripsy. *Digestive diseases and sciences* 1991; **36**: 1794-5.
7. Moratti A, Stigliani F, Antonica E, Sacchero R: La sindrome di Bouveret. *Radiol Med* 1991, **81**: 560- 1.