

Role of color Doppler US in the diagnosis of focal nodular hyperplasia of the liver: a case report

Dubravka Vidmar¹, Alenka Višnar-Perovič¹, Bojana Černelc¹,
Saša Markovič², Verica Ferlan Marolt³, Milan Gorenc¹

¹Institute of Radiology, University Medical Center Ljubljana, ²Institute of Oncology Ljubljana,

³Institute of Pathology, Faculty of Medicine, University of Ljubljana, Slovenia

Presented is a case of a female patient who underwent ultrasonography because of unspecific abdominal difficulties. This examination unexpectedly revealed a round lesion in the liver. Due to characteristic age, sex, many-year history of oral contraceptive use (OCC) and typical ultrasonographic image of the lesion, focal nodular hyperplasia (FNH) was suspected right from the beginning, and the patient was examined with color Doppler US. The imaged vascular distribution was typical of FNH. Apart from laboratory tests, further diagnostic work-up included only a contrast CT examination. On the follow-up examination carried out a few months later the findings of Doppler spectral analysis showed that the vascular system of the lesion consisted of both arteries and veins. Owing to the controversial data reported in the literature regarding the presence of veins, a biopsy was performed as well, and the findings obtained indisputably confirmed the diagnosis of FNH. Although a conclusive diagnosis of FNH cannot be made by means of color Doppler US alone, a suspicion based on that examination is well grounded.

Key words: liver disease-ultrasonography; hyperplasia; ultrasonography, Doppler, color

Introduction

Focal nodular hyperplasia (FNH) is a rare benign lesion of the liver parenchyma, which occurs most frequently in women of reproductive age.¹⁻⁴ The lesion can be discovered by chance in an asymptomatic patient, or, if very large, by causing unspecific problems.⁵ Histologically, it consists of dense connective tissue, which forms a central scar and stellate

fibrous structures (septa) rising from it; between them, there is hyperplastic liver parenchyma and small bile ducts presumably created by hepatocyte metaplasia. Both the central scar and the septa running towards periphery contain numerous thick-walled arteries.^{6,7,8} It has been speculated that FNH perhaps occurs as a hyperplastic response of liver parenchyma to abnormal blood supply due to a pre-existent vascular malformation. Persons with FNH often present with different vascular anomalies such as teleangiectasies, hemangiomas, A-V malformations, etc.^{2,6} The lesion is most commonly associat-

Correspondence to: Dubravka Vidmar, M.D., Institute of Radiology, University Medical Center, Zaloška 7, 1000 Ljubljana. Tel.: +386 61 325-570; Fax: +386 61133 10 44

ed with the use of oral contraceptives (OC),^{1,2,9,10} although it appears that these, rather than being directly responsible for its rise, they stimulate the lesion's growth and vascularization.^{6,7,8} According to some reports, the lesion underwent a regression after the cessation of OC use.²

The non-invasive color Doppler investigation is considered very useful for imaging of the typical vascular structure with the main feeding artery supplying the central scar and its stellate structures.⁴ A case of a female patient with very typical Doppler image is presented.

Case report

A 33-year old woman with a five-year history of OC use was referred for ultrasonography of the abdomen owing to unspecific difficulties related to voiding of urine. The examination revealed a 6x4 cm large round hypoechoic single nodule in the IVth liver segment. Radially from the center of the lesion running stellate formations, which were even more hypoechoic than the lesion itself, were evident already on the B mode sonogram (Figure 1).

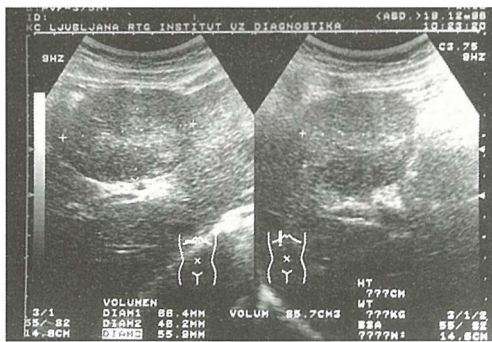


Figure 1. Hypoechoic nodule (FNH) with a central scar and radially from the center running hypoechoic vessels.

The solitary nodule was situated subcapsularly. The remaining liver parenchyma was normal.

Apart from OC use, there was no evidence of disease, and/or alcohol or drug abuse in the patient's previous medical history. Except for palmar erythema of the limbs, the patient's clinical status showed no evidence of other abnormalities.

The diagnostic procedures were continued with color Doppler US on a Toshiba SSA 270 A unit with a 3.75 MHz probe. Additional options, such as power Doppler, color persistence and color capture, were used for enhancing the blood-flow signal.

The lesion was hypervascular, with blood vessels arranged in a stellate formation: smaller branches emerging from a larger feeding artery of the central scar were running towards the periphery.

The findings of that examination were strongly suggestive of FNH, and the patient was seen by a counsel team for hepatic tumors. She underwent laboratory tests and contrast CT scan, which imaged a central scar with typical stellate vascular formation; all this confirmed the suspected diagnosis of FNH which was based on ultrasonography.

On the next follow up a few months later, the B mode US and color Doppler examinations evidenced the same size, B mode appearance and internal vascular structure of the lesion as on the first examination. In addition, a spectral analysis of the vessels in the lesion showed that the signals obtained from the vessels running radially from the center to periphery yielded arterial as well as venous curves (Figure 2,3). As various reports from the literature dealing with FNH exclude the presence of veins in the center of the lesion, a core-biopsy was performed in addition, which unequivocally confirmed the diagnosis of FNH.

A follow-up US one year after the first examination did not show evidence of morphological changes in the lesion. The patient is free of any subjective complaints while the follow-up laboratory findings are within normal limits.

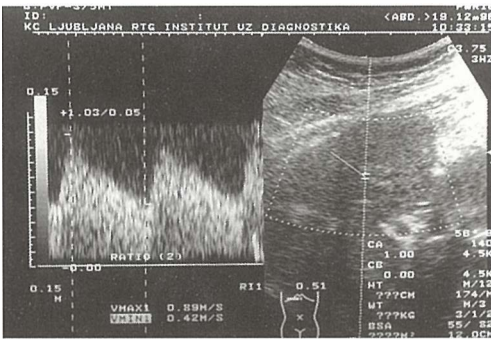


Figure 2. The so-called feeding artery which encircles the lesion (FNH) and enters it through the central scar - the spectral analysis curve.

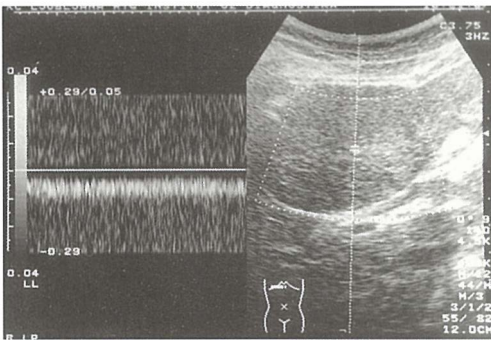


Figure 3. The spectral analysis Doppler curve has revealed veins as well as arteries in the center of the lesion. A core-biopsy was performed to exclude hepatic adenoma.

Discussion

Most often, focal nodular hyperplasia (FNH) is found by chance as a benign round lesion in the liver. Generally it is asymptomatic; only if very large, it may create unspecific difficulties.^{2,5} Apart from B mode ultrasonography and color Doppler US, the diagnostics of FNH may employ various other non-invasive as well as invasive investigations, such as contrast CT scan, scintiscan with Tc-99, MRI, angiography and core-biopsy. Combined radiological investigations ensure 75-83% reliability of diagnosis.² In limited circumstances, the diagnosis of FNH can be obtained by non-invasive methods with a high degree of probability.² Although US is a very sensitive

method for the detection of round lesions in the liver, a B mode US appearance (image) of FNH is insufficiently specific to enable us to distinguish between FNH and other benign or malignant lesions.⁴ This is also the case when the lesion is situated in a typical site (subcapsularly, more frequently in the right lobe), and if it is feasible - exceptionally - to image the central scar with otherwise rarely present calcinations, or even its stellate formations.²

With color Doppler method coming into use, differential diagnostics was given new means to distinguish between various round lesions of the liver by imaging their blood flow, and thus enhance the specificity of ultrasonography. Several authors report the findings of their studies on vascularization of round lesions in the liver, and their attempts to use these findings for better differentiation between the lesions in question.¹⁰⁻¹⁵ In this respect, quantitative measurements of blood flow have not turned out relevant, particularly not in small lesions.^{1,9} Greater specificity was noted with respect to the quantity (extent), type and distribution of vessels in the lesion.¹³ The most precise image of the vascular formation, which also includes the capillary phase, can be obtained with a US contrast medium in the form of micro-bubbles.⁵ Possible causes of unsuccessful imaging of the vascular system could be attributed to: a) a deep site of the lesion within the liver parenchyma; b) insufficient vein caliber; c) closeness of large vessels, their signals causing artifacts which hamper identification of smaller vessels in or next to the lesion; d) hemorrhage in the lesion.⁹

FNH is a hypervascularized lesion which comprises arteries distributed in a characteristic pattern: the so-called feeding artery, which encircles the lesion and enters it through the central scar, gives rise to a stellate formation of smaller arteries running peripherally through fibrous septa. Such apparent hypervascularization yields a stel-

late Doppler image.^{1,2,3,4,5,10,11} Reports on simultaneous identification of drainage veins are scarce.^{4,11} Moreover, the findings of veins in the lesion is believed to correlate histologically with hepatic adenocarcinoma, and thus exclude the possibility of FNH.^{9,10}

In the presented patient, the B mode ultrasonographic appearance (image) of the lesion was consistent with the morphological features that are most frequently associated with FNH: the lesion was of an average size (6x4 cm), situated subcapsularly in the right liver lobe (IVth segment), and was moderately hypoechoic against the surrounding liver parenchyma which was completely healthy. There was also an indistinct evidence of a central scar and its septa extending peripherally. No calcinations in the central scar could be found. Although the presence of these in FNH is possible, such a finding is rare and fairly atypical; it ultimately requires biopsy to differentiate the lesion from fibrolamellar hepatocellular carcinomas. The latter occurs most frequently in the population of previously healthy women of the same age group, and is characterized - likewise FNH - by a central scar; in the latter, however, the presence of calcinations is significantly more frequent than in FNH.¹⁶

The lesion showed a distribution of blood vessels which is characteristic for FNH: a large feeding artery entered the lesion centrally, and afterwards fanned out with radially running branches. According to data reported in the literature, the typical vascularization pattern was consistent with the diagnosis of FNH. However, a subsequent spectral analysis has revealed that the radially running blood vessels were arteries as well as veins. Considering the commonly present belief that the presence of veins in a lesion speaks for a hepatic adenoma, which has a different clinical course and therefore requires a different management than FNH, a core-biopsy was performed as well; the latter examination clearly confirmed the diagnosis of FNH.

Conclusion

When an asymptomatic, formerly healthy female of a reproductive age has a round liver lesion detected on ultrasonography while color Doppler US images the typical vascularization pattern within the lesion, the suspicion of FNH is well grounded. Our spectral analysis revealed that the histologically confirmed FNH contained arteries as well as veins. Although ultrasonographic and color Doppler investigations cannot ascertain a conclusive and final diagnosis of FNH, both methods can considerably reduce the diagnostic procedure.

References

1. Golli M, Mathieu D, Anglade M-C, Cherqui D, Vasile N, Rahmouni A. Focal nodular hyperplasia of the liver: value of color doppler US in association with MR imaging. *Radiology* 1993; **187**: 113-7.
2. Di Stasi M, Caturelli E, De Sio I, Salmi A, Buscarini E, Buscarini L. Natural history of focal nodular hyperplasia of the liver: an ultrasound study. *J Clin Ultrasound* 1996; **24**: 345-50.
3. Bazzocchi M, Macorig D, Cecconi P, Gozzi G. Diagnostica per immagini dell' iperplasia nodulare focale epatica. *Radiol Med* 1991; **82**: 805-13.
4. Sawhney S, Jain R, Safaya R, Berry M. Pedunculated focal nodular hyperplasia. *Pediatr Radiol* 1992; **22**: 231-2.
5. Kudo M, Tomita S, Minowa K, Tochio H, Shimada K, Mimura J. Color doppler flow imaging of hepatic focal nodular hyperplasia. *J Ultrasound Med* 1992; **11**: 553-7.
6. Schuer PJ, Lefkowitz JH. *CH 11 in liver biopsy interpretation*. London: WB Saunders Company; 1994.
7. International working party. Terminology of nodular hepatic cellular lesions. *Hepatology* 1995; **22**: 83- 99.
8. Craig JR, Peters RL, Edmondson HA. *Tumors of the liver and intrahepatic bile ducts*. Armed forces institute of pathology Washington; 1988. p. 8 - 18.
9. Golli M, Van Nhieu J T, Mathieu D, Zafrani ES,

- Cherqui D, Dhumeaux D. Hepatocellular adenoma: color doppler US and pathologic correlations. *Radiology* 1994; **190**: 741-4.
10. Bartolozzi C, Lencioni R, Paolicchi A, Moretti M, Armillotta N, Pinto F. Differentiation of hepatocellular adenoma and focal nodular hyperplasia of the liver: comparison of power Doppler imaging and conventional color Doppler sonography. *Eur Radiol* 1997; **7**: 1410-5.
 11. Borner N, Clement T, Herzog P, Kreitner KF, Miltenberger H, Schild H. Farbcodierte Dopplersonographie (FD-Sonographie) primärer und sekundärer Lebertumoren. *Ultraschall in Med* 1990; **11**: 274-80.
 12. Weimann A, Repp H, Klempnauer J, Gebel M, Lang H, Ringe B. Diagnostic value of color doppler sonography in primary liver tumors- a trend study. *Bildgebung* 1993; **60**: 140-3.
 13. Nino-Murcia M, Ralls PW, Jeffrey RB Jr, Johnson M. Color flow doppler characterization of focal hepatic lesion. *Am J Roentgenol* 1992; **159**:1195-7.
 14. Numata K, Tanaka K, Mitsui K, Morimoto M, Inoue S, Yonezawa H. Flow characteristics of hepatic tumors at color doppler sonography: correlation with arteriographic findings. *Am J Roentgenol* 1993; **160**: 515-21.
 15. Tanaka S, Kitamura T, Fujita M, Nakanishi K, Okuda S. Color doppler flow imaging of liver tumors. *Am J Roentgenol* 1990; **154**: 509-14.
 16. Caseiro-Alves F, Zins M, Mahfouz A-E, Rahmouni A, Vilgrain V, Menu I. Calcification in focal nodular hyperplasia: a new problem for differentiation from fibrolamellar hepatocellular carcinoma. *Radiology* 1996; **198**: 889-92.