

## Color doppler for the evaluation of puncture site complications after percutaneous coronary interventions

Andreja Černe, Igor Kranjec, Mirta Koželj, Jadranka Buturović Ponikvar

Department of Cardiology, University Medical Center, Ljubljana, Slovenia

*Femoral access site complications (FASC) after percutaneous coronary interventions (PCI) may be frequent, difficult to identify, and associated with significant morbidity. To refine our catheterization technique, we performed duplex color flow imaging (DCFI) in 42 consecutive patients undergoing diagnostic coronary arteriography (Group A) or PCI (Group B). In all patients, arterial (6-9F) and venous femoral sheaths (8F) were inserted by the Seldinger technique followed by the IV bolus of heparin (3000-10000 U). In Group A, the sheaths were removed immediately after the procedure. In Group B, heparin infusion (1000 U/hr) was started after PCI, and the sheaths were removed the following morning. DCFI was performed the day after catheterization using the 7.5 MHz linear phased-array transducer. Abnormal physical (groin swelling, new bruit) and ultrasound findings (hematoma, pseudoaneurysm, AV fistula) were recorded in 11 patients (26.2 %) and 15 patients (35.7 %), respectively. In patients with groin swelling or new bruits, DCFI revealed hematomas, pseudoaneurysms, or AV fistulas. FASC correlated with age >65 years ( $p < 0.05$ ), sheath size ( $p < 0.01$ ), and heparin dosage ( $p < 0.01$ ). In conclusion, FASC occur often after PCI, and can be easily identified by DCFI. Risk factors include advanced age, large sheaths, and more aggressive heparin administration. Early detection using DCFI will minimize the morbidity associated with FASC.*

*Key words:* angioplasty, transluminal, percutaneous coronary-adverse effects; coronary angiography-adverse effects; femoral vein-ultrasonography.

### Introduction

Femoral access site complications (FASC) following percutaneous coronary interventions (PCI) add morbidity to the procedures and increase costs by prolonging hospital stay. FASC have been reported with increasing frequency, partly due to older patients with more extensive peripheral vascular disease, as well as owing to the widespread use of anticoagulant/fibrinolytic therapy, and larger size vascular sheaths.<sup>1-11</sup> Hematoma is the most common finding and represent a simple collection of blood with no communication with the punctured

vessel.<sup>12</sup> Pseudoaneurysm results from leakage of blood into the soft tissues around the femoral artery, with subsequent fibrous encapsulation and failure of the defect in the vessel wall to heal.<sup>13</sup> AV fistula is an abnormal communication between the artery and the vein, occurring when a needle tract crosses both the artery and the vein and is dilated during catheterization.<sup>14, 15</sup> While hematoma is almost always spontaneously resorbed, pseudoaneurysm and AV fistula represent potentially unstable lesions, which may predispose to more serious sequelae. They may give origin to emboli; and may cause local infection, vascular thrombosis, or pressure effects and might rupture or cause high-output cardiac failure.<sup>16</sup> Several previous reports emphasized the limitations of physical findings, such as pulsatile groin mass, enlarging ecchymosis, abnormal puncture site pain and a new audible bruit in the clinical setting of peripheral vascular inju-

Correspondence to: Andreja Černe, M.D., Department of Cardiology, University Medical Center, Zaloška 7, 1000 Ljubljana, Slovenia.

ries.<sup>17,18</sup> Nowadays, duplex color flow imaging (DCFI) is believed to be the leading noninvasive, highly specific and sensitive modality for the diagnosis, planning of therapy and follow-up of potential FASC.<sup>19-23</sup> It allows for simultaneous 2D imaging of anatomic structures and Doppler study of blood flow, thus eliminating the need for invasive radiological procedures.<sup>20-23</sup>

In order to refine our current catheterization technique, FASC were prospectively evaluated in our group of patients following diagnostic coronary arteriography or PCI. The aims of this study were threefold: 1) to detect the frequency and nature of femoral access site complications in our group of patients; 2) to assess the utility of clinical signs in the diagnosis of vascular complications as verified by DCFI findings; 3) to identify clinical and procedural factors that would predict the likelihood of these complications in our catheterization laboratory.

## Materials and methods

### *Catheterization procedures*

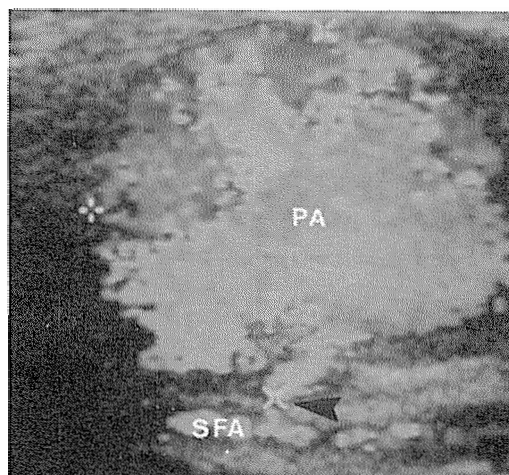
42 consecutive patients undergoing diagnostic coronary arteriography (Group A, 22 patients) or PCI with PTCA and stenting (Group B, 20 patients) at the Department of Cardiology, University Medical Center, Ljubljana, were enrolled in the prospective study between October 12, 1995 and February 20, 1996. Cardiac catheterizations were performed by four skilled interventional cardiologists. In all patients, arterial (Group A, 6F; Group B, 9F) and venous femoral sheaths (8F) were inserted using the Judkins approach by the double-wall Seldinger technique, followed by IV administration of a heparin bolus (Group A, 3000 U; Group B, 10000 U). In Group A, the sheaths were removed immediately after the diagnostic procedure. In Group B, heparin infusion (1000 U/hr) was started after PCI and the sheaths were removed the following morning 4 hrs after the discontinuation of heparin. The patients were maintained on bed rest for 6 (Group A) or 12 hrs (Group B) thereafter.

### *Clinical detection of vascular complications*

Following the removal of sheaths each patient was examined for evidence of prolonged bleeding, subcutaneous ecchymosis, groin swelling, access site pain, vessel thrombosis and new femoral bruit.

### *Vascular imaging*

DCFI was routinely performed in all patients with the Acuson computed color Doppler sonography system (Acuson 128, Acuson Corporation, Mountain View, Canada) employing the 7.5 MHz linear phased-array transducer. The greatest diameter and the site of the peripheral vascular complications were recorded. An echo-free mass with no communication with the vascular structures was considered to be a hematoma. Pseudoaneurysm was identified as an extravascular hypoechoic cavity communicating with the femoral artery by a sinus tract, displaying "to and fro" signal on pulsed Doppler examination (Figure 1a). AV fistula was character-

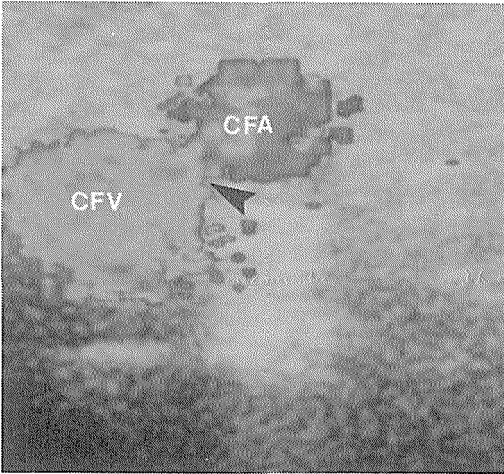


**Figure 1a.** A longitudinal color and pulsed Doppler image of the pseudoaneurysm (PA) at the ventral aspect of the superficial femoral artery (SFA) showing the cavity communicating with the artery by a sinus tract (arrow), and characteristic "to and fro" waveform.

ized by demonstrating a communication between the femoral artery and vein with a unidirectional continuous AV shunt representing typically, high diastolic flow in the arterial waveform proximal to the fistula and increased turbulent flow with arterial pulsation in the draining vein (Figure 1b).

### *Clinical data*

The recorded baseline clinical variables included patient age, gender, height, weight, body mass index (BMI), pulse pressure during catheterization, risk factors for atherosclerotic disease and the presence of femoral and aorto-iliac artery disease. The procedural parameters included the type of cath-



**Figure 1b.** A transverse color and pulsed Doppler image of the AV fistula between the common femoral artery (CFA) and the common femoral vein (CFV) showing a communicating channel (arrow), and continuous, unidirectional, turbulent waveform.

eterization procedure, the size of indwelling vascular sheaths, the number of consecutive ipsilateral punctures, and the length of bed rest prior to ambulating. The amount of heparin administered during and after the procedure was also documented.

*Statistics*

Numeric continuous data were analyzed as the mean ±1 SD, and categorical parameters were expressed as proportions. Differences in the distribution of selected characteristics between patients with DCFI-detected vascular complications and those without them were examined by the two-tailed Student t-test

and the Chi-square test for continuous and categorical variables, respectively. Univariate logistic regression was then performed to identify individual factors predicting the likelihood of vascular complications. Statistical significance was defined as a p value <0.05. All analyses were performed with the SPSS release 6.0 statistical package.

**Results**

*Diagnosis*

In 42 consecutive patients undergoing diagnostic coronary arteriography or PCI no major FASC, such as severe groin/abdominal hemorrhage, access site infection, sepsis or limb loss were observed. Abnormal physical and ultrasound findings were observed in 11 (26.2 %) and 15 (35.7 %) patients, respectively (Table 1a). In 11 patients clinically suspected of having FASC, 7 hematomas, 1 pseudoaneurysm, and 3 AV fistulas were confirmed by DCFI. 4 (9.5 %) additional patients with no local signs of FASC were found to have a significant vascular pathology on routine DCFI examination. One from 8 hematomas (12.5 %), 2 from 3 pseudoaneurysms (66.6 %), and 1 of 4 AV fistulas (25.0 %) would be missed solely on clinical grounds.

*Clinical assessment*

Physical findings at the access site in 15 patients with the DCFI-confirmed FASC are detailed in Table 1b. In patients with large groin swelling measuring ≥7 cm, DFCI revealed 4 hematomas, but 1 pseudoaneurysm and 1 AV fistula. Though femoral

**Table 1a.** Clinical and DCFI findings in patients following diagnostic coronary arteriography (Group A) and PCI (Group B).

Patients	Swelling ≥ 7 cm	New bruit	Hematoma	Pseudoaneurysm	AV fistula
Group A (n = 22)	4 patients (18.2 %)	2 patients (9.1 %)	4 patients (20.0 %)	1 patient (4.5 %)	1 patient (4.5 %)
Group B (n = 20)	2 patients (10.0 %)	3 patients (15.0 %)	4 patients (18.2 %)	2 patients (10.0 %)	3 patients (15.0 %)
Total (n = 42)	6 patients (14 %)	5 patients (12 %)	8 patients (19.0 %)	3 patients (7.1 %)	4 patients (9.5 %)

**Table 1b.** Physical findings at the access site in 15 patients with DCFI-confirmed diagnosis of femoral artery injury following diagnostic coronary arteriography or PCI.

Patients (n=15)	Hematoma	Pseudoaneurysm	AV fistula
Ecchymosis	6/8 patients	1/3 patient	0/4 patient
Groin swelling	4/8 patients	1/3 patient	1/4 patient
Pulsation	0/8 patient	1/3 patient	0/4 patient
Tenderness	8/8 patients	3/3 patients	4/4 patients
New bruit	1/8 patients	1/3 patient	3/4 patients

arterial pulsations were transmitted from the femoral artery in all patients, a more marked pulsation that extended over the femoral artery boundaries was observed in only 1 patient with pseudoaneurysm. New bruits were detected in both patients with pseudoaneurysm (33.3 %) and AV fistula (35.0 %), but they were also recorded in 1 (12.5 %) patient with hematoma. The bruit associated with a pseudoaneurysm was systolic in nature; on the other hand, the bruits present in patients with AV fistula were described as continuous in 2 patients, and as "long-systolic" in 1 patient. Subcutaneous ecchymosis was associated with hematoma in 6, and with pseudoaneurysm in 1 patient. Mild to moderate tenderness at the local puncture site was present in all patients.

#### DCFI characteristics

A total of 15 FASC included 8 hematomas (53.3 %), 3 pseudoaneurysms (20.0 %) and 4 AV fistulas (26.6 %). Most of hematomas were graded as small and measured  $2.6 \pm 0.6$  cm in diameter. Pseudoaneurysms had an average dimension of  $2.5 \pm 0.5$  cm and were located within 1 cm from the involved arterial segment. 2 pseudoaneurysms occurred at the ventral aspect of the superficial femoral artery, and one at the dorsal aspect of the common femoral artery in close proximity to its bifurcation. AV fistulas were located in superficial femoral artery in 3 cases, and in the common femoral artery in 1 case. They were considered to be hemodynamically unimportant, since no signs of venous hypertension or

proximal arterial dilatation were observed during DCFI examination.

#### Risk factors

FASC were more likely to result from PCI as compared to diagnostic coronary angiography (45.0 % versus 27.2 %,  $p < 0.05$ ). A comparison of baseline and procedural variables between patients with DCFI-confirmed vascular complications and patients without complications are shown in Table 2. The studied groups did not differ as concerns sex, obesity, underlying predisposing risk factors and distribution of aorto-iliac artery disease. In both groups, blood coagulation tests before catheterization were within normal range. Pre-treatment with aspirin or dipyridamol did not influence the risk of FASC in this study. Among all patients, the strongest predictors of FASC were advanced age ( $p < 0.05$ ), the use of large-size indwelling sheaths ( $p < 0.01$ ) and higher dosage of heparin ( $p < 0.01$ ). Univariate logistic regression was used to identify the clinical and procedural factors predicting the likelihood of FASC (Table 3). A dose-dependent regimen of heparin administration remained a statistically significant risk factor in all entities. While advanced age significantly contribute to hematoma formation, the use of large-size sheaths predicted the likelihood of AV fistula formation.

#### Management

All peripheral vascular lesions were managed non-operatively. Transfusion of 3 U of blood was ad-

**Table 2.** DCFI confirmed FASC as a function of clinical and procedural characteristics in patients undergoing diagnostic coronary arteriography or PCI.

Characteristic	Complications (n = 15)	Controls (n = 27)	P
Age (years)	65.4±10.0	56.2±11.6	0.013
Age > 65 years	40.0 %	25.9 %	0.029
Male gender	66.6 %	59.2 %	NS
BMI (kg/ m <sup>2</sup> )	26.5 ±2.8	25.9 ±4.3	NS
Obesity (BMI >25 kg/m <sup>2</sup> )	40.0 %	37.0 %	NS
Hypertension	66.6 %	62.9 %	NS
Pulse pressure (mm Hg)	65.4 ±19.9	65.2 ±19.9	NS
Diabetes mellitus	3.3 %	7.4 %	NS
Hypercholesterolemia	53.3 %	48.1 %	NS
Current smoking	33.3 %	59.2 %	NS
Peripheral vascular disease	26.6 %	25.9 %	NS
Aspirin or dipyridamole before catheterization	80.0 %	85.1 %	NS
Heparin during catheterization (10.000 U vs 3.000 U)	73.3 %	29.6 %	0.006
Continuous heparin overnight (1000 U/h)	73.3 %	29.6 %	0.006
Sheath dimension (9 F vs 6 F)	66.6 %	33.3 %	0.005
Consecutive number of ipsilateral arterial puncture	2.1±1.8	1.8±1.2	NS

ministered to only 1 patient with moderate hemorrhage into the retroperitoneal space. Most hematomas resorbed within a few days or weeks, depending on their size. One pseudoaneurysm showed spontaneous resolution as documented by the follow-up DCFI. Two stable pseudoaneurysms were successfully treated by DCFI-guided external compression. All AV fistulas appeared hemodynamically unimportant and were followed-up closely by DCFI.

### Discussion

The reported incidence of FASC after diagnostic coronary arteriography varies widely, from less than 1% to as much as 20%.<sup>1-3, 7-10</sup> When PCI are included the figure is higher (6.1-24%), possibly owing to the introduction of new devices, increased anticoagulation and larger sheath size.<sup>4-6, 11</sup> Furthermore, owing to the difference in definition there is a wide discrepancy in the reported incidence of FASC, in particular those of hematoma (0.6-12.3%) and bleeding (0.1-20.0%).<sup>1, 4-6, 8</sup> Our 26.2% incidence of FASC detected clinically ranks among the highest reported rates. It was mostly contributed to small stable hematomas, that would be excluded in other studies. The incidence of pseudoaneurysms (2.3% clinical detection; 7.1% DCFI) compares favorably with previously reported (0.5-5.2% clinical detection; 5.8-9.0% DCFI).<sup>12, 13</sup> Our incidence of AV fistulas (7.1% clinical detection; 9.5% DCFI) was higher as compared to other studies (0.05-0.1% clinical detection, 0.3-5.2% DCFI)<sup>14, 15, 21</sup> and may be related to our common practice to perform the double-wall Seldinger technique and routine ipsilateral arterial and venous catheterization. However, in contrast to other reports, no major FASC, such as severe hemorrhage, access site infection, sepsis, limb loss or even death were observed in our study.

Our current methods for the detection of FASC included a routine clinical and DCFI examination. Clinically, FASC were suspected in 11 patients, but DCFI-confirmed in 15 patients. Four patients (9.5%) with significant vascular pathology would be missed

on clinical grounds alone. Accordingly, we believed that clinical examination alone is not sufficient in order to detect all FASC. Although several physical signs have been used to detect FASC, clinical examination alone may not reliably distinguish between different entities. The rate of diagnostic accuracy of any single physical sign detected in our study was low. In patients with groin swelling, DCFI revealed hematomas, as well as pseudoaneurysms and AV fistulas. Although pulsatility of the mass appeared to be suggestive of pseudoaneurysm, it was present in only one case. As expected, new bruits suggested both pseudoaneurysm and in AV fistula, but simple hematoma did also cause a bruit due to extrinsic compression of the neighboring artery. Furthermore, a quality of bruit did not reliably identify its etiology.

The early recognition and prompt treatment of unstable vascular lesions are necessary to prevent further morbidity.<sup>16, 24</sup> Apart from progressive expansion and pain no objective criteria exist that would prospectively identify those pseudoaneurysms that will rupture and those that will spontaneously thrombose.<sup>22, 23</sup> In the present study, two stable pseudoaneurysms were successfully treated by DCFI-guided manual compression. Thus, we obviated the need for surgical interventions, and prevented spontaneous rupture in those patients followed conservatively.

The incidence of FASC was significantly higher after PCI than after diagnostic coronary arteriography as confirmed previously.<sup>4, 6-8</sup> FASC were most closely associated with the use of large-diameter sheaths and higher amount of heparin administration. Significantly higher complication rate observed in patients of advanced age may be due to a somewhat delayed process of healing, and seems to implicate a rigidity and poor retractability of underlying vessels.

### Conclusion and future outlook

FASC occur frequently after PCI and can be easily identified by DCFI. Diagnosis based on clinical examination alone is rather inaccurate. An exact

**Table 3.** Univariate logistic regression for the identification of individual clinical and procedural factors predicting the likelihood of hematoma, pseudoaneurysm and AV fistula.

Characteristic	Hematoma	Pseudoaneurysm	AV fistula
Advanced age	p <0.03	NS	NS
Periprocedural regimen of heparin	p <0.05	p <0.04	p <0.02
Sheath dimension	NS	NS	p <0.04

diagnosis facilitates the choice of treatment and prevents further morbidity. Based on our initial experience, DCFI-guided compression seems to be a useful alternative to surgical closure of pseudoaneurysm. Risk factors, identified in our study include advanced age, large sheaths, and large amount of heparin administration. Monitoring of adjunctive anticoagulant therapy, and careful patients selection may reduce the morbidity and increase the safety of these procedures. It seems advisable to use a single-wall puncture technique, to avoid routine venous puncture, and to alternate the access site with repeat catheterization. As indicated by our study, meticulous attention to catheterization details will minimize complications related to the access, while early detection and management will reduce the morbidity associated to complications.

### References

- Gwost J, Stoebé T, Chesler E, Weir EK. Complications of coronary arteriography from the collaborative study of coronary artery surgery (CASS). *Circulation* 1979; **59**: 1105–11.
- Skillman JJ, Kim D, Baim DS. Vascular complications of percutaneous femoral cardiac interventions. *Arch Surg* 1988; **123**: 1207–12.
- Babu SC, Picorellil GO, Shash PM, Stein JH, Clauss RH. Incidence and results of arterial complications among 16,350 patients undergoing cardiac catheterization. *J Vasc Surg* 1989; **10**: 113–6.
- Kaufman J, Moglia R, Lacy C, Dinerstein C, Moreyra A. Peripheral vascular complications from percutaneous transluminal angioplasty: A comparison with transfemoral cardiac catheterization. *Medical Sciences* 1989; **297**: 22–5.
- Oweida SW, Roubin GS, Smith RB, Salam AA. Post-catheterization vascular complications associated with percutaneous transluminal coronary angioplasty. *J Vasc Surg* 1990; **12**: 310–5.
- Muller DW, Podd J, Shamir KJ. Vascular access site complications in the era of complex interventions. *Circulation* 1992; **82**: 510.
- Mullet DW, Shamir KJ, Ellis SG, Topol EJ. Peripheral vascular complications after conventional and complex percutaneous coronary procedures. *Am J Cardiol* 1992; **69**: 63–8.
- Fransson SG, Nylander E. Vascular injury following cardiac catheterization, coronary angiography, and coronary angioplasty. *European Heart Journal* 1994; **15**: 232–5.
- Ricci MA, Trevisani GT, Pilcher DB. Vascular complications of catheterizations. *The American Journal of Surgery* 1994; **167**: 357–78.
- Bogart DB, Bogart M, Miller JT, Farrar MW, Barr K, Montgomery MA. Femoral artery catheterization complications: A study of 503 consecutive patients. *Cathet Cardiovasc Diagn* 1995; **34**: 8–13.
- Omoigui NA, Califf RM, Pieper K, Keller G, O'Hanesian MA, Berdan LG, Mark DB et al. Peripheral vascular complications in the coronary angioplasty versus excisional atherectomy trial (CAVET). *JACC* 1995; **26**: 922–30.
- Altin RS, Flicker S, Naidech HJ. Pseudoaneurysm and arteriovenous fistula after femoral artery catheterization: Association with low femoral punctures. *AJR* 1989; **152**: 629–31.
- Mitchell DG. Femoral artery pseudoaneurysm: diagnosis with conventional duplex and color Doppler US. *Radiology* 1987; **165**: 687–90.
- Heystren FMJ, Fast JH. Arteriovenous fistula as a complication of the Seldinger procedure of the femoral artery and vein. *Diagn Imag* 1983; **52**: 197–201.
- Thadani U, Pratt AE. Profunda femoral arteriovenous fistula after percutaneous arterial and venous catheterization. *Br Heart J* 1971; **33**: 803–5.
- Mills JL, Wiedman JE, Robinson JG, Hallet JW. Minimizing mortality and morbidity from iatrogenic arterial injuries: the need for early recognition and prompt repair. *J Vasc Surg* 1986; **4**: 22–7.
- Messina JL. Clinical characteristics and surgical management of vascular complications in patients undergoing cardiac catheterization. *J Vasc Surg* 1989; **13**: 593–600.
- Cohen GI, Chan KL. Physical examination and echo Doppler study in the assessment of femoral arterial complications following cardiac catheterization. *Cathet Cardiovasc Diagn* 1990; **21**: 137–43.
- Reneman RS. Cardiovascular applications of multi-gate pulsed Doppler systems. *Ultrasound in Med and Biol* 1986; **12**: 357–70.
- Coughlin BF, Pausther DM. Peripheral pseudoaneurysm: evaluation with duplex US. *Radiology* 1988; **168**: 339–42.
- Igildbashian VN, Mitchell DG, Middleton WD, Schwartz RA, Goldberg B. Iatrogenic femoral arteriovenous fistula: diagnosis with color Doppler imaging. *Radiology* 1989; **170**: 749–51.
- Mitchell DG. Femoral artery pseudoaneurysm: diagnosis with conventional duplex and color Doppler US. *Radiology* 1987; **165**: 687–90.
- Sheikh KH. Utility of Doppler color flow imaging for identification of femoral arterial complications of cardiac catheterization. *Am Heart J* 1989; **117**: 623–8.
- Kirsh JD, Reading CC, Charboneau W. Ultrasound-guided compression and repair of postangiographic femoral arteriovenous fistulas. *Mayo Clin Proc* 1993; **68**: 612–3.