

Transesophageal echocardiography – a new diagnostic method in cardiology

Mirta Koželj

Department of Cardiovascular Disease, University Medical Centre, Ljubljana, Slovenia

Transesophageal echocardiography (TEE) is a rapidly expanding diagnostic procedure in cardiology. Limitations of transthoracic approach caused by pulmonary emphysema, obesity, thoracic deformation and dyspnea have been overcome by using the transesophageal approach. TEE has a higher resolution, because higher frequency transducers can be used and there is no thorax interposition between the heart and transducer. There are strong and relative indications for this procedure. The TEE examination is a safe method and has very limited contraindications.

Key words: echocardiography transesophageal, diagnostic method, cardiology

Introduction

After the introduction of echocardiography, it soon became apparent that scanning of the heart is sometimes hindered by inadequate penetration of ultrasound through the thoracic wall and ribcage. This stimulated many investigators to search for alternative approach. Within only a few years, transesophageal echocardiography (TEE) has become established as an important new imaging technique in cardiology. TEE has opened a unique »new window« to the heart. The immediate proximity of oesophagus and the posterior heart permits exceptionally high resolution images, particularly of the left atrium, mitral valve, and interatrial septum,

and thoracic aorta. Additionally, from the stomach, the ventricles can be dependably imaged.

Technological developments and current TEE probes

The technique of TEE imaging was first introduced on an experimental basis in the late 1970s.¹ Since then, rapid advances in ultrasound technology have greatly changed the practice of TEE imaging. Miniaturisation of transducers size, the development of phased array systems housed in flexible endoscopes, and the ability to perform pulsed and colour Doppler flow imaging have made TEE a valuable diagnostic tool.^{2,3} Until recently, transesophageal endoscopes have had a single set of transducer elements attached to the probe tip. Using this transducer, images are acquired in serial transverse imaging planes. Recently Omoto et al.⁴ have introduced a biplane transesophageal pro-

Correspondence to: Mirta Koželj, MD, PhD, Department of Cardiovascular Disease, University Medical Centre, Zaloška 7, 61000 Ljubljana, Slovenia. Phone: + 386 61 317 057. Fax: + 386 302 455.

UDC: 616.12-073:534-8

be. Two phased-array transducers, one imaging in transverse and one in longitudinal planes, are mounted side-by-side at the tip of the gastroscope. This additional sagittal plane transducer allow imaging of the heart in two orthogonal planes, and enable a more complete biplane examination of cardiac and aortic anatomy. Much more sophisticated systems operate with multiplane probes, which allow to observe the heart in even multiple sections.

The basic construction of all transesophageal transducers is similar. A commercially available gastroscope is adapted by fitting a phased-array transducer at its tip for imaging in the transverse axis. The fiberoptics, together with the channels used for suction and biopsy, are removed to provide space for electronic connections for the transducer, but normal guidance controls are retained (Figure 1). The probes have the capacity for two-dimensional imaging at 5 to 7 MHz and 3.5 MHz for Doppler sampling.

TEE echocardiography is presently utilised in two environments: intraoperatively and for outpatient examinations. Intraoperatively, TEE is utilised to monitor cardiac function and detect intracardiac air or debris, to diagnose or quantify cardiac pathology and to assess operative results.

Patient preparation for TEE examination

TEE is unpleasant for most patients. Prior to the TEE examination, the possibility of gastroesophageal disease must be excluded, specifically oesophageal varices, diverticula, spasm and strictures, and intraesophageal masses. To prevent aspiration the patient should abstain from all oral intake for at least 4 hours, and during the introduction and examination the patient lies in the left decubitus position. Antibiotic prophylaxis is recommended only for a group of patients at high risk of infectious endocarditis such as those with prosthetic heart valves, severe native mitral regurgitation, and congenital heart disease.⁵ Choice of anti microbial agent is made in accordance with the guidelines of the American Heart Association.⁶

Lidocain spray is given for local anaesthesia to all patients. In our experience other premedication is not necessary. We perform TEE with sedatives and spasmolytics only in patients, in whom the aortic dissection is suspected. The patient is asked to swallow and the probe is advanced into the oesophagus with the aid of gentle pressure. Under no circumstances should oesophageal intubation be attempted against resistance. For the unconscious for example at intraoperative TEE, anaesthetised patients, no preparations are needed other than those for the operative procedure itself. The TEE probe is introduced into the oesophagus following of anaesthesia.

TEE: anatomic correlations

A comprehensive transesophageal examination entails a sequence of transducer positions and tomographic planes of sections. A step-by step approach that can be altered on the basis of the clinical situation is suggested. During TEE, two distinct tomographic examinations are performed – namely, that of the heart and that of the thoracic aorta.

Complete TEE imaging of the heart is performed from transducer locations in the stomach and various levels of the oesophagus. Views from the distal and proximal fundus of the stomach, gastroesophageal junction, lower and




Figure 1. Biplane probe (5 MHz). Note dual cables and connectors (“vertical, horizontal”) for two transducers.

middle oesophagus, and upper oesophagus are included in a standard TEE study of the heart. Although these locations serve as a general guide, the exact location of the transducer should be guided by the acquired image and not by the position in the stomach or oesophagus. If the probe is rotated anticlockwise, all of the thoracic descending aorta can be visualised adjacent to the transducer.⁷

The main clinical indications for a TEE study in adults

The oesophagus is adjacent to the left atrium and descending aorta. The high resolution and the shorter distance to the transducer make possible high quality images of the left atrium, mitral valve, interatrial septum and aortic valve. Flow patterns in the heart can be studied in detail. With transthoracic echocardiography, shielding of the left atrium by prosthetic valves often prevents evaluations of insufficiencies. TEE with colour flow Doppler provides magnificent evaluation of (para) valvular mitral insufficiency. Biplane TEE provides better evaluation of all cardiac valves and of valve insufficiencies in the longitudinal sections. Longitudinal sections are superior for the evaluation of the right ventricular outflow tract. With TEE, the interatrial septum is about perpendicular to the transducer and also the detection of a very small atrial septal defect is easy now. A different and often better evaluation of the aortic valve and right atrium is possible with TEE.

Major indications for ambulatory (outpatient and inpatient) TEE include defining the aetiology and severity of native valve disease, especially mitral regurgitation; detecting vegetations and other sequels of endocarditis (Figure 2); assessing prosthetic valve function and regurgitation; and identifying a potential cardiac embolic source (Figure 3). TEE has been shown to be an excellent method for detecting atrial septal defects, atrial septal aneurysm (Figure 4), and patent foramen ovale. In regard to cardiac tumours, although the data are preliminary, certain tumour locations and morphologic

aspects are better evaluated with TEE than with other techniques. Important advantages of TEE over transthoracic echocardiography are the high resolution images of cardiac cavities for tumour location and the visualisation of the

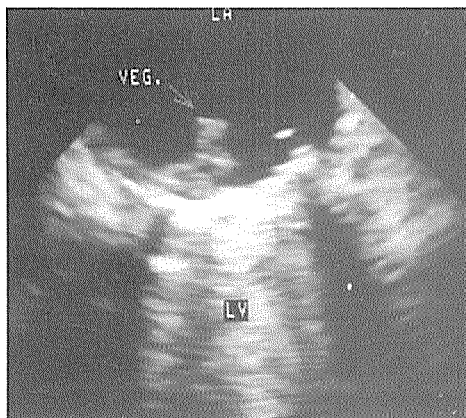


Figure 2. Transesophageal echocardiogram at the level of the left atrioventricular junction. A bilcaflet prosthetic valve is in mitral position, which casts a shadow within the left ventricle (LV). There is a vegetation (arrow) of the left atrial side of the prosthesis. LA = left atrium. The vegetation was not seen at transthoracic study because of shadowing of mitral prosthesis in the left atrium.

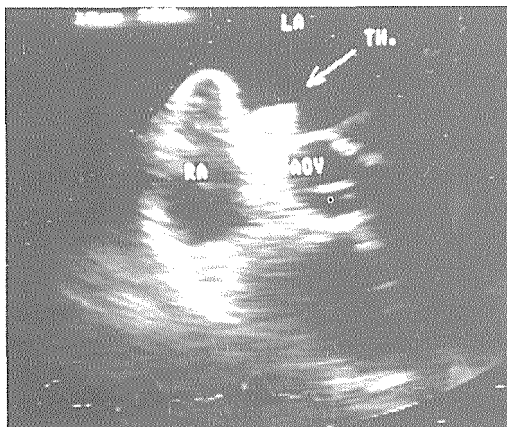


Figure 3. Transesophageal transverse-axis image in a patient with dilative cardiomyopathy. A large thrombus (TH) attached at interatrial septum is clearly visible (arrow). On the precordial image no definite structure could be visualised. LA = left atrium, RA = right atrium, AOV = aortic valve.

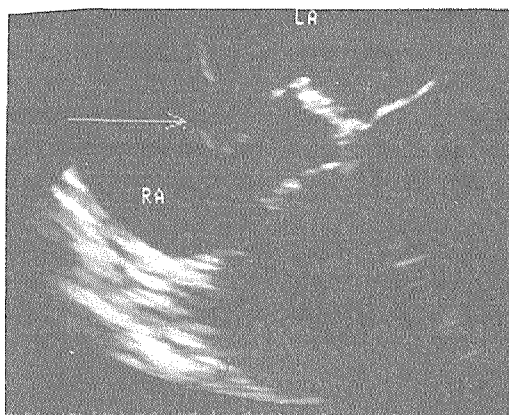


Figure 4. Transesophageal image of an atrial septal aneurysm (arrow). LA = left atrium, RA = right atrium.

myocardial wall and great veins for recognition of impingement, containment, migration and infiltration of diverse tumours types.⁸

A new field in ultrasound diagnosis is the thoracic aorta. Good information about the presence of dissection and plaques can be obtained (Figure 5). The true and false lumen can be distinguished with colour flow Doppler. The aortic arch and ascending aorta are not always visible because of interposition of trachea.

TEE is of limited value in the evaluation of lesions within the coronary arteries. Even where the quality of the images is excellent, only limited segments of the proximal vessels can be visualised. It is our opinion that the only practical value is in the identification of left main coronary stenosis or the involvement of coronary arteries in dissection of ascending aorta.

Safety and complications of TEE

Clear indications for TEE are necessary because side effects are rare but can be harmful. The complications include intolerance of the procedure, bronchospasm, spasm of oesophagus, vomiting, cardiac rhythm disturbances, angina, pharyngeal bleeding. The ECG monitoring is mandatory during the procedure. Nevertheless

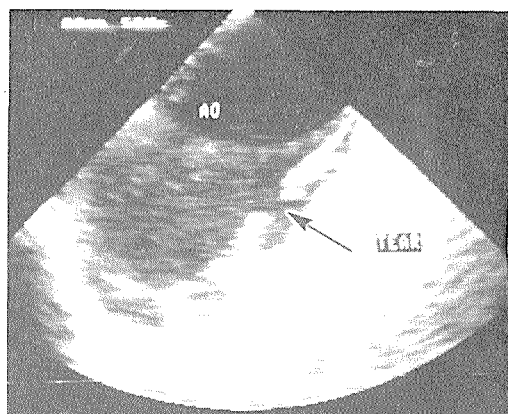


Figure 5. Cross-sectional transesophageal image of the aortic arch (AO) in a patient with acute dissection. The arrow shows the intimal tear. The color flow Doppler study confirms the flow at this site. Subsequent surgical inspection confirmed that this was the site of an intimal tear.

a careful history concerning upper gastrointestinal problems should be taken before TEE study.⁹

Conclusion

TEE has indeed opened a new and exciting window to the heart. TEE has now become a logical extension of a complete transthoracic echocardiographic examination. Predictable high-quality images obtained from the transesophageal examination have fostered wide application of this new technology. With newer multiplanar scanning devices becoming available, whole sets or families of short- and long-axis and four chamber views of the heart will be obtained.

References

1. Frazin L, Talano J, Stephanides L, Loeb HS, Kopel L, Gunnar RM. Oesophageal echocardiography. *Circulation* 1976; **54**: 102-8.
2. Hisanaga H, Hisanaga A, Nagata K, Ichie Y. Transesophageal cross-sectional echocardiography. *Am Heart J* 1980; **100**: 605-9.

3. Hisanaga H, Hisanaga A, Nagata K, Yoshida S. A new transesophageal real-time twodimensional echocardiographic system using a flexible tube and its clinical application. *Proc Jpn Soc Of Ultrasonics in Med* 1977; **32**: 43-4.
4. Omoto R, Kyo S, Matsumura M. Recent technological progress in transesophageal colour Doppler flow imaging with special reference to newly developed biplane and paediatric probes. In: Erbel R, Khanheria, Brennecke R, Meyer J, Seward JB, Tajik AJ eds. *Transesophageal echocardiography. A new window to the heart*. Heidelberg, Berlin: Springer-Verlag, 1989: 21-6.
5. Foster E, Redberg RF, Schiller NB. Transesophageal echocardiography. Indications and technical considerations: In: Schiller NB, Foster E, Redberg RF eds. *Transesophageal echocardiography. Cardiology Clinics*. 1993; **11**: 355-60.
6. Dajani AS, Bisno AL, Chung KJ, Durack DT, Freed M, Gerber MA. Prevention of bacterial endocarditis. Recommendations by The American Heart Association. *JAMA* 1990; **264**: 2919-22.
7. Schneider AT, Hsu TL, Schwartz SL, Pandian NG. Single, biplane, multiplane, and three dimensional transesophageal echocardiography. Echocardiographic-Anatomic correlations. In: Schiller NB, Foster E, Redberg RF eds. *Transesophageal echocardiography. Cardiology Clinics*. 1993; **11**: 361-87.
8. Seward JB. Cardiac tumours and thrombus: transesophageal echocardiographic experience. In: Erbel R, Khanheria, Brennecke R, Meyer J, Seward JB, Tajik AJ eds. *Transesophageal echocardiography. A new window to the heart*. Heidelberg, Berlin: Springer-Verlag, 1989: 120-8.
9. Fraser AG, Anderson RH. The normal examination: technique, imaging planes, and anatomical features. In: Sutherland GR, Roeland JRTC, Fraser AG, Anderson RH eds. *Transesophageal echocardiography in clinical practice*. Gower Medical Publishing, 1991: 3.1-3.32.