

## Electrochemotherapy with bleomycin. The first clinical experience in malignant melanoma patients

Zvonimir Rudolf,<sup>1</sup> Borut Štabuc,<sup>1</sup> Maja Čemažar,<sup>1</sup> Damijan Miklavčič,<sup>2</sup>  
Lojze Vodovnik<sup>2</sup> and Gregor Serša<sup>1</sup>

<sup>1</sup> Institute of Oncology, Ljubljana,<sup>2</sup> Faculty of Electrical and Computer Engineering,  
University of Ljubljana, Slovenia

---

*Electrochemotherapy offers a new approach to increase chemotherapeutic drug delivery. Exposure of cells or tissues to electric pulses potentiates the antitumor effectiveness of bleomycin and cisplatin, as demonstrated in vitro and in vivo on murine tumor models and in clinical trials in head and neck carcinoma patients. To determine the antitumor effectiveness of electrochemotherapy with bleomycin in malignant melanoma patients, cutaneous and subcutaneous tumor nodules were treated with electric pulses after intravenous administration of bleomycin. Nodules of various sizes were treated with single or multiple treatment. Also, antitumor effectiveness of electrochemotherapy with bleomycin was evaluated after several runs of electrochemotherapy treatment in the same patient with an interval of at least three weeks. The treatment effect was not dependent only on the tumor size, but also on the even distribution of the electric field for electropermeabilization of the nodules. Therefore, nodules which were treated either with a single or several runs of electric pulses, and were completely covered by the treatment, regressed within two to three weeks after therapy. Electrochemotherapy was equally effective in the same patient when it was repeated after a three weeks interval. In reported 2 malignant melanoma patients complete response was achieved in 22 out of 24 nodules treated. The preliminary results demonstrate that electrochemotherapy with bleomycin is effective in eradicating cutaneous and subcutaneous tumor lesions of malignant melanoma. Therefore, electrochemotherapy with bleomycin offers a successful approach to the treatment of cutaneous and subcutaneous tumor lesions in patients, without side effects and with high response rate. The treatment is applicable in nodules of varying sizes, since the nodules can be treated with multiple electric pulses to cover the whole tumor area and electrochemotherapy can be safely repeated several times.*

*Key words: melanoma-therapy; bleomycin; electric stimulation therapy*

---

### Introduction

Correspondence to: Gregor Serša Ph.D., Institute of Oncology, Department of Tumor Biology, Zaloška 2; 61105 Ljubljana, Slovenia. Tel: + 386 61 323 063 ext. 29 33, Fax: + 386 61 131 41 80.

In cancer treatment electrochemotherapy utilizes electric pulses to potentiate delivery of chemotherapeutic drugs into cells. Exposure of cells or tissues to short intense electric pulses increases permeability of plasma membrane without impairing cell viability. This nonselec-

tive plasma membrane permeabilization enables drugs to diffuse into the cells and reach their intracellular targets.<sup>1-7</sup>

Antitumor effectiveness of electrochemotherapy was extensively studied in murine tumor models using bleomycin or cisplatin as chemotherapeutic drugs.<sup>8-17</sup> In these studies it has been demonstrated that for an effective antitumor action of electrochemotherapy very low drug concentration is needed, which is ineffective when used without electric pulses.<sup>8-17</sup> The chemotherapeutic drug can be given either systemically or locally, thus providing many possibilities of clinical application.<sup>15,17,18</sup>

The first reports on antitumor effectiveness of electrochemotherapy in patients have already been published. In head and neck squamous cell carcinoma patients it was demonstrated that the treatment with bleomycin (10 mg/m<sup>2</sup>) followed by four or eight short intense electric pulses (100 μs, 1300 V/cm, frequency 1 Hz) administered through two external electrodes located on each side of the treated nodule was well tolerated. Objective responses were obtained in a majority of the 40 treated nodules (72%) with 57% complete response rate.<sup>19</sup>

The aim of our study was to determine antitumor effectiveness of electrochemotherapy with bleomycin in malignant melanoma patients with terminal disease. In the study cutaneous and subcutaneous malignant melanoma nodules of various sizes were treated with single or multiple electrochemotherapy treatments. Also, the antitumor effectiveness of electrochemotherapy with bleomycin was evaluated after several runs of treatment in the same patient.

In this preliminary communication we report 2 cases with repeated treatment for cutaneous and subcutaneous metastases of malignant melanoma.

## Patients and methods

### *Patient description*

**Patient 1:** The female patient, born in 1968 (H.F.No.: 731/92), had a nevus on her right thigh removed 6 months after her first child-

birth, i.e. in October 1991, because during pregnancy, it grew bigger and became hemorrhagic. Histological examination after radical removal revealed a nodular type of melanoma, Breslow 2.1 mm, Clark V. Due to the metastases of the melanoma in the inguinal lymph nodes on the right, a radical inguinal dissection was carried out in December 1991. After the operation, the patient was treated with human leukocyte interferon alpha given in 2 MU doses once a week for 6 months.

In April 1993, a number of skin metastases were detected on the gluteal part of the right thigh as well as in two inguinal lymph nodes on the right. The metastatic nodes in the inguino-femoral region and two skin metastases of melanoma origin on the right thigh were removed by surgery. In June 1993, after the third of total five cycles of chemo-immunotherapy with vinblastine (4 mg/m<sup>2</sup> intravenous (i.v.) on day 1), lomustine (60 mg/m<sup>2</sup> per os on day 1), cisplatin (20 mg/m<sup>2</sup> given in a two-hour infusion on days 2-5) and interferon alpha-2b (6 MU subcutaneously on days 3-7), a complete response of the skin metastases in the right gluteal region was established.

In March 1994, chemotherapy with dacarbazine (400 mg/m<sup>2</sup> i.v. on days 1-5) was applied due to recurrent melanoma growth on the skin and in the inguinal and retroperitoneal lymph nodes. The four-month treatment resulted in a complete response of skin metastases, whereas a partial response was noted in the inguinal and retroperitoneal lymph nodes.

Four months after completed therapy, skin metastases of melanoma were cytologically confirmed in the right gluteo-femoral region extending over a 30 x 20 cm surface. The inguinal and retroperitoneal lymph glands were not found to have enlarged since the previous examination. US and CT examinations failed to detect metastases in the visceral organs. Performance status by Karnofsky scale was 100. The total blood count and chemistry were within normal limits.

**Patient 2:** The patient, born in 1951 (H.F.No.: 2721/92), was operated on in January 1992 in order to have a rapidly growing pigmen-

ted nevus on the left thigh removed. Histological examination after radical removal revealed a nodular type of melanoma, Breslow 3.9 mm, Clark III. In July 1992, a radical inguino-femoral dissection of the lymph nodes on the left was carried out because of cytologically confirmed melanoma metastases in the inguinal lymph nodes. After surgery, the patient was receiving human leukocyte interferon alpha, 2 MU once weekly for 2 months. During the treatment with human leukocyte interferon alpha, a number of skin metastases emerged on the left thigh. In October 1992, the patient received radiotherapy for the skin metastases on the left thigh and was simultaneously also treated by chemo-immunotherapy with dacarbazine (interferon alpha-2b days 1-4, 3 MU daily; and dacarbazine 800 mg/m<sup>2</sup> on day 5 i.v. bolus repeated every three weeks). Altogether, the patient had undergone four treatment cycles. In January 1993, a complete response of the skin metastases was observed in the irradiated area whereas further progression of metastases was noted in the area outside the radiation field. Between January and July 1993, the skin metastases with the largest diameter not exceeding 5-15 mm were treated with several intratumoral applications of interferon alpha-2b. This treatment resulted in a complete response of all skin metastases, which was maintained until June 1994, when further progression of the disease was noted in the iliac lymph nodes on the left and in the inguinal lymph nodes bilaterally, together with the occurrence of skin metastases on the left thigh and shank, and pulmonary metastases. After three cycles of chemo-immunotherapy with dacarbazine and interferon alpha-2b a complete response of the pulmonary metastases was observed along with further progression of skin and lymph node metastases. The systemic treatment was therefore stopped and replaced with irradiation of the bilateral inguinal lymph node metastases. The patient received daily dose of 600 cGy twice a week to an irradiation field of 9 x 13 cm; left and right inguinal lymph node sites were irradiated with a total dose of 3000 cGy each.

Before electrochemotherapy treatment of skin metastases, the patient's performance status by Karnofsky scale was 60; several subcutaneous metastases with the largest diameter ranging from 2 mm to 3 cm were noted on the left thigh and shank. The metastatic inguinal lymph nodes were enlarged on both sides. No melanoma metastases could be found in the lung and liver. The total blood count and chemistry were within the limits of normal values.

#### *Electrochemotherapy treatment*

Electrochemotherapy consisted of i.v. administration of bleomycin (Mack, Germany) followed by exposure of melanoma nodules to electric pulses. Bleomycin was administered i.v. in 30 seconds at the dose of 10 mg/m<sup>2</sup> regardless of the number of nodules treated. The interval between bleomycin administration and electric pulse application was 8 minutes. The nodules to be treated were sprayed few minutes before electric pulse application with xylocaine (Astra, Germany) in order to avoid pain. Square wave electric pulses of 100 µs, 910 V amplitude (1300 V/cm), frequency 1 Hz were delivered through two parallel stainless steel electrodes (distance 7 mm; width 7 mm; length 14 mm, with rounded tips) with an electropulsator Jouan GHT 1287 (Jouan, France). Electrical parameters were controlled using oscilloscope HM 205-3 (Hameg Instruments, Germany). Electric pulses were delivered in two trains of four pulses with one second interval, delivered in two perpendicular directions (4 + 4 configuration). Good contact between the electrodes and the skin was assured by means of conductive gel. When several nodules were treated in the same session electric pulses were delivered one after the other at the intervals of at least one minute. Large nodules were treated with several runs of electric pulses, administered in adjacent position in the way that the whole tumor area was covered.

#### *Follow up*

During the electrochemotherapy treatment patients were carefully monitored for evaluation

of treatment effects. After the treatment the patients remained in the outpatients clinic for two hours, when they were examined and released. As outpatients they were examined weekly and the treatment response was evaluated. Tumor nodules were measured with caliper and were photographed before and after the treatment. The therapeutic response of electrochemotherapy was scored according to WHO guidelines as progressive disease (PD) if tumors increased more than 20 % in size, no change (NC) if the tumors decreased in size less than 50 %, partial response (PR) if the tumors decreased more than 50 % and complete response (CR) if they became unpalpable.

## Results

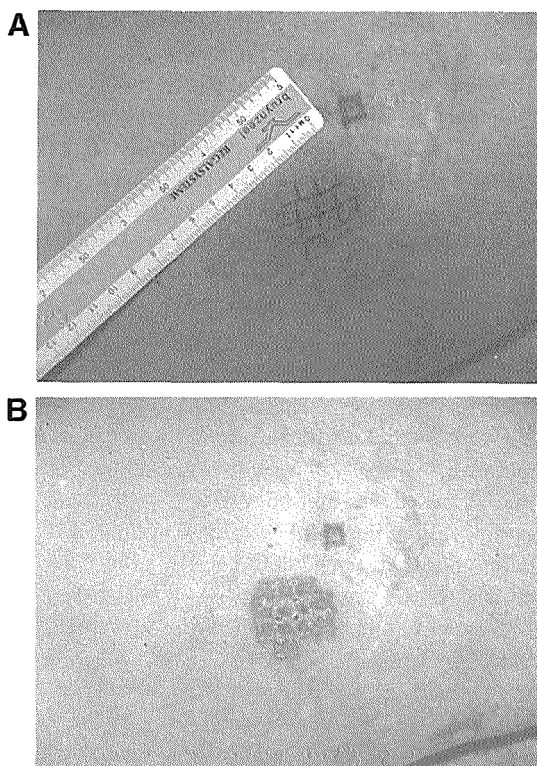
### Case reports

Patient 1 received bleomycin 10 mg/m<sup>2</sup> i.v. on December 6, 1994; 8 minutes later electric pulses were applied to two metastases measuring 5 x 5 x 3 mm (39 mm<sup>3</sup>) and 5 x 3 x 2 mm (16 mm<sup>3</sup>), respectively; another two lesions untreated by electric pulses served as controls. Both electrochemotherapy treated lesions underwent complete response after 14 days while the control lesions progressed. (Table 1, session A). Second electrochemotherapy session (Table 1, session B) was introduced on December 21, 1994 for a skin metastasis of 22 x 27 x 2 mm (622 mm<sup>3</sup>). Electric pulses were applied consecutively in 12 runs, administered in adjacent position, covering the whole tumor area. After 21 days a complete response of the treated skin metastases was confirmed, as illustrated in Figure 1A and B.

**Table 1.** Patient 1: electrochemotherapy conditions and effects.

Session	No. of treatments*	No. of nodules	Size of the treated nodules (mm <sup>3</sup> )		Response†
			Before treatment	- 4 weeks later	
A	none	1	39	188	PD
	none	1	9	56	PD
		1	39	0	CR
	1	1	16	0	CR
B	12	1	622	0	CR

\* treatment = application of 4 + 4 electric pulses + PD - progressive disease; CR - complete response



**Figure 1.** In patient 1 the smaller tumor nodule was treated with single application (4 + 4) of electric pulses in the first session. The marks where the electrodes were positioned are still visible (A). In the bigger tumor nodule the positions of the electrodes for the 12 treatments with electric pulses in 4 + 4 configuration were marked with ballpen. Three and five weeks after the first and the second electrochemotherapy session, both tumor nodules were in complete response (B). Electrode marks and superficial scabs on the bigger tumor nodule are clearly visible.

In January 1995, the patient was referred to irradiation of the central nervous system due to two inoperable brain metastases. Because of severe neurological symptoms and epilepsy, no further electrochemotherapy treatment of skin metastases was indicated or applied. The patient was maintained on symptomatic therapy until May 1995, when she died of brain edema due to further progression of brain metastases.

All electrochemotherapy treated metastases remained in complete response until the patient's death.

Patient 2 received bleomycin 10 mg/m<sup>2</sup> i.v. on October 24, 1994, 8 minutes later two metastases measuring 29 x 24 x 8 mm (2915 mm<sup>3</sup>)

and 16 x 11 x 5 mm (461 mm<sup>3</sup>), respectively, on the left thigh and shank were treated by electric pulses, while another metastasis measuring 18 x 13 x 5 mm (613 mm<sup>3</sup>) untreated by electric pulses served as a control (Table 2, session A). The control metastasis and smaller metastasis treated with electrochemotherapy progressed, while the bigger one underwent a decrease.

On November 28, 1994, after the application of bleomycin, 5 skin metastases on the left thigh and one on the left forearm, their largest diameters ranging from 4 to 15 mm, were treated with electric pulses (with tumor volumes 251, 88, 17, 17, 17 mm<sup>3</sup>, respectively). The biggest one (on the left thigh, 251 mm<sup>3</sup>) was treated with two runs of electric pulses, covering the whole tumor area. All the electrochemotherapy treated lesions underwent complete response (Table 2, session B).

On December 14, 1994, after the application of bleomycin, 13 skin metastases, with the largest diameters from 4 to 6 mm, on the back of the right thigh and on the right side of the thorax were treated with electric pulses (average tumor volume 20 mm<sup>3</sup>). All electrochemotherapy treated lesions underwent complete response (Table 2, session C).

In January 1995, there were metastases detected in the lung, liver, spleen, and in the retroperitoneal lymph nodes. The patient died of liver metastases in February 1995. When he died, all the metastases treated with electrochemotherapy on November 28 and De-

ember 14, 1994 were found to have regressed completely; the bigger of the two metastases treated on October 24, 1994 was in regression, whereas the smaller one was in progress.

### Side effects

There were no major local or general side effects noted. Muscle contractions were observed after each pulse. The contractions were instantaneous, disappearing immediately at the end of each pulse. Although the contractions were tolerable in treated regions, an unpleasant sensations described as a local pain or shock were reported by the patients. Several hours after treatment, the only noticeable effect was the occurrence of erythema and slight edema at the treated area. These symptoms disappeared in one day. Marks of the electrodes were visible for several weeks after the treatment. No significant changes in blood count and biochemistry were observed.

### Discussion and conclusion

The preliminary results of an on-going trial on malignant melanoma patients demonstrated that electrochemotherapy with bleomycin is effective in eradicating cutaneous and subcutaneous tumor lesions of malignant melanoma. In the two reported malignant melanoma patients complete response was achieved in 22 out of 24 nodules treated.

Our results support the outcome of the first clinical trial with electrochemotherapy with bleomycin of head and neck squamous cell carcinoma, where 57 % of the treated nodules were in complete response after the treatment.<sup>19</sup> The treatment protocol of our study on malignant melanoma and the study on squamous cell carcinoma are similar except some modifications. Melanoma patients with cutaneous and subcutaneous nodules were treated without general anesthesia, with electric pulses delivered in 4 + 4 configuration. Furthermore, treatment protocol was extended to several runs of electric pulses being applied to bigger tumor nodules, and repeated treatment with electrochemotherapy in the same patient with a few weeks interval.

**Table 2.** Patient 2: electrochemotherapy conditions and effects.

Session	No. of treatments*	No. of nodules	Size of the treated nodules (mm <sup>3</sup> )		Response <sup>†</sup>
			Before treatment	- 4 weeks later	
A	none	1	613	1253	PD
	4	1	2915	2027	NC
	1	1	461	785	PD
B	2	1	251	0	CR
	1	1	88	0	CR
	1	4	17	0	CR
C	1	13	20	0	CR

\* treatment = application of 4 + 4 electric pulses

<sup>†</sup>PD - progressive disease; NC - no change;

CR - complete response

As reported, antitumor effectiveness of electrochemotherapy was dependent on tumor size, the best response being noted in smaller nodules up to 20 mm<sup>3</sup> of volume. Nevertheless, it seems that the response is dependent also on the even distribution of the electric field for electropermeabilization of nodules, since bigger nodules that were treated with several runs of electric pulses completely covering the tumor area regressed within two to three weeks after treatment. Also, electrochemotherapy was equally effective in the same patient when it was repeated after a three-week interval. These first results demonstrate that electrochemotherapy is feasible as a local form of treatment since it does not cause significant side effects, either immediate or delayed. All the observed side effects appear to be reversible. A clear antitumor effect was observed in patients with disease resistant to conventional methods. Furthermore, electrochemotherapy could be safely repeated.

### Acknowledgement

This work was supported by the Ministry of Science and Technology of the Republic of Slovenia.

### References

- Melvik JE, Petterson EO, Gordon PB, Selgen PO. Increase in cis-dichlorodiammineplatinum (II) cytotoxicity upon reversible electropermeabilization of the plasma membrane in cultured human NHIK 3025 cells. *Eur J Cancer Clin Oncol* 1986; **22**: 1523-30.
- Nutt AK, Mansouri A, Henle KJ. Response of cisplatin resistant tumor cells to electroporation and cisplatin. *Proc Annu Meet Am Assoc Cancer Res* 1991; **32**: A2229.
- Rols MP, Teissie J. Electropermeabilization of mammalian cells. Quantitative analysis of the phenomenon. *Biophys J* 1990; **58**: 1089-98.
- Orlowski S, Mir LM. Cell electropermeabilization: a new tool for biochemical and pharmacological studies. *Biochim Biophys Acta* 1993; **1154**: 51-63.
- Orlowski S, Belehradek Jr J, Paoletti C, Mir LM. Transient electropermeabilization of cells in culture. Increase in cytotoxicity of anticancer drugs. *Biochem Pharmacol* 1988; **37**: 4727-33.
- Poddevin B, Orlowski S, Belehradek Jr J, Mir LM. Very high cytotoxicity of bleomycin introduced into the cytosol of cells in culture. *Biochem Pharmacol* 1991; **42**: S67-S75.
- Belehradek Jr J, Orlowski S, Ramirez LH, Pron G, Poddevin B, Mir LM. Electropermeabilization of cells in tissues assessed by the qualitative and quantitative electroloading by bleomycin. *Biochim Biophys Acta* 1994; **1190**: 155-63.
- Okino M, Mohri H. Effects of a high-voltage electrical impulse and an anticancer drug on in vivo growing tumors. *Jpn J Cancer Res* 1987; **78**: 1319-21.
- Mir LM, Orlowski S, Belehradek Jr J, Paoletti C. Electrochemotherapy potentiation of antitumor effect of bleomycin by local electric pulses. *Eur J Cancer* 1991; **27**: 68-72.
- Belehradek Jr J, Orlowski S, Poddevin B, Paoletti C, Mir LM. Electrochemotherapy of spontaneous mammary tumours in mice. *Eur J Cancer* 1991; **27**: 73-6.
- Okino M, Esato K. The effects of a single high voltage electrical stimulation with an anticancer drug on in vivo growing malignant tumors. *Jpn J Surg* 1990; **20**: 197-204.
- Salford LG, Persson BRR, Brun A, Ceberg CP, Kongstad PCh, Mir LM. A new brain tumor therapy combining bleomycin with in vivo electropermeabilization. *Biochem Biophys Res Co* 1993; **194**: 938-43.
- Heller R, Jaroszeski M, Leo-Messina J, Perrot R, Van Voorhis N, Reintgen D, Gilbert R. Treatment of B16 mouse melanoma with the combination of electropermeabilization and chemotherapy. *Bioelectrochem Bioenerg* 1995; **36**: 83-7.
- Serša G, Čemažar M, Miklavčič D, Mir LM. Electrochemotherapy: variable anti-tumor effect on different tumor models. *Bioelectrochem Bioenerg* 1994; **35**: 23-7.
- Čemažar M, Miklavčič D, Vodovnik L, Jarm T, Rudolf Z, Štabuc B, Čufer T, Serša G. Improved therapeutic effect of electrochemotherapy with cisplatin by intratumoral drug administration and changing of electrode orientation for electropermeabilization on EAT tumor model in mice. *Radiol Oncol* 1995; **29**: 121-7.
- Serša G, Čemažar M, Miklavčič D. Antitumor effectiveness of electrochemotherapy with cis-diamminedichloroplatinum(II) in mice. *Cancer Res* 1995; **55**: 3450-5.
- Heller R, Jaroszeski M, Leo-Messina J, Glass F, Perrot R, Van Voorhis N, Reintgen D, Gilbert R. Electropermeabilization/chemotherapy parameter examination for effective anti-tumor treatment. XIIth international symposium on bioelectrochemistry and bioenergetics, Sevilla 1994, Book of abstracts, OIII-3.

18. Mir LM, Orlowski S, Belchradek JJr, Tessie J, Rols MP, Serša G, Miklavčič D, Gilbert R, Heller R. Biomedical applications of electric pulses with special emphasis on antitumor electrochemotherapy. *Bioelectroch Bioenerg* 1995; **38**: 203-7.
19. Belchradek, M., Domenge, C., Luboinski, B., Orlowski, S., Belchradek, Jr. J., Mir, L. M. Electrochemotherapy, a new antitumor treatment. First clinical phase I-II trial. *Cancer* 1993; **72**: 3694-700.