

## Diagnosis and treatment of malignant mesothelioma of the peritoneum

Erika Brenčič,<sup>1</sup> Marjeta Stanovnik,<sup>2</sup> A. Višnar-Perović<sup>1</sup>

<sup>1</sup>Institute of Diagnostic and Interventional Radiology, Clinical Center, Ljubljana, <sup>2</sup>Institute of Oncology, Ljubljana, Slovenia

*Six patients with malignant mesothelioma of the peritoneum (MMP) diagnosed by US and CT between 1982 and 1992 are presented. MMP was suspected on the basis of diffuse changes in the peritoneum, omentum and mesenterium. The diagnosis was confirmed by cytological and histological examinations. The very suspicion of MMP based on US and CT alone, without the presence of typical symptoms, may shorten the time to definitive pathomorphological diagnosis.*

*All patients were treated by combined chemotherapy (ChT), whereas four also underwent surgery and irradiation (RT). Four patients have died and two are alive with disease. A relatively prolonged survival was achieved only in two patients receiving multimodal therapy; this was probably influenced by the patients' youth, good performance status at the beginning of therapy and prognostically favourable MMP subtype.*

*Key words:* mesothelioma, peritoneal neoplasms

### Introduction

Malignant mesothelioma of the peritoneum (MMP) is a rare primary malignant disease. The disease may affect the peritoneum, though its pleural invasion is more common.<sup>1,2</sup> Men exposed to a contact with asbestos are affected in a greater percentage. It can be expected that the expanding development of asbestos industry will result in an increased number of new cases of this disease. The latent period from the exposure to asbestos and the onset of disease

is known to be very long. The mechanism of asbestos action upon the peritoneum has not been explained yet.<sup>3</sup>

Symptoms of this disease show great diversity, ranging from colic pains to loss of body weight. Clinical examination may reveal ascites with or without palpable tumor masses.

The diagnosis of MMP is often established only after explorative laparotomy or on autopsy.

Classical radiological methods are insufficient as they can image different stages of changes in the intestinal mucosis, without actually being able to explain the organic cause of obstruction. The establishing of correct diagnosis is rendered very difficult as the disease closely resembles the clinical picture of abdominal carcinomatosis and carcinoid involvement.<sup>4,5</sup>

Correspondence to: Erika Brenčič, MD, PhD, Institute of Diagnostic and Interventional Radiology, Clinical Center, Zaloška c. 7, 61105 Ljubljana, Slovenia. Fax: + 38 61-13-10-44.

UDC: 616.381-006.32-07-08

US and CT are noninvasive diagnostic methods able to present small or diffuse peritoneal, omental and mesenterial changes, with exclusion of a metastatic involvement. US- and CT-guided aspiration biopsies for cytological examination help to provide fast and accurate diagnosis.<sup>6, 7, 8</sup>

Systemic or intraperitoneal (IP) ChT in combination with surgery or radiotherapy (RT) resulted in a prolonged survival in a selected group of patients.<sup>9, 10, 11</sup> According to the experiences of other centers<sup>9, 12</sup> longer survival can be attributed to the following factors: sex, early stage of disease, younger age, histological subtype of MMP and good performance status at the beginning of treatment.

### Materials and methods

In the period from 1982 to 1988, 51 patients with malignant mesothelioma were registered by the Cancer Registry of Slovenia at the Institute of Oncology in Ljubljana.<sup>13</sup>

The success of treatment and diagnosis was reviewed in 6 patients with MMP treated during the years 1982–1992 at the Institute of Oncology.

**Table 1.** Basic data on the six studied patients.

Pat. No.	Age Sex	Asbestos exposure	Mode of biopsy and finding	Site
1	32/M	possible	Biopsy on lapt. tubulopapillary MMP subtype	Peritoneum
2	49/M	yes	Biopsy on laps. epitheloid MMP subtype	Peritoneum
3	56/M	no	Aspir. biopsy of the inguin. lgl	Peritoneum, pleura, lung, inguin. lgl
4	27/M	no data	Biopsy on lapt. multicentric MMP subtype	Peritoneum inguin. lgl
5	56/M	yes	Aspir. biopsy of the ascites	Peritoneum
6	47/M	yes	Aspir. biopsy of the ascites	Peritoneum

Abbreviations: lapt. – laparotomy; laps. – laparoscopy

All patients were males in the mean age of 44 years. Exposure to asbestos was confirmed in 3 of 6 patients. In one patient such exposure was possible whereas in another one it was excluded. No data on possible exposure to asbestos were available for one patient (Table 1).

In Pat. 1 and Pat. 4 the histologic diagnosis was confirmed by biopsy on laparotomy, and in two patients by aspiration biopsy of the ascites. Pat. 3 underwent aspiration biopsy of the inguinal lymph nodes, whereas Pat. 2 had the diagnosis confirmed by biopsy on laparoscopy (Table 1).

Epithelial subtype of MMP was established in Pat. 1 and Pat. 2. Multicystic subtype of MMP was histologically confirmed in Pat. 4. In the remaining three patients aspiration biopsy failed to identify the histologic subtype. The diagnosis of MMP was confirmed by autopsy in all four deceased patients.

In five patients the initial CT examination was carried out at the time of diagnosis, whereas Pat. 1 had CT performed only on the follow up after the initial therapy.

CT examination was always performed with 5-sec. exposure time and 16mm distance between individual sections through the entire abdominal cavity. Intestinal loops were imaged by means of Gastrografin, a contrast medium for oral application. For exclusion of metastases, the results of investigations for the assessment of peritoneal, omental and mesenterial involvement, possible presence of ascites and changes in other organs were considered.

Separate CT examinations of the thorax were not performed, though the pleural space above the diaphragm was imaged in all patients.

Peritoneal involvement was found in all cases; in Pat. 3 and Pat. 4 the disease was present in the inguinal lymph nodes, whereas in the former patient pleural and pulmonary involvement was found as well (Table 1).

Debulking surgery was performed in Pats 1, 2, 4 and 5. Two patients were not subjected to surgery, one because of pulmonary and pleural dissemination, and the other because of numerous peritoneal tumor infiltrations (Table 2).

**Table 2.** Treatment sequence and outcome.

Pat. No.	Treatment sequence	No. of surg.	Interval(mos)		Outcome
			From dg to death	From compl. th to last follow-up	
1	lapt (bx)iv.ChT > RT > iv.ChT > lapt(ex) > ip.ChT > lapt > lapt	4	90	10	dead
2	laps(bx) > iv.ChT > RT	1	4	1	dead
3	iv.ChT	0	10	7	dead
4	lapt(deb) > iv.ChT > RT > iv.ChT	1	33	15	alive with disease
5	iv.ChT > lapt(deb) > iv.ChT > RT	1	21	11	dead
6	iv.ChT	0	5	–	alive with disease

Abbreviations:

lapt – laparotomy; laps – laparoscopy; iv.ChT – intravenous chemotherapy; ip.ChT – intraperitoneal chemotherapy; RT – radiotherapy; bx – biopsy; deb – debulking surgery; ex – explorative surgery; > – followed by

**Table 3.** No. of cycles, combination of drugs and irradiation.

Pat. No.	No. of cycles and drug. comb. iv.ChT	comb. ip.ChT	Abdom. RT TD-cGy	Fract. cGy	Duration (days)
1	11/ADM, CTX, CDDP 7/ADM, VP16, CDDP 6/CDDP, MIT, IFO	1/ADM CDDP	2.980	80/100	11/21
2	2/MIT, 5-FU	0	3.000	100	30
3	5/ADM, CTX, CDDP	0	0	0	0
4	6/ADM, CTX, CDDP 5/MIT, C	0	3.000 only pelvis	300	10
5	3/VLB 3/ADM, CTX, IFO	0	3.450	150	23
6	2/MIT, CDDP, VCR	0	0	0	0

Abbreviations:

ADM – doxorubicin, CTX – cyclophosphamide, CDDP – cis-platin, VP16 – etoposide, MIT – mitomycin, 5-FU – fluorouracil, C – carboplatin, VLB – vinblastine, VCR – vincristine, IFO – ifosfamide

All 6 patients were given a systemic chemotherapy (ChT). Pat. 1 received a single intraperitoneal (i. p.) application of ChT which was ineffective (Table 3).

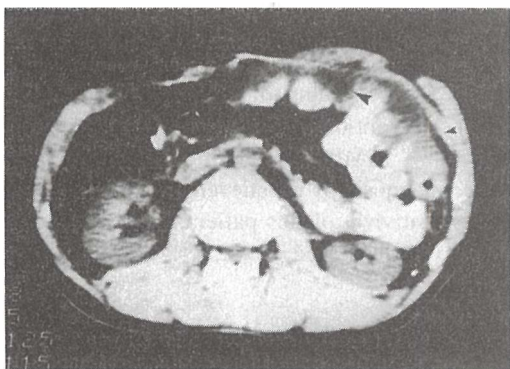
Different combinations of cytostatics and different numbers of cycles were used (Table 3).

Four patients were also irradiated. Three of these received TD 2980–3450 cGy to the whole abdomen, whereas in Pat. 4 the irradiation field was restricted to pelvis alone (Table 3).

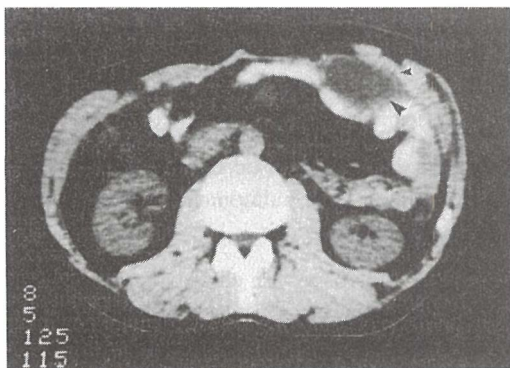
Follow up included chest X-ray, US, CT of the abdomen and cytologic examination of the ascites. US-guided aspiration biopsy was used in order to evaluate possible progression of the disease.

## Results

The initial CT examination revealed peritoneal involvement in 5 patients by imaging the thickening and irregular contours of the peritoneum. Pat. 1 had the initial CT performed only on the first follow-up examination after therapy. The thickened peritoneum found on that occasion (Figure 1) persisted throughout the follow-up of 90-month lasting course of disease. When comparing the results of all follow-up examinations, only the quantity of ascites was found to have varied. Tumor masses that appeared occasionally did not exceed 5 cm of size (Figure 2) and were located in different sites, most fre-



**Figure 1.** CT image of peritoneal thickening (small arrow), ascites, and minor tumors (big arrow).



**Figure 2.** CT image of a soft-tissue tumor (big arrow) situated between the intestinal loops and the abdominal wall; thickened peritoneum (small arrow).

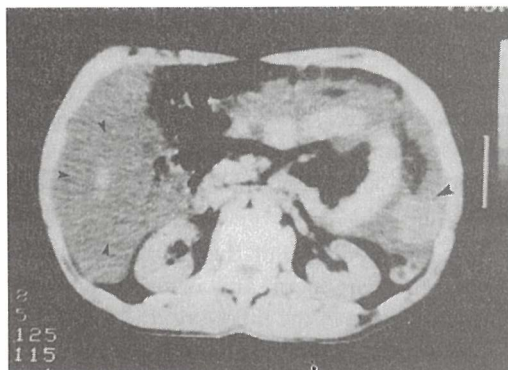
quently between intestinal loops. Associated with further progression of the disease, these tumors obstructed the intestinal loops and consequently caused the patient's death.

On the first examination in three patients tumors larger than 5 cm and the density of 20–30 HE were found. At that time, ascites was present in 5 patients, its density ranging between 10–20 HE (Figure 3). In five patients increased distance between the anterior abdominal wall and intestinal loops could be seen due to ascites and omental changes (Figure 4).

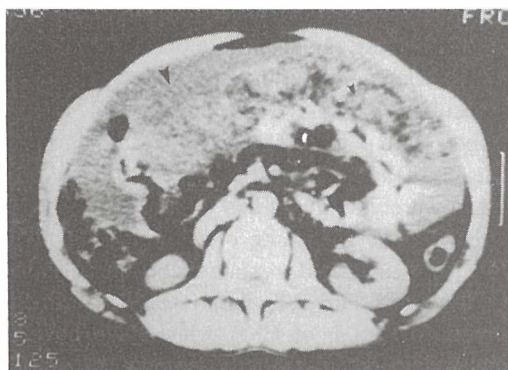
Thickened mesentery was found in all patients. In two of them this could be ascribed to the stellate mesenterial changes caused by the presence of small tumors and their consequential obstruction of blood supply. None of the

patients had any pleural outflow at the time of the first CT examination. Pat. 3 and Pat. 4 showed evidence of lymph node involvement (Table 1), whereas changes in the pleura and lung of Pat. 3 appeared soon after the beginning of therapy.

In Pat. 1 a combination of different treatment modalities (Table 3) resulted in a 90 month survival. The patient died because of progressing disease and ileus. Pat. 5 died 21 months after the diagnosis, despite the combined therapy. Only a short-lasting remission was achieved in 2 patients who survived 4 and 10 months respectively. Two patients are still alive, one of them with palpable tumors in the peritoneum and inguinal lymph nodes. His disease, however, shows tendency of stagnation, and the patient has been off the specific treatment for



**Figure 3.** CT image of a soft-tissue tumor (big arrow) and ascites (small arrow).



**Figure 4.** Ascites (big arrow) and changed omentum (small arrow) imaged on CT examination.



15 months already. The other patient had been receiving ChT for 5 months, but the only therapeutic effect achieved was a decrease of ascites (Table 3).

Toxic side effects after ChT and RT were moderate. No life-threatening adverse reactions occurred during therapy.

### Discussion

MMP can be successfully diagnosed by US and CT, when these are complemented with aspiration biopsy. The diagnosis or suspicion for MMP is based on the presence of ascites, and peritoneal, omental and mesenterial changes which can be imaged on CT. CT examination speeds up the diagnostic procedure and helps to provide the final diagnosis of MMP.

In some of our patients follow-up by means of CT was able to confirm the presence of disease (tumors and ascites) during therapy. In others, however, CT failed to evidence the disease, though microscopic peritoneal changes detectable only by aspiration biopsy might have been present.

Treatment results of the presented patients with MMP are poor and in agreement with those reported in the literature: the duration of survival is 2, 12 and 18 months after diagnosis.<sup>3, 8, 14</sup>

Patients with well differentiated papillary MMP and cystic form of MMP were found to have a longer survival even without treatment.<sup>14</sup>

Considering the small number of studied patients, the combined therapy in Pat. 1 and Pat. 4 resulted in 33 and 90 month survival, respectively. Both patients had prognostically favourable epithelial and multicentric MMP subtype. They were young and had a good performance status at the beginning of treatment. In both cases the combined treatment comprised debulking surgery and RT. Pat. 1 received a single i. p. application of ChT, which could not be continued owing to ileus. The patient died 90 months after the beginning of treatment. Pat. 4 has been without a specific therapy for 15

months, and is alive with evidence of disease 33 months after diagnosis.

At the beginning of treatment, Pat. 5 was over 40 years old, and had a residual tumor of unknown MMP subtype; he died 21 months after diagnosis. It is believed that the relatively longer survival of this patient could be attributed to undiagnosed, possibly favourable MMP subtype.

In two of six patients, short survival (4 and 10 months respectively) was due to their rapid course of disease. Combined therapy was ineffective also because of unfavourable prognostic factors at the beginning of therapy, though one of them had the epitheloid MMP subtype. Pat. 6 has been only receiving ChT for 5 months now.

It is interesting to note that one of the patients was not exposed to asbestos, and died with pleural and pulmonary involvement 10 months after diagnosis.

Owing to unspecific clinical symptoms and late establishment of correct diagnosis, the patients with MMP are generally admitted for treatment with highly advanced stages of the disease.<sup>3</sup> Therefore, the treatment intent is often limited to palliation.

In their study, though it was carried out on a smaller number of patients, Lederman et al. reported that a longer survival had been achieved by combined therapy.<sup>10, 11</sup> The survival of patients with combined radical therapy is longer than that of patients receiving palliative treatment only. Based on the correlation of our findings with the results of other studies,<sup>14</sup> we believe that MMP is possibly curable in patients with favourable prognostic factors.

Considering that this is a rare disease, the number of patients in individual studies is generally small. Though being rather low, the number of patients with longer survival points out the need for multicentric studies to be carried out, so that the optimum treatment for MMP could be determined on a larger population of patients.

## References

1. Haskell CM. *Cancer Treatment*, 3<sup>rd</sup> Edition, W. B. Company 1990; **188**: 300.
2. Suzuki Y. Pathology of Human Malignant Mesothelioma. *Seminars in Oncology* 1981; **81**: 268.
3. Plaus WJ. Peritoneal Mesothelioma. *Arch Surg* 1988; **123**: 763.
4. Whitley NO, Brenner DE, Antman KH, Grant D, Aisner J: CT of Peritoneal Mesothelioma. Analysis of Eight Cases. *AJR* 1982; **138**: 531.
5. Granke SD, Ellis JH, Richmond DB. CT Findings of Hypervascular Malignant Peritoneal Mesothelioma. *Computerized Radiol* 1987; **11**: 91.
6. Reuter K, Raptopoulos F, Krolikowski FJ, D'Orsi CJ, Graham S, Smith EH: Diagnosis of Peritoneal Mesothelioma. Computed Tomography, Sonography and Fine-needle Aspiration Biopsy. *AJR* 1983; **140**: 1189.
7. O'Neil JD, Ros PR, Storm BL, Buck JL, Wilkinson EJ. Cystic Mesothelioma of the Peritoneum. *Radiology* 1989; **170**: 333.
8. Pui-Li Y, Guico R, Parikh S, Chin S. Cystic Mesothelioma of the Retroperitoneum. *J Clin Ultrasound* 1992; **20**: 65.
9. Antman KH, Klegar KL, Pomfret EA, Osteen RT, Amato DA, Larson DA, Corson JM. Early Peritoneal Mesothelioma. A Treatable Malignancy. *Lancet* 1985; **2**: 977.
10. Lederman GS, Recht A, Herman T, Osteen R, Corson J, Antman KH. Long-term Survival in Peritoneal Mesothelioma. The Role of Radiotherapy and Combined Modality Treatment. *Cancer* 1987; **59**: 1882.
11. Lederman GS, Recht A, Herman T, Osteen R, Corson J, Antman KH: Combined Modality Treatment of Peritoneal Mesotheliomas. *NCI Monogr* 1988; **6**: 321.
12. Antman KH, Shemin R, Ryan L, Klegar K, Osteen R, Herman T, Lederman G, Corson J. Malignant Mesothelioma. Prognostic Variables in a Registry of 180 Patients, the Dana-Farber Cancer Institute and Brigham and Women's Hospital Experience over Two Decades, 1965-1985. *J Clin Oncol* 1988; **6**: 147.
13. Cancer Incidence in Slovenia 1988. Institute of Oncology, Ljubljana, Report No. 30, Ljubljana, 1992.
14. Antman KH, Pass HI, Recht A. Benign and Malignant Mesothelioma. *Cancer: Principles and Practice of Oncology*. Third edition. De Vita V. T. Jr. et al., Ed.: Philadelphia, Lippincott 1989: 1399.