

## Leiomyosarcoma of the maxilla: report of a case

**Borut Sotošek**

*University Clinic for Maxillofacial and Oral Surgery  
Ljubljana, Slovenia*

*A case of medulary bone origin leiomyosarcoma in the maxilla is presented together with a review of the literature. The main symptom was slowly enlarging, painless mass wich exulcerated later on. Special staining methods and imunohistochemical analysis are necessary for dignosis of this tumor. Radical surgical excision remain the mainstay of treatment.*

**Key words:** maxillary neoplasms; leiomyosarcoma

### Introduction

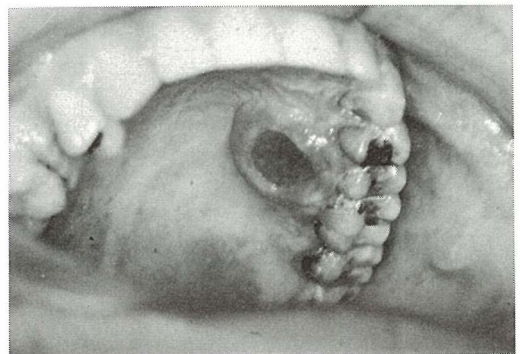
Tumors of the smooth muscle origin may occur anywhere in the human body where smooth muscle is present. They occur with a significant frequency in the alimentary tract but are decidedly unusual in the oral cavity, pharynx and upper respiratory tract.<sup>1</sup> There have been a total of 116 cases of oral leiomyoma described in the literature,<sup>2</sup> and only 25 cases of primary oral leiomyosarcoma were reported,<sup>2-5</sup> those arising centrally within bone are extremely rare.<sup>1, 5</sup> This paper reports an additional case of leiomyosarcoma which originated in the maxilla.

### Case report

In our case, a 29-year-old Caucasian male was admitted on 2 October 1991. His chief comp-

laint was a painless swelling on the right side of the palate, first noticed in August 1991, which exulcerated later on. He had also noticed loosening of the teeth in the region.

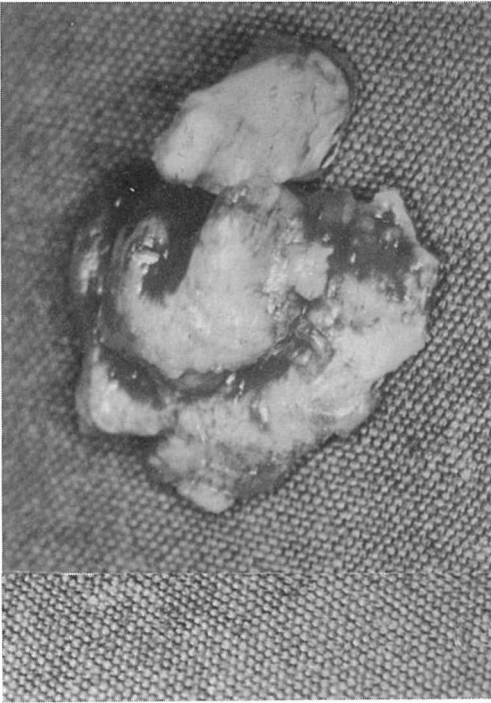
Clinically, a shallow lesion with diameter of 2 cm and central ulceration was present (Figure 1). Specific ulceration was excluded by dermatovenerologist. Local x-ray picture and panoramic radiograph showed partially well and partially illdefined radiolucency of the alveolar



**Figure 1.** Preoperative intraoral view of the exulcerated tumor arising from hard palate.

Correspondence to: Asist. Dr. Borut Sotošek, University Hospital, Clinic for Maxillofacial and Oral Surgery, Zaloška 2, 61000 Ljubljana, Slovenia.

UDC: 616.716.1-006.363.04

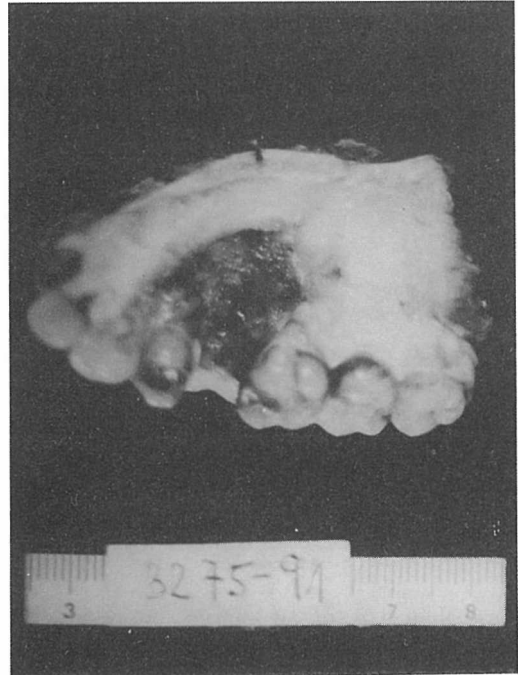

**Figure 2.** Gross appearance of the tumor after enucleation.

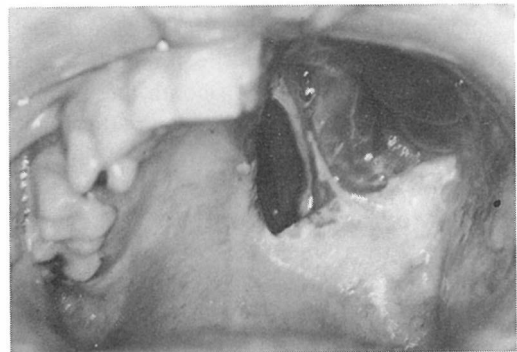process of maxilla on the right side. A biopsy was performed. The initial histological diagnosis was leiomyoma. The lesion was treated by enucleation and tooth extraction. On surgery, the tumor has been shelled out from the bone (Figure 2). Because of the expansion of the tumour into the bone, a medullary bone origin of it was suggested. Histological examination of the surgical specimen showed that the tumor was leiomyosarcoma, moderately differentiated. Histologically, a dense population of neoplastic spindle cells was seen, showing low to moderate mitotic activity (13 mitoses per 50 HPF). Tumor cells showed reactivity to smooth muscle actin. Resected margins were not free of tumor at the base of lesion, so additional surgical management was necessary, without preoperative chemotherapy, which was not indicated because of low mitotic activity of the tumour. Before undertaking further local therapy, the search for a possible primary tumor on other location and/or metastases was performed, with negative results. Therefore, a second

surgical procedure, i.e. partial maxillectomy was performed. The resected bones were macroscopically free of tumour, which was confirmed by frozen sections and also by definitive paraffin sections (Figure 3).

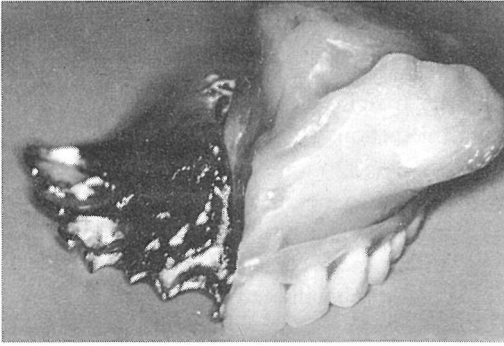
Presently, 19 months after surgery, the patient seems to be free of disease (Figure 4). There are no signs of local recurrence, regional and distant metastases and he is prosthetically successfully rehabilitated (Figures 5, 6).



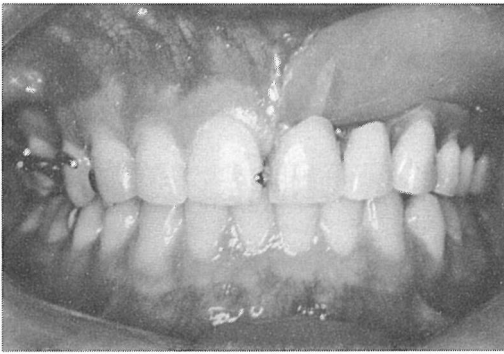
**Figure 3.** Surgical specimen after partial maxillectomy.



**Figure 4.** Postoperative intraoral view, two months after partial maxillectomy.



**Figure 5.** Maxillofacial prosthesis.



**Figure 6.** Prosthetically successfully rehabilitated patient.

### Discussion

Less than 1% of all cancers are soft-tissue sarcomas and, of these, only 2 to 8% are leiomyosarcomas. Leiomyosarcomas arise most commonly in the gastrointestinal and female genital tract.<sup>6</sup>

Superficial soft tissues in the head and neck area are not uncommon site for both benign and malignant variants of smooth muscle neoplasm. Approximately 25% of superficial soft tissue leiomyosarcomas were from this anatomical region.<sup>7</sup>

On the other hand, the oral cavity and upper respiratory tract are unusual sites of origin for smooth muscle neoplasm.<sup>1, 8</sup>

The leiomyosarcoma is a malignant tumor of smooth muscle origin. It is very rare in the oral cavity and whether it develops through malignant transformation of leiomyoma or *de novo*

is not known.<sup>9, 10</sup> To account for the origin of smooth muscle tumors in areas normally deficient in smooth muscle, three explanations have been given: 1. origin from aberrant undifferentiated mesenchyme, 2. origin from smooth muscle elements in the walls of blood vessels, 3. origin from both sources.<sup>1</sup>

The tumour was found in patients of almost all ages ranging from 10 months to 88 years.<sup>1, 9-11</sup>

In oral leiomyosarcomas no sex predilection was apparent,<sup>9</sup> but some another reports suggest a predilection of this tumour for males.<sup>10, 11</sup>

Leiomyosarcomas have been reported in the cheek, tongue, palate, floor of mouth, gingivae and mandible. Where information is available, leiomyosarcomas of this region appear to be lethal lesions in nearly one-half of the patient.

Central (intraosseous) smooth muscle tumors are extremely rare.<sup>1, 5, 10, 12, 13</sup> The maxilla seems to be the favourite site for the occurrence of oral leiomyosarcoma. Of the 21 cases described in the literature, nine were in maxilla, including the palate, as their primary location.<sup>11, 12, 14</sup>

Leiomyosarcomas pose a diagnostic challenge both clinically and microscopically.<sup>3</sup> Clinically, the lesion presents as a painless swelling in some patients while in others a chief complaint is a painful swelling without other clinical characteristics.<sup>9</sup> In one study, an ulceration was seen in only two of 21 cases, one showed a decubital indentation corresponding to the opposing teeth, and other exhibited a true neoplastic ulceration.<sup>11</sup> In the cases in which tumour originated from the jaw bone, the regional teeth became loose at an early stage<sup>9, 11</sup> and that could lead to a mistaken diagnosis of advanced periodontitis and subsequent mismanagement of patients.<sup>3</sup> It was suggested that the most common clinical sign was slowly enlarging, non-ulcerated, painless mass in the early stage which was hard and well-circumscribed giving an impression of a benign tumour.<sup>11, 12</sup>

At the microscopic level this neoplasm can be confused with other lesions. Special staining methods and immunohistochemical analysis are useful for diagnosis of this tumour. The immunohistochemical reactivity of the tissue to de-

smin has been demonstrated to be highly characteristic for leiomyosarcomas and rhabdomyosarcomas. Two features serve to differentiate between the two: the absence of striated-muscle differentiation in leiomyosarcoma and the reactivity to myoglobin in rhabdomyosarcoma.<sup>3</sup>

Radical and complete surgical excision with wide margins of normal tissue remain the mainstay of the treatment, for both primary and recurrent leiomyosarcoma in the head and neck region, with irradiation and chemotherapy as adjunctive treatments.<sup>3,10,11,15,16</sup>

Oral leiomyosarcomas may metastasize to the cervical lymph nodes and lungs with equal frequency, whereas tumours in other sites metastasize to the lung and liver.<sup>3</sup>

The prognosis for this neoplasm is guarded. Oral leiomyosarcomas showed a high incidence of local recurrence, metastasis and poor prognosis. A 50% recurrence and metastatic rate have been reported, with a mortality of 40%. Reported survival rates were 4 weeks to 5 years for the patients with metastases.<sup>10,11</sup>

Metastasis of a leiomyosarcoma to the oral cavity is an extremely rare event.<sup>15</sup> In general, the treatment of intraoral metastatic lesion is palliative or is included in the medical treatment of the primary lesion (radiation or chemotherapy). Resection of metastatic tumours is undertaken infrequently.<sup>15</sup>

Because of the relatively high mortality and recurrence rate, a long-term follow-up of the patient is mandatory.

## References

1. Batsakis JG. *Tumors of The Head and Neck*. Baltimore: Williams & Wilkins, 1980: 354–6.
2. Svane TJ, Smith BR, Cosentino BJ, Cundiff EJ, Ceravolo JJ. Oral Leiomyomas. *J Periodontol* 1986; **57**: 433–5.
3. Krishnan V, Miyaji CM, Mainous EG. Leiomyosarcoma of the mandible: A Case Report. *J Oral Maxillofac Surg* 1991; **49**: 652–5.
4. Natiella JR, Neiders ME, Greene GW. Oral leiomyoma. *Journal of Oral Pathology* 1982; **11**: 353–65.
5. Goldblatt LI, Edesess RB. Central leiomyoma of the mandible. *Oral Surg* 1977; **43**: 591–7.
6. Kissane JM. *Anderson's Pathology St. Louis*: Mosby, 1990: 1861.
7. Stout AP, Hill WT. Leiomyosarcoma of the superficial soft tissue. *Cancer* 1953; **11**: 844.
8. Hemani DD, Gupta AK, Sharma KK, Sharma SD. Leiomyoma of the palate. *The Journal of Laryngology and Otolaryngology* 1983; **97**: 471–7.
9. Shafer WG, Hine M, Lewy BM. *A Textbook of Oral Pathology*. Philadelphia: W. B. Saunders Company, 1983: 199.
10. Kratochvil FJ, MacGregor SD, Budnick SD, Hewan-Lowe K, Allsup HW. Leiomyosarcoma of the maxilla. *Oral Surg* 1983; **54**: 647–55.
11. Nishi M, Mimura T, Senba I. Leiomyosarcoma of the maxilla. *J Oral Maxillofac Surg* 1987; **45**: 64–8.
12. Kawabe Y, Kondo T, Hosoda S. Two cases of leiomyosarcoma of the maxillary sinuses. *Arch Otolaryng* 1969; **90**: 492–5.
13. Farman AG, Kay S. Oral leiomyosarcoma. *Oral Surg* 1977; **43**: 402–9.
14. Takagi M, Ishikawa G. An autopsy case of leiomyosarcoma of the maxilla. *J Oral Path* 1972; **1**: 125–32.
15. Bogart SF, Sacks HG, DeMarco L. Metastatic leiomyosarcoma of the Palate. *J Oral Maxillofac Surg* 1990; **48**: 1338–40.
16. Dropkin LR, Tang CK, Williams JR. Leiomyosarcoma of the nasal cavity and paranasal sinuses. *Ann Otol* 1976; **85**: 399–403.