

Clinical advances of contrast-enhanced MR imaging A review

Vinko Kristl

*Institute for Diagnostic and Interventional Radiology, University Clinical Centre, Ljubljana
Slovenia*

The review shows clinical use and some results obtained with contrast agent gadopentetate dimeglumine (Gd-DTPA). It may improve the diagnostic capability of MR imaging. The contrast-enhanced MR imaging is relatively new diagnostic modality and has rapidly evolved from an experimental field to a widely used clinical technique. Further studies are needed to confirm most of potential indications.

Key words: magnetic resonance imaging; gadolinium; gadolinium-DTPA, diagnostic approach.

Introduction

In a relatively short time, MR imaging became an essential diagnostic tool for the practice of medicine. Tissue relaxation times (T_1 , T_2), proton density and flow are the principal intrinsic factors, that determine signal intensity on MR images. During the early development of MR imaging there was no exogenously administered contrast material. Anatomic regions that can be immobilized, such as the head, spine and extremities present few obstacles to MR imaging. Routine technique produces excellent images of these regions. MR images of the body, on the other hand, have suffered from low spatial resolution, low signal – to – noise ratios and motion – related artifacts. With greater clinical use of MR imaging, however, the difficulty in

differentiating lesions such as neoplasms or abscesses of the central nervous system and other organs from surrounding edema became apparent. Intensive efforts to improve the diagnostic utility of body MR imaging have resulted in a variety of specialized approaches: pharmaceutical manipulation of signal-to-noise ratios, tissue contrast improved data acquisition, and image processing. Contrast agents alter the tissue signal intensity by either decreasing proton relaxation times or by altering proton density. Now it is known that MR contrast agents improve the usefulness of MR imaging which plays an increasingly important role in clinical practice. Contrast – enhanced MR imaging can simultaneously provide dynamic physiologic information (anatomic and/or biochemical) and high anatomic detail, thereby overcoming the major limitations of both nuclear scintigraphy (poor anatomic resolution) and CT (limited physiologic information).¹ Thus, in both physiologic and pathologic situations where contrast enhancement is seen with CT, a similar result should be expected with MR imaging. There

Correspondence to: Vinko Kristl, MD, IDIR, University Clinical Center, Zaloška 7, 61000 Ljubljana, Slovenia.

are major differences with MR imaging depending on the pulse sequence used. T_1 dependent pulse sequences show the greatest enhancement and T_2 dependent pulse sequences show the least enhancement. Differences in CT and MR imaging are also in display of calcified tissue, flow effects.^{1,2}

Gadolinium diethylene triamine pentaacetic acid in form dimeglumine salt (Gd-DTPA) is the first MR contrast agent which received Food and Drug Administration approval in June 1988, and is used in clinical practice. Gd-chelated to DTPA molecules make up a contrast agent which has no tissue specificity. Metal ion is chelated to reduce biologic toxicity, biodistribution and pharmacokinetics are ligands dependent. Toxicologically Gd-DTPA is similar to a common iodinated contrast agent.

Pharmacology of Gd-DTPA

After i.v. injection, Gd-DTPA has a plasma half-life of 90 min. This biodistribution follows a two compartment model. It is rapidly redistributed from the vascular compartment into the extracellular space and undergoes renal elimination by passives glomerular filtration.¹ The kidneys concentrate Gd-DTPA and over 90% of it is excreted unchanged with urine within 3 hours. A very small amount of it is excreted through the gastrointestinal tract. Gd-DTPA does not cross the normal blood-brain barrier. Gd-DTPA produces changes in tissue T_1 and T_2 . There is no direct relationship between the concentration of Gd-DTPA and the observed signal intensity.

Toxicity of Gd-DTPA

Immediate short-time side effects have not represented a problem; for example blood pressure and pulse rate have been stable. There are some increased or decreased values in some parameters noted in hematologic testing. There is 15 – 30% incidence of transient increase in serum iron concentration. This has generally persisted for less than 24 hours and has returned to normal. A transient rise in serum bilirubin

has also been observed in a few cases, although no significant clinical sequelae developed. No evidence of in vivo dissociation of the Gd-DTPA complex exists, and further trials have been planned on the assumption that these side effects are not of major clinical importance.^{1,3,4}

Gd-DTPA effects on T_1 and T_2

Gd-DTPA produces a change in relaxation rates, which are reciprocal of T_1 or T_2 relaxation time. Increasing of Gd-DTPA concentration produces a decrease in both T_1 and T_2 . This reduction will be greater in absolute terms for T_1 than for T_2 . Protons within fat are not as accessible to Gd-DTPA as protons in free water, thus the changes to protons in fat would be expected to be less than those for protons in water. The term “negative enhancement” is used to describe the situation where tissue signal intensity is decreased by a contrast agent. By using Gd-DTPA, a great change in signal intensity is seen in the inversion recovery sequence (IR).

The overall effect of Gd-DTPA depends on the dosage of contrast agent. Dosages of 0.1 – 0.2 mmol/kg body weight are used. Delayed examinations of the brain may show a greater effect than immediate examinations because transport of Gd-DTPA across the blood-brain barrier may take time. The reverse may be true with very vascular lesions. It must also be remembered that although many pathologic processes increase T_1 and T_2 , Gd-DTPA decreases T_1 and T_2 . Thus considerable potential exists for “isointense” behaviour, whereby the contrast agent reduces tissue T_1 and T_2 values back to those of the adjacent normal tissue, producing a net loss of tissue conspicuity.

Clinical studies investigating the use of contrast agent in MR imaging of the body are few in comparison to studies of contrast – enhanced MR imaging of the brain and spinal canal.¹ This fact is attributable in part to the relatively greater complexity associated with contrast-enhanced MR imaging of non-neurologic disorders. For example, Gd-DTPA induced signal enhancement can result in more pronounced

motion artifacts, and the rapid diffusion of contrast into the extracellular space may neutralize soft-tissue contrast between healthy and diseased tissues. From this point of view it is sensible to present separately neurologic and non neurologic applications of Gd-DTPA in MR imaging.

I. Neurologic Gd-DTPA applications

Gd-DTPA does not cross the normal blood-brain barrier but is present in higher concentration in the gray matter as compared with the white matter, reflecting the different vascularity of these tissues. Owing to differences in perfusion, the gray matter will enhance more than the white matter, resulting in a loss of gray-white soft tissue contrast on postcontrast images. The pituitary stalks, pituitary gland, cavernous sinus and choroid plexus enhance also. Because of flow, vascular enhancement is more variable than it is with CT and is most obvious in the structures.

During spinal imaging the normal cord, nerve roots, and intervertebral disks do not enhance.²

The blood-brain barrier is generally impermeable to Gd-DTPA. In a variety of pathological conditions including tumors, infections and demyelinating diseases it becomes permeable (vascular permeability), and Gd-DTPA accumulates in an extravascular location. For screening examination of the brain highly T₂ weighted spin echo (SE) sequences (these are insensitive to contrast enhancement) and T₁ weighted sequence (either IR or SE) are used for better anatomic details. T₁ weighted sequences are sensitive to contrast enhancement.

Benign tumors

Meningioma exhibits an increase in T₁ and T₂ (Figure 1).⁵ Some meningiomas display only a slight increase in T₁ as compared with the white matter, and have T₂ values within the normal range for the brain. Calcifications and bony changes are poorly shown by MR imaging. It is possible to predict meningioma (histologic

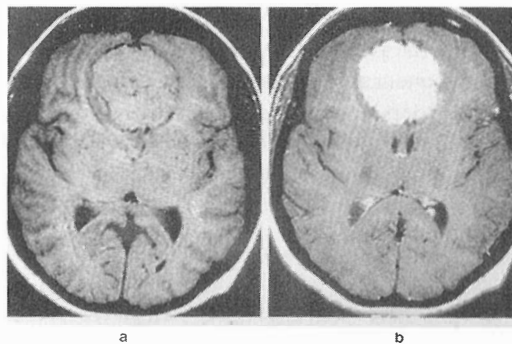


Figure 1. Meningioma without contrast agent: a – SE 2800/30, b – SE 600/20, Gd-DTPA enhanced.

subtypes) on signal intensity (SI) changes⁵. Gd-DTPA is most useful in the detection and characterization of small meningiomas.

In a case of meningioangiomatosis (rare cortical hamartomatous lesion) Gd-DTPA can show no lesion enhancement, which suggests an intact blood-brain barrier.⁶

Acoustic neuroma shows an increase in T₁ and T₂. It is located within the internal auditory canal, within the cerebellar pontine angle or within the posterior cranial fossa. With larger tumors contrast between the brain and cerebral edema is important. Sequences of T₁ and T₂ weighting are used. Contrast enhancement is of great value. Extravasation of the contrast agent molecules through the blood-brain barrier into a brain lesion results in a focal contrast enhancement. Characteristic time dependent contrast enhancement of cerebral lesions is helpful in differentiation between meningiomas and neurinomas.⁷

MR imaging with Gd-DTPA enhancement is the preferred method for depicting intracranial acoustic or facial neuromas, but enhancement of the nerve, even focal enhancement, is not diagnostic for the neuroma (nonneoplastic lesions, and neuritis may mimic a small acoustic neuroma on MR imaging).⁸

Other benign tumors

Enhancement has been seen with pituitary tumors, chordomas, glomus jugular tumors, and epidermoid tumors.

Malignant tumors

It is difficult to separate edema from tumor because both processes produce an increase in T_1 and T_2 . Differences between them depend only on exploiting relative differences in the degree of these changes. With more imaging sequences, there is more chance to separate the tumor from edema. Highly malignant tumors show greatest enhancement with Gd-DTPA contrast. Enhancement within cystic tumors has also been seen. Sometimes enhancement of areas of apparent edema can be seen with Gd-DTPA where it probably represents tumor infiltration.²

Enhancement on MR imaging may be especially valuable in low grade tumors and may be an important guide to biopsy when no enhancement is seen on CT. With noncontrast imaging using a selection of T_1 and T_2 weighted pulse sequences it is not possible to obtain the same separation level of tumor from edema achieved with Gd-DTPA. So is Gd-DTPA helpful in identifying the nidus of tumor, and contrast agent clearly improves the diagnostic sensitivity of T_1 weighted pulse sequences. It is important to remember that Gd-DTPA enhancement does not delineate the borders of tumors, but rather the side of maximal blood-brain barrier breakdown. Gd-DTPA should be used for scanning tumors of the frontal, ethmoid, and sphenoid sinuses for the evaluation of intracranial spread extension of disease. Reactive edema in the inferior frontal lobes can be seen.⁹ Mild focal or diffuse dural enhancement with Gd-DTPA is a normal finding on enhanced MR imaging in the pediatric patient who has undergone biopsy, craniotomy or intraventricular shunt placement for an intracranial neoplasm or associated hydrocephalus.¹⁰

Gd-DTPA enhanced examination is very useful in patients with metastatic disease, where it is possible to identify more lesions. After cerebral tumor resection, enhancement of residual or recurrent tumor is readily separated from postoperative changes such as encephalomalacia or gliosis. The value of Gd-DTPA in separating radiation necrosis from a residual tumor is unclear.²

Cerebrovascular diseases

With the use of contrast agent in MR imaging luxury perfusion is noted in the cases of cerebral infarction. Contrast agent is of diagnostic value in differentiating subacute from chronic cerebral infarctions to predict the age of the lesion. Most of the subacute lesions showed the signs of mass effect (increased blood flow represents a luxury perfusion due to collateral formation or reopening of occluded vessels) (Figure 2).¹¹ Furthermore, Gd-DTPA appears to be useful in the MR evaluation of early ischemia and its response to intervention.¹²

Arteriovenous malformations show a different pattern. Slowly flowing blood has great enhancement and rapidly flowing blood has no enhancement. The type of venous drainage, either superficial or deep, could be determined by contrast enhanced MR imaging. The intravenous administration of contrast adds significant information in the MR study of venous angio-ma.¹³

Ring enhancement in contrast MR imaging has been identified at the margin of giant aneurysms (probably reflecting proliferation of the vasa vasorum).

Enhancement of the membrane associated with subdural hematomas may be visualised.

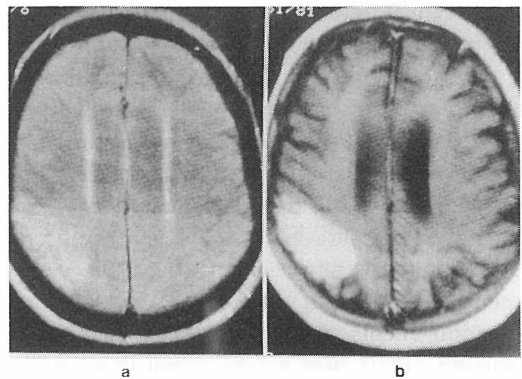


Figure 2. Subacute infarction: a – T_2 -weighted image; increased signal intensity in the right parietal region. b – Postcontrast T_1 -weighted image, contrast enhancement in the infarcted area.

Demyelinating diseases

Multiple sclerosis was the first disease in which MR imaging was demonstrated to have significant advantages over X-ray and CT. Multiple sclerosis is the major indication for MR imaging. Its sensitivity is increased by the use of Gd-DTPA and by delayed examination.² Non-contrast MR imaging is very sensitive in detecting demyelinating diseases, especially on T₂-weighted images.¹⁴

However, gadopentetate dimeglumine enhanced MR has been shown to be more sensitive than contrast enhanced CT for identifying regions of abnormal blood-brain barrier that may correlate with clinical activity.

In patients with chronic partial epilepsy Gd-DTPA should be used selectively to clarify or better define the nature of abnormalities encountered on unenhanced scans. The likelihood of missing an important abnormality by performing unenhanced imaging alone is small.¹⁵

Infections

Ring enhancement is a well known feature of cerebral abscess and other patterns of enhancement may also be seen both with abscess and other forms of CNS (central nervous system) infections. MR has been demonstrated to be sensitive for the detection of CNS involvement with viral infections. In case of acute disseminated encephalomyelitis MR typically demonstrates multiple focal areas of increased signal on T₂ weighted images within the brain stem, cerebrum and cerebellum. Predominant pathologic finding with this disorder are focal areas of demyelination. MR abnormalities are typically located within the white matter.¹⁶

In a case of parasitic disease (neurocysticercosis) contrast enhancement around the cysticerci seems to occur when there are both surrounding edema and signal intensity of the cyst contents higher than cerebrospinal fluid on T₁ and proton density-weighted images. Such enhancement probably reflects degeneration of the worms and an inflammatory reaction of the adjacent brain tissue. The degree of contrast

enhancement on MR imaging may indicate the degree of focal parenchymal inflammatory reaction around the cysts.¹⁷

Orbit

The advantages of MR imaging in this site are as follows: there radiation on the lens, high soft-tissue contrast visualizing of the optic nerve within the optic canal. The abundant orbital fat leads to chemical shift misregistration artefacts. In the cases of optic neuritis, the abnormally enhanced nerve is often masked by the surrounding high signal fat on T₁ weighted images. Post Gd-DTPA fat suppression T₁ weighted images clearly identified the shaggy, enhanced inflammatory perioptic lesions with or without an enhanced optic nerve.¹⁸ With this finding we can differentiate perineuritis from the smoothly outlined enhancing perioptic meningioma.

Soft tissues, nasopharynx and soft tissue of the neck

We can see differential enhancement between the lesion and normal mucosa. Mucosa has high level of vascularity and high water content so it displays a moderately high level of enhancement with Gd-DTPA. Gd-enhanced MR imaging of the cranial nerves (fifth nerve) is recommended in patients with cranial nerve sensory or motor deficit or neuralgia. Contrast enhanced MR imaging appears to be superior to noncontrast imaging, as it is possible by means of imaging characteristics, to separate benign from malignant disease.¹⁹

Spinal cord

With MR imaging it is possible to visualize the spinal cord directly without intrathecal contrast agents. Parenchymal changes within the cord can also be seen directly. Gd-DTPA is used for defining extramedullary lesions and for distinguishing tumor from edema, and defining the extent of metastatic spread. It is possible to differentiate scar from a recurrent disk

following surgery. Overall, the spinal cord has been one of the most promising sites for the use of Gd-DTPA. Three dimensional gradient echo steady state sequence and postprocessing gives a view of the thecal sac and the dural root sleeves.²⁰ It may provide enough information to eliminate the need for contrast myelography in the evaluation of extradural disease. Gd-DTPA provides conspicuity of tumors, inflammatory and infective processes. It enables differentiation of cystic tumors from syringomyelia and post-radiation cord damage, and epidural fibrosis from recurrent disc.

II. Non-neurologic applications

Thorax

Flow properties of MR imaging enable differentiation between masses and vascular structures. The indications for Gd-DTPA in MR imaging might be expected to be fewer than the indications for iodine based agents in CT. Mediastinal masses have displayed enhancement and the pattern of the proximal pulmonary vasculature can be demonstrated with them.

Contrast enhancement has been seen in the margin of areas of myocardial infarction. There are two or three zones identified in acute, subacute or chronic stages of myocardial infarction. Greater enhancement is produced in the peri-infarction zone than in the normal or infarcted myocardium.^{21, 22} By diagnostic MR it is possible to determine pseudoaneurysms of the heart.²³ MR can detect intramural and intracavitary cardiac tumors which are bigger than 5 mm. MR imaging can also provide essential information on tumor extent, location, and relation to the cardiac and paracardiac structures.²⁴

Gd-DTPA has proved valuable in separating neoplastic from fibrotic lesions within the breast, although difficulties in distinguishing benign and malignant tumors remain. In the case of bronchus tumor or mesothelioma the major use of MR is in the evaluation of mediastinal involvement, the relationship of the tumor to the great vessels, and the presence of

chest wall involvement.²⁵ MR imaging is similar to CT in its ability to evaluate normal and abnormal hila and mediastina.²⁶ MR is superior to CT in showing enlarged hilar lymph nodes, but CT is better for demonstrating bronchial abnormalities.²⁷

Because of the contrast resolution between static and flowing blood, pulmonary emboli can be demonstrated non-invasively, but the question remains whether the increased signal intensity depends only on slow flow or on the embolus itself.²⁸

The central vasculature in the mediastinum can be evaluated by means of MR angiography. Two dimensional FLASH angiography (a fast low angle shot two-dimensional pulse sequence) can be postprocessed into a three-dimensional MR angiography by a maximum intensity projection algorithm.²⁹

Alterations in both T₁ and T₂ reflect changes in water content of inflammatory alveolitis to fibrotic lungs.³⁰

Abdomen

Liver: The normal liver parenchyma shows marked enhancement soon after an intravenous injection of Gd-DTPA but this decreases with its redistribution and excretion. The liver, pancreas, and adrenal gland enhance homogeneously, whereas the spleen, kidney and the abdominal aorta and inferior vena cava enhance heterogeneously with dynamic gadolinium-enhanced MR imaging.³¹

Liver tumors show variable enhancement but may also have greater enhancement than normal liver so that they become isointense (Figure 3). Gd-DTPA enables better differentiation between necrotic and other areas of tumor, more precision in defining tumors and differentiation between portal veins and dilated bile ducts. MR correctly localized 90% of the liver metastatic lesions. MR represents an ideal modality for lesion localization because it accurately depicts hepatic vessels fissures that define segmental boundaries. The flow void phenomenon causes the hepatic veins to be strikingly low in

signal. Because the hepatic veins act to separate the hepatic segments, lesion site can be easily assessed.³²

The appearance of hemangiomas in dynamic gadopentetate dimeglumine enhanced MR imaging is characterized by hyperintense peripheral enhancement followed by a fill-in phenomenon. This is quite distinct from the enhancement behaviour of liver metastases, and hepatocellular carcinomas. The difference in SI between hemangiomas and metastases is most striking on delayed images. Hypervascular metastases do not show the homogenous high SI typical of hemangiomas. Focal-nodular hyperplasia is characterized in dynamic contrast-enhanced MR imaging by a strong contrast enhancement with a peak during the first 30 seconds after contrast administration, and by a rapid decrease in SI.¹ Turbo FLASH (fast low angle shot) dynamic scanning of liver with Gd-DTPA enhancement significantly improves lesion-liver contrast particularly in the cases of focal nodular hyperplasia of the liver.³³ Improved liver-to lesion contrast is possible with intraarterial portography with Gd-DTPA.³⁴

Spleen: The sensitivity of MR imaging in the detection of tumorous lesions of the spleen is low because relaxation times and SI of normal spleen and intrasplenic tumors are very similar. Contrast agents can dramatically improve

tumor detection. Normal splenic enhancement pattern during dynamic gadolinium-enhanced T₁ weighted spin-echo MR imaging is heterogeneous, with conversion to homogeneous enhancement one minute later.³⁵ Prolonged enhancement on postcontrast MR imaging is a useful finding in differentiation of splenic hamartoma (rare benign lesion) from malignant lesions of the spleen (especially from nodular lesions of malignant lymphoma).³⁶

Pancreas: In evaluating diseases of the pancreas, MR is still inferior to CT. Development of oral contrast agents is a first step toward improving the usefulness of MR imaging of the pancreas, because the pancreas must be first differentiated from the gastrointestinal tract. In cases of pancreatic transplant dysfunction Gd-DTPA enhanced MR imaging is a very sensitive technique.³⁷

Adrenals: Malignant tumors and pheochromocytomas show a significantly greater SI than adenomas in precontrast images. After administration of Gd-DTPA only moderate enhancement and quick washout is observed in adenomas, whereas malignant tumors and pheochromocytomas show strong enhancement and slower washout.¹ With gradient echo sequences adrenocortical adenomas display a lower SI than other adrenal lesions on T₂ weighted ima-

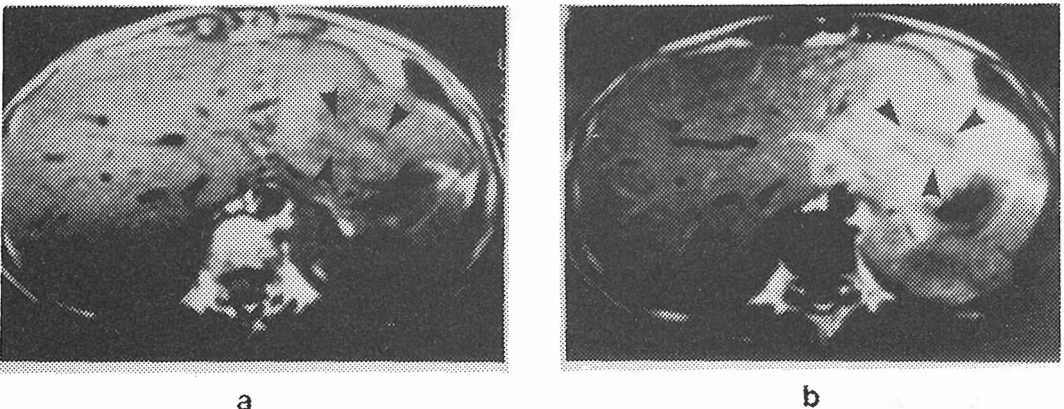


Figure 3. Hepatocellular carcinoma a – short TR/TE (700/20) SE sequence, b – short TR/TE (700/20) SE sequence after Gd-DTPA injection.

ges. Pheochromocytomas, metastases, and carcinomas of the adrenals show a high SI. Additional dynamic contrast enhanced studies allow further classification. The physiopathologic mechanism of different enhancement patterns is based on the strong perfusion of malignant tumors. A disturbed permeability of the capillaries of malignant lesions leads to an increased diffusion of the contrast agent into the interstitial space. In the case of metastases and carcinomas, the contrast agent is retained in the extravascular space for a longer period of time.³⁸ Additional advantage of MR images is that multiplanar sections allow a better overview of the topographic relationships.

Kidney: In the kidney Gd-DTPA is concentrated and sharp differentiation between the cortex and medulla can be produced. The concentration of Gd-DTPA in the collecting system is usually sufficient for reduction in the T_2 of urine to dominate the reduction in T_1 producing a zero signal with all sequences using the conventional doses. If a low dose is given and the patient is scanned quickly, however, an increased SI may be seen in the collecting system. Contrast-enhanced MR imaging for both tumor diagnosis and functional assessment is best achieved when dynamic studies are performed in combination with a bolus injection of gadopentetate dimeglumine. Gadolinium-enhanced MR imaging is an effective method for characterizing renal lesions in patients with renal insufficiency. At the usual dosage there appears to be no nephrotoxic reaction in these patients.³⁹

Retroperitoneum: A variety of retroperitoneal lesions have displayed enhancement which may produce a better definition of the extent of particular lesions. MR imaging has proved unreliable in the distinction of normal and neoplastic nodes by means of SI characteristics, because the relaxation times and proton densities of normal and metastatic nodes overlap.¹

Pelvis: General considerations applicable to imaging of soft tissue outside the CNS apply to the pelvis. Pelvic tumors display enhancement

and similar parallels have been seen with other pathologic processes. The bladder shows concentration phenomena, whereby a signal from the posterior bladder (concentrated Gd-DTPA) may be zero with a zone of enhancement between lower and upper zones where the concentration is optimal with essentially normal urine above. Contrast-enhanced MR imaging appears to allow better bladder tumor staging than do precontrast T_1 and/or T_2 weighted pulse sequences. This is especially true for the distinction of superficial tumors from those infiltrating the muscle, because noninvolvement of the muscle layer is visualized as an intact hypointense line in the region underlying the tumor. The application of Gd-DTPA proved valuable in detecting small bladder tumors and in differentiating between necrotic and vital tissue within large ones. Tumors are generally characterized by a very inhomogeneous perfusion with an augmented vascularization along the edges of the tumor and a rarified capillary network within the tumor center. This probably causes an uneven distribution of contrast medium within bladder tumors. Neurofibromas show a markedly increased SI on T_2 weighted images relative to the surrounding soft tissues with marked enhancement following Gd-DTPA administration.^{40,41}

Reports of MR imaging for staging of bladder neoplasms have been encouraging owing to its inherent soft tissue contrast as well as the advantage of multiplanar applicability. However, some authors suggest that the accuracy of MR imaging performed without a contrast medium in determining the depth of tumor invasion is only slightly better or even worse than that of CT.⁴² However, both precontrast and postcontrast T_1 weighted images of the bladder should be obtained.

In the diagnosis of tumors of the uterus, Gd-DTPA enhanced MR imaging can yield additional information in patients with endometrial carcinoma. Viable and necrotic areas are easier to distinguish on postcontrast than on T_2 weighted precontrast images. In the evaluation of ovarian masses, Gd-DTPA improves the

visualization of the tumor structure and may allow better distinction of inflammatory adnexal processes from malignant tumors.¹

Muscle-skeletal system

Contrast enhanced MR imaging with T₁ weighted echo pulse sequences is more variable in distinguishing different tumor components, necrosis, peritumoral edema and viable tumor tissue, than is precontrast imaging. Marked improvement occurs after contrast application compared with the T₁ weighted precontrast image, the contrast is never as strong as in T₂ weighted precontrast sequences. Application of Gd-DTPA reduces the contrast between enhancing tumor and signal-intensive fatty tissue and bone marrow. This is used for characterization and evaluation of tumors before and after treatment.⁴³ Gd-DTPA MR imaging is used also in the joints for delineation of cartilage and tendon tears, for differentiation between pannus and joint effusion and for the delineation of infection processes.⁴⁴

Conclusion

Administration of Gd-DTPA has pointed out that MR imaging is no longer noninvasive in the strict sense, and the duration of the examinations may be increased. Once Gd-DTPA has been accepted, the question concerning its strict clinical indications needs to be solved. As with other aspects of MR imaging, the options are wide, and the principal agent in use at the present time, Gd-DTPA is one of the most obvious choices. Much more effort will undoubtedly be expended on developing other contrast agents, some of which will find application in clinical practice. Without a gastrointestinal contrast agent, MR imaging will be unable to provide global examination of the abdomen. With novel formulations such as the nonionic isoosmolar preparations, higher doses or prolonged infusion may further improve diagnostic information.

References

1. Saini S, Modic MT, Hamm B, Hahn PF. Advances in contrast-enhanced MR imaging. *AJR* 1991; **156**: 235-54.
2. Stark DD, Bradley WG. *Magnetic resonance imaging*. St. Louis: The C. V. Mosby Company, 1988.
3. Kristl V. Contrast agents in MR imaging. *Radiol lugosl* 1991; **25**: 355-9.
4. Laniado M, Claussen C, Weinmann HJ, Schroeder W. Paramagnetic contrast media in magnetic resonance imaging of the brain. In: Taveras JM, Ferrucci JT. *Radiology*. Lippincott, Philadelphia. Vol. 3, part 59, 1989.
5. Kaplan RD, Coons S, Drayer BP, Roger Bird C, Johnson PC. MR characteristics of meningioma subtypes at 1.5 tesla. *J Comput Assist Tomogr* 1992; **16**: 366-71.
6. Tien RD, Osumi A, Oakes JW, Madden JF, Burger PC. Meningioangiomatosis: CT and MR findings. *J Comput Assist Tomogr* 1992; **16**: 361-5.
7. Felix R, Schoerner W, Sander B, et al. Contrast-enhanced MR brain studies: clinical experience with Gd-DTPA over four years. *Diagnostic Imaging* 1988; Supl. 13-5.
8. Han MH, Jabour BA, Andrews JC at all. Nonneoplastic enhancing lesions mimicking intracranial acoustic neuroma on gadolinium-enhanced MR images. *Radiology* 1991; **179**: 795-6.
9. Tassel P, Ya-Yen Lee. Gd-DTPA enhanced MR for detecting intracranial extension of sinonasal malignancies. *J Comput Assist Tomogr* 1991; **15**: 387-92.
10. Hudgins AP, Davis PC, Hoffman JC. Gadopentetate dimeglumine enhanced MR imaging in children following surgery for brain tumor: spectrum of meningeal findings. *AJR* 1991; **156**: 1237-43.
11. Cordes M, Henkes H, Roll D, Eichstaedt H, Christe W, Langer M, Felix R. Subacute and chronic cerebral infarction: SPECT and Gadolinium-DTPA enhanced MR imaging. *J Comput Assist Tomogr* 1989; **13**: 567-71.
12. Crain Mr, Yuh WTC, Greene GM, Loes DJ, Ryals TJ, Sato Y, Hart MN. Cerebral ischemia: evaluation with contrast-enhanced MR imaging. *AJR* 1991; **157**: 575-83.
13. Wilms G, Demaerel P, Marchal G, Baert AL, Plets C. Gadolinium-enhanced MR imaging of cerebral venous angiomas with emphasis on their drainage. *J Comput Assist Tomogr* 1991; **15**: 199-206.
14. Caldemeyer KS, Harris TM, Smith RR, Edwards MK. Gadolinium enhancement in acute disseminated encephalomyelitis. *J Comput Assist Tomogr* 1991; **15**: 673-75.
15. Elster AD, Mirza W. MR imaging in chronic partial epilepsy: role of contrast enhancement. *AJR* 1991; **156**: 605-10.
16. Tolly TL, Wells RG, Sty JR. MR features of fleeting CNS lesions associated with Epstein-Barr virus infection. *J Comput Assist Tomogr* 1989; **13**: 665-8.
17. Chang KH, Lee JH, Han MH, Han MC. The role of contrast-enhanced MR imaging in the diagnosis of neurocysticercosis. *AJR* 1991; **157**: 393-6.

18. Tien RD, Hesselink JR, Szumowski J. MR fat suppression combined with Gd-DTPA enhancement in optic neuritis and perineuritis. *J Comput Assist Tomogr* 1991; **15**: 223-7.
19. Sevick RJ, Dillon WP, Engstrom J, Bergman WG, Ric Harnsberg H. Trigeminal neuropathy: Gd-DTP enhanced MR imaging. *J Comput Assist Tomogr* 1991; **15**: 605-11.
20. VanDyke CW, Modic MT, Beale SM, Amartur S, Ross JS. 3D MR myelography. *J Comput Assist Tomogr* 1992; **16**: 497-500.
21. Saeed M, Wendland MF, Masui T, Connolly AJ, Derugin N, Brash RC? Higgins CB. Myocardial infarction: assessment with an intravascular MR contrast medium. *Radiology* 1991; **180**: 153-60.
22. van Dijkman PRM, van der Wall EE, de Roos A, Matheijssen NAA, van Rossum AC, Doornbos J, van der Laarse A, van Voorthuisen AE, Bruscke AVG. Acute, subacute and chronic myocardial infarction: quantitative analysis of gadolinium-enhanced MR images. *Radiology* 1991; **180**: 147-150.
23. Duvernoy O, Wikstrom G, Mannting F, Larson SG, Andren B, Dubiel T. Pre- and postoperative CT and MR in pseudoaneurysms of the heart. *J Comput Assist Tomogr* 1992; **16**: 401-9.
24. Rienmueller R, Lloret JL, Tiling R, Groh J, Manert W, Mueller DK, Seifert K. MR imaging of pediatric cardiac tumors previously diagnosed by echocardiography. *J Comput Assist Tomogr* 1989; **13**: 621-6.
25. Lorigan JG, Libshitz HI. MR imaging of malignant pleural mesothelioma. *J Comput Assist Tomogr* 1989; **13**: 617-20.
26. Heelan RT, Martini N, Westcott JW, et al. Carcinomatous involvement of the hilum and mediastinum: Computed tomographic and magnetic resonance evaluation. *Radiology* 1985; **156**: 111-5.
27. Webb WR, Jensen BG, Sollitto R, de Geer G, McCowin M, Gamsu G, Moore E. Bronchogenic carcinoma: staging with MR compared with staging with CT and surgery. *Radiology* 1985; **156**: 117-24.
28. Ovenfors CO, Batra P. Diagnosis of peripheral pulmonary emboli by MR imaging: an experimental study in dogs. *Magn Reson Imag* 1988; **6**: 487-91.
29. Kauczor HU, Layer G, Schad LR, et al. Clinical application of MR angiography in intrathoracic masses. *J Comput Assist Tomogr* 1991; **15**: 409-17.
30. Vinitski S, Pearson MG, Karlik SJ, et al. Differentiation of parenchymal lung disorders with in vitro proton nuclear magnetic resonance. *Magn Reson Med* 1986; **3**: 120-5.
31. Mirowitz SA, Gutierrez E, Lee JKT, Brown JJ, Heiken JP. Normal abdominal enhancement patterns with dynamic gadolinium-enhanced MR imaging. *Radiology* 1991; **180**: 637-40.
32. Zeman RK, Dritschilo A, Silverman PM, et al. Dynamic CT vs 0.5T MR imaging in the detection of surgically proven hepatic metastases. *J Comput Assist Tomogr* 1989; **13**: 637-44.
33. Mathieu D, Rahmouni A, Anglade MC, et al. Focal nodular hyperplasia of the liver: assesment with contrast-enhanced Turbo FLASH MR imaging. *Radiology* 1991; **180**: 25-30.
34. Pavone P, Giuliani S, Cardone G, et al. Intraarterial portography with gadopentetate dimeglumine: improved liver-tolesion contrast in MR imaging. *Radiology* 1991; **179**: 693-7.
35. Mirowitz SA, Brown JJ, Lee JKT, Heiken JP. Dynamic gadolinium-enhanced MR imaging of the spleen: normal enhancement patterns and evaluation of splenic lesions. *Radiology* 1991; **179**: 681-6.
36. Ohtomo K, Fukuda H, Mori K, Minabi M, Itai Y, Inoue Y. CT and MR Appearances of splenic hamartoma. *J Comput Assist Tomogr* 1992; **16**: 425-8.
37. Fernandez MP, Bernardino ME, Neylan JF, Olson RA. Diagnosis of pancreatic transplant dysfunction: value of gadopentetate dimeglumine-enhanced MR imaging. *AJR* 1991; **156**: 1171-6.
38. Krestin GP, Friedmann G, Fischbach R, Neufang KFR, Allolio B. Evaluation of adrenal masses in oncologic patients: dynamic contrast-enhanced MR vs CT. *J Comput Assist Tomogr* 1991; **15**: 104-10.
39. Rofsky NM, Weinreb JC, Bosniak MA, Libes RB, Birnbaum BA. Renal lesions characterization with gadolinium-enhanced MR imaging: efficacy and safety in patients with renal insufficiency. *Radiology* 1991; **180**: 85-9.
40. Neucenburg JM, Bohndorf K, Sohn M, Teufl F, Guenther RW, Daus Hj. Urinary bladder neoplasms: evaluation with contrast-enhanced MR imaging. *Radiology* 1989; **172**: 739-43.
41. Shonnard KM, Jelinek JS, Benedikt RA, Kransdorf MJ, CT and MR of neurofibromatosis of the bladder. *J Comput Assist Tomogr* 1992; **16**: 433-8.
42. Neucenburg JM, Bohndorf K, Sohn M, et al. Staging of urinary bladder neoplasms with MR imaging: Is Gd-DTPA helpful? *J Comput Assist Tomogr* 1991; **15**: 780-6.
43. Beltran J, Chandnani V. McGhee RA? Kursunoglu-Brahme S. Gadopentetate dimeglumine-enhanced MR imaging of the musculoskeletal system. *AJR* 1991; **156**: 457-66.
44. Seeger LL, Widoff BE, Bassett LW, Rosen G, Eckardt JJ. Preoperative evaluation of osteosarcoma: value of gadopentetate dimeglumine-enhanced MR imaging. *AJR* 1991; **157**: 347-51.