

Management of a patient with solitary brain metastasis of unknown origin

Miha Debevec¹ and Miha Škrbec²

¹The Institute of Oncology, Ljubljana

²Institute of Radiology, University Clinical Center, Ljubljana

A case of a patient with solitary brain metastasis is presented. The primary tumor was found only after radiography of the lung in lateral projection. The change evident on CT scan was difficult to evaluate because of a thrombosis in the internal cervical artery and related to it infarction in the region of the median cerebral artery, which, however, was discovered only on autopsy.

Key words: brain metastases, brain neoplasms-secondary; primary tumor detection, lung neoplasms-radiography, brain CT;

Introduction

Presently, in our conditions CT is of decisive importance for the diagnosis of brain invasive processes. As evident from CT scans, corticosteroids effectively eliminate brain edema surrounding the tumor. In search of the origin of a suspected solitary brain metastasis, apart from directed oncological anamnesis and clinical examination, X-ray of the lung is considered by far the most important diagnostic procedure. In the presented case of a patient with solitary brain metastasis, the origin was later on found in the lung, whereas the changes evident on brain CT were obscured by the affected cerebral vascular system.

Case report

A 71-year old female patient, smoker of many years, was admitted to the Medical Department because of a few-days lasting dysphasia and paresis of the right facial nerve, and a few month history of rheumatoid pains in the hand joints. X-ray of the lung was unsuspecting (Figure 1). The findings of Doppler US examination of the neck arteries were within normal limits. The eyeground showed evidence of grade II hypertension. During the investigation period the patients deteriorating neurologic condition manifested itself with paresis of the right hand, pronounced disorders of speech and writing, and right-side positive Babinski test. Brain CT (Figure 2) showed a 2 cm large tumor formation in the left temporal region with circular uptake of the contrast medium, and edema of the left cerebral hemisphere. The finding indicated a strong probability of metastatic spread.

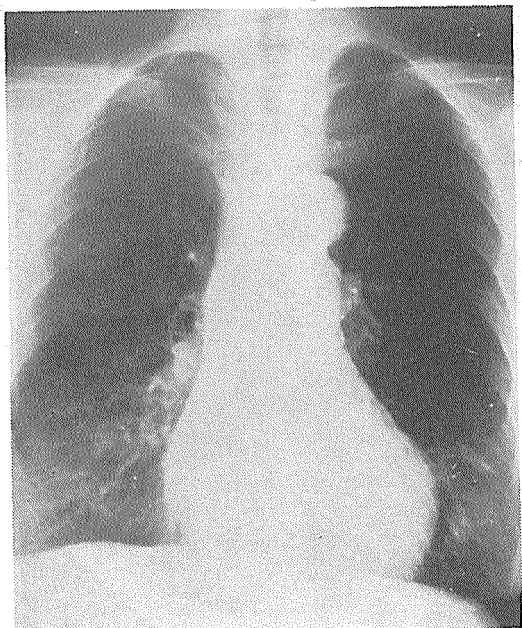


Figure 1. Lung X-ray in January 1991.

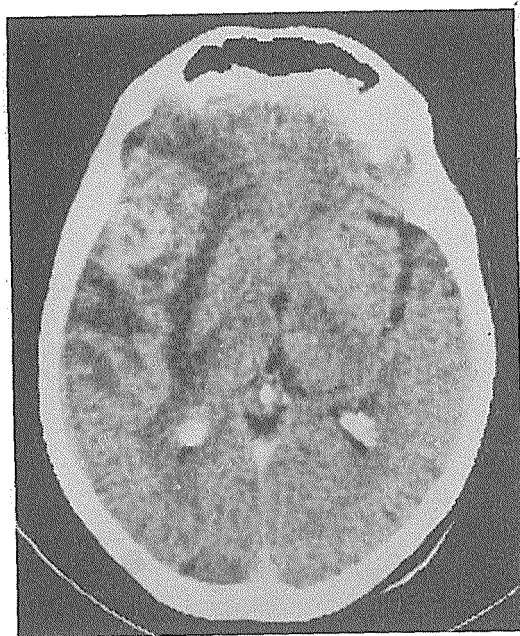


Figure 2. Brain CT in January 1991.

Based on the results of diagnostic procedures, the patient received Dexamethason treatment and had X-ray of the lung taken in the lateral view. The radiogram (Figure 3) imaged an infiltrate in the right lower lobe. On bronchoscopy, there was no direct evidence of tumor, whereas transbronchial biopsy proved the presence of poorly differentiated adenocarcinoma.

The patient's brain was irradiated on telecobalt with TD 3.000 cGy with two opposite fields, in daily fractions of 300 cGy delivered to the whole brain. Dexamethason treatment given in 4 mg injections was maintained throughout the duration of radiotherapy and was ceased on its completion. The treatment resulted in a complete regression of brain symptoms, which lasted 11 months. During that time the lung findings remained unchanged: there was no clinical evidence of pulmonary tumor, and radiograms did not differ from the previously taken images.

After 11 months, the patient's condition suddenly worsened: again dysphasia, right-sided

hemiparesis, sphincteral disorders and psychoorganic alterations were noted. Dexamethason treatment was ineffective. X-ray of the lung remained unchanged. Follow-up CT of the brain (Figure 4) showed practically identical tumor lesion in the left temporal region, more distinct changes of the white matter accompanied by enlarged ventricles. The patient died a few days later with the signs of pulmonary edema.

Autopsy revealed a primary pulmonary adenocarcinoma, and its metastasis in the brain, and thrombosis of the left internal carotid artery associated with the signs of acute infarction in the region of the middle cerebral artery.

Discussion

The presented case is interesting so from the point of primary tumor detection as well as with reference to the evaluation of changes evidenced on brain CT.

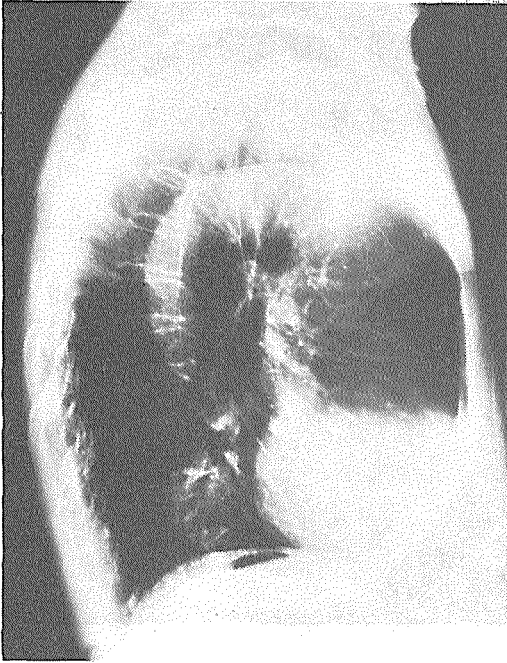


Figure 3. Lateral lung X-ray in January 1991.

According to foreign^{1,2,3,4,5} and our own experience⁶, brain metastases of unknown origin are most frequently associated with primary tumors of the lung. This turned out to be the case in 40 of 78 such patients in our series. Search for possible primary tumor in the lung requires X-ray imaging in P-A and lateral view, considering that smaller tumors may be hidden behind the heart, mediastinum or hilus and can thus be clearly differentiated in the lateral view only – the case of our patient. This is particularly important in bedridden patients who undergo radiography in lying position using A-P view; in such cases the mediastinum is flattened and the diaphragm lifted as a result of lying, which renders the assessment of possible tumorous changes even less reliable.

The most frequently seen CT changes associated with brain metastases are as follows: relatively small lesions, well stained with contrast medium, and surrounded by considerable ede-

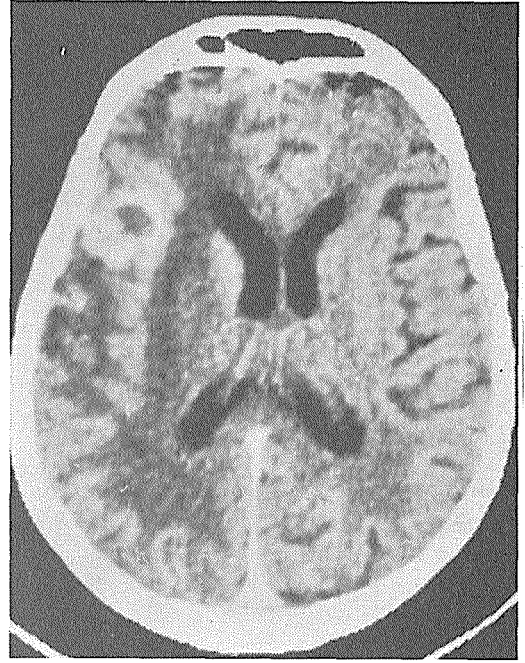


Figure 4. Brain CT in February 1992.

ma. A marked regression or complete disappearance of the edema after corticosteroid treatment is noted. Therapy with sufficiently high doses or radiation may in due time result in atrophy of the brain and cerebral ventricle enlargement, whereas further high doses of irradiation cause demyelination. Infarction is associated with similar changes of the white matter as seen in edema, however, these should correspond to the orifice of the affected artery. In our case, the changes of the white matter of the brain appeared as a consequence of tumor, irradiation and infarction of the left middle cerebral artery. Doppler US examination, which could reliably detect thrombosis of the internal carotid artery, was not repeated. It is quite evident, however, that repeated irradiation of the brain would not improve the patient's condition.

References

1. Abdel-Dayem HM, El-Shirbiny AM. Excision of solitary brain metastases: Effect on survival. *J Surg Oncol* 1982; **19**:93-7.

2. Haar F, Patterson RH. Surgery for metastatic intracranial neoplasm. *Cancer* 1972; **30**:1241-5.
3. Desoretz DE, Blitzer PH, Russel AH, Wang CC. Management of solitary metastasis to the brain: The role of elective brain irradiation following complete surgical resection. *Int J Radiat Oncol Biol Phys* 1980; **6**:1727-30.
4. White KT, Fleming TR, Laws ER. Single metastasis to the brain: Surgical treatment in 122 consecutive patients. *Mayo Clin Proc* 1981; **56**:424-8.
5. Winston KR, Walsh JW, Fischer EG. Results of operative treatment of intracranial metastatic tumors. *Cancer* 1980; **45**:2639-45.
6. Debevec M. Management of patients with brain metastases of unknown origin. *Neoplasma* 1990; **37**:601-6.