

## IDENTIFICATION OF ENLARGED CONAL ARTERY IN TETRALOGY OF FALLOT WITH SECTOR SCAN ECHOCARDIOGRAPHY

Robida A, Bricelj V

**Abstract** — In a 9-month-old boy with tetralogy of Fallot, prominent conal branch of the right coronary artery traversing the right ventricular outflow tract was visualized with sector scan echocardiography. Angiography in the aortic root confirmed the echocardiographic diagnosis. The advantage of noninvasive diagnosis of these anomalies is in postponing angiocardiography and surgery in cases of tetralogy of Fallot when major branch of the coronary artery crosses the right ventricular outflow tract. An alternative palliative operation may be necessary in such patients.

UDC: 616.124.6-007.253-073:534-8

**Key words:** tetralogy of Fallot, coronary vessel anomalies, echocardiography

### Case report

Radiol lugosl 1989; 23: 365—7

**Introduction** — In 5—9% of patients with tetralogy of Fallot, anterior descending coronary artery or another major branch crosses the right ventricular outflow tract (1, 2). When total correction is planned, the right ventricular outflow tract or transannular patch must be frequently used especially in infants. The anomalous artery can be severed at the time of right ventricular outflow tract incision and fatalities may occur. Thus preoperative delineation of coronary arteries is essential. Routinely employed aortic root angiography with a venous catheter passed through ventricular septal defect, or if this fails, with a retrograde catheter usually satisfactorily shows the coronary arteries.

Sector scan echocardiography has been used to assess the coronary arteries in transposition of great arteries (3).

In this report we describe the sector scan echocardiographic imaging of prominent conal artery branch of the right coronary artery crossing the right ventricular outflow tract in tetralogy of Fallot.

**Case report** — A 9-month-old boy with diagnosis of tetralogy of Fallot was presented to us at the age of 4 months with the episodes of cyanotic spells. At that time he was started on pro-

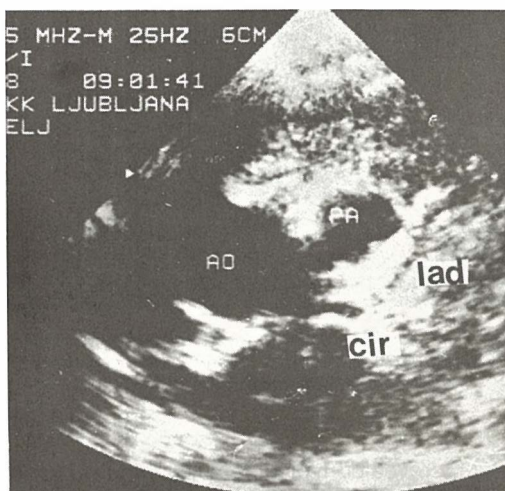


Fig. 1a — Short axis parasternal view of the left anterior descending coronary artery (lad) and circumflex branch of the left coronary artery (cir). AO = aorta, PA = pulmonary artery.

pranolol and received the transfusion of packed red cells because of anemia.

Cyanotic spells reappeared a few days before his second admission. Sector scan echocardi-

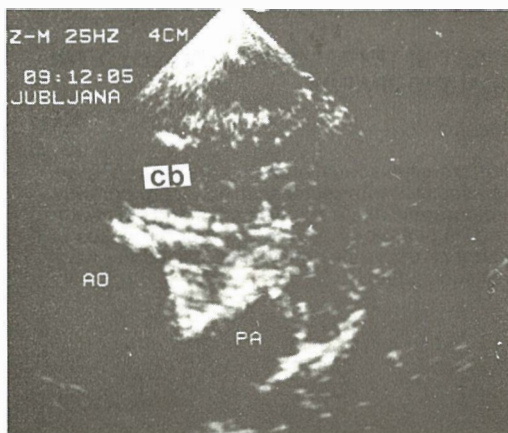


Fig. 1b — Short axis parasternal view of the conal branch (cb) of the right coronary artery crossing the right ventricular outflow tract. AO=aorta, PA=pulmonary artery.

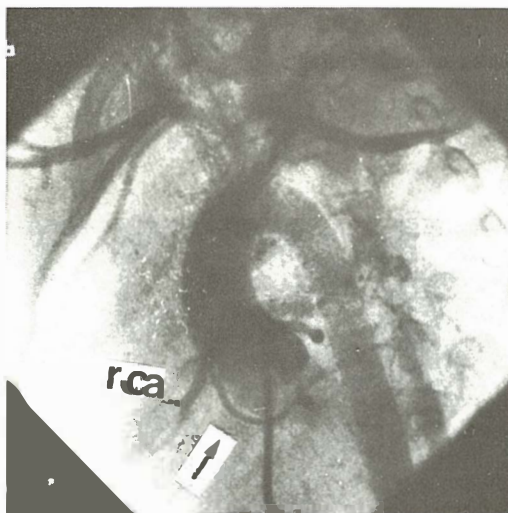


Fig. 2 — Aortic root angiography showing the conal branch (arrow) of the right coronary artery (rca) which crosses the right ventricular outflow tract.

graphy revealed typical features of tetralogy of Fallot with pronounced infundibular stenosis. Special attention was paid to the examination of the coronary arteries. We used 5 MHz medium focus transducer from high left parasternal short axis view just above the aortic valve (1). To see the left coronary artery the transducer was oriented inferiorly so that the pulmonary valve annulus was shown on cross section. Anticlockwise rotation of the transducer revealed prominent conal branch of the right coronary artery (Fig. 1

a, b). Cardiac catheterization and angiocardiography confirmed echocardiographic diagnosis of tetralogy of Fallot. Injection of the contrast medium into the aortic root in left anterior oblique projection of 45 degrees and cranial angulation of 20 degrees showed the right coronary artery and the conal branch crossing the right ventricular outflow tract (Fig. 2).

**Discussion** — Recent report on the echocardiographic examination of the anomalies of the coronary arteries in tetralogy of Fallot has identified coronary arteries in 78 % of studied children. Major obstacles for adequate imaging of coronary arteries in this defect have been poor penetration of ultrasound beam in large patients, concomitant pulmonary disease with persistent overlaying of lung tissue, and pulmonary artery atresia with severe hypoplasia of the right ventricular outflow tract. The anomalies have been found in 9 of 29 studied children.

Only in one patient a small conal branch has been visualized. It has not been considered abnormal (4). However, conal branch of the right coronary artery in tetralogy of Fallot tends to be long and swings lower over the right ventricular outflow tract instead of being short and high as is the case in normal situation. The enlarged conal artery is the response to right ventricular hypertrophy. It may render right ventriculotomy undesirable (1, 5). Surgeon can usually identify anomalies of the coronary arteries during surgery but sometimes these may be obscured by adhesions of previous operations or may run intramurally.

Thus the advantage of sector scan echocardiographic examination of the coronary arteries is in postponing the invasive investigation and surgery in cases of tetralogy of Fallot where major coronary artery crosses the right ventricular outflow tract. An alternative palliative operation may be indicated in such patients.

#### Povzetek

#### PRIKAZ POVEČANE KONUSNE ARTERIJE PRI TETRALOGIJI FALLOT Z DVODIMENZIONALNO EHOKARDIOGRAFIJO

Pri 9 mesečnem dečku s tetralogijo Fallot sva prikazala povečano konusno arterijo, ki je prečkala iztočni trakt desnega prekata z dvodimenzionalno ehokardiografijo. Diagnozo sva potrdila z angiografijo v aortni koren. Prednost neinvazivne ehokardiografske diagnostike prikaza koronarnih arterij je v preložitvi invazivne diagnostike in kirurškega posega pri bolnikih s tetralogijo Fallot, kjer večja koronarna arterija prečka iztočni trakt desnega prekata. Včasih je pri teh pacientih potrebno napraviti alternativno paliativno operacijo.

### References

1. White I R, Frech R S, Castaneda A, Amplatz K. The nature and significance of anomalous coronary arteries in tetralogy of Fallot. *Am J Roentgenol Rad Therapy Nuclear Med* 1972; 114: 350—4.

2. Fellows K E, Smith J, Keane F. Preoperative angiography in infants with tetralogy of Fallot. *Am J Cardiol* 1981; 47: 1279—85.

3. Pasquini L, Sanders S P, Parness I A, Olan S D. Diagnosis of coronary artery anatomy by two-dimensional echocardiography in patients with transposition of the great arteries. *Circulation* 1987; 75: 557—64.

4. Berry J M, Einzig S, Krabill K A, Bass J L. Evaluation of coronary artery anatomy in patients with tetralogy of Fallot by two-dimensional echocardiography. *Circulation* 1988; 78: 149—56.

5. Hurwitz R A, Smith W, King H, Girod G A, Caldwell R L. Tetralogy of Fallot with abnormal coronary artery: 1967—1977. *J Thorac Cardiovasc Surg* 1980; 80: 129—34.

Author's address: Robida Andrej M. D., University Clinical Center Ljubljana, Zaloška 2, 61000 Ljubljana.

## 27th Congress of the European Society of Paediatric Radiology

The European Society of Paediatric Radiology is holding its 27th Congress, May 14—19, 1990, in Munich, Germany. The meeting will have a well balanced scientific programme covering all aspects of paediatric radiology, state-of-the-art techniques in diagnostic and interventional imaging, quality assurance and professional practice. Special programmes include a »two days before« industrial visit to Siemens (May 11) and Philips (May 12) with subsequent city sightseeing tour of Erlangen-Nürnberg and Salzburg, a postgraduate course (May 14 & 15) based on the theme »Rational use of diagnostic imaging in paediatrics«, an international Symposium on »The Status of paediatric radiology in Europe«. Accompanying programmes include a companion's conference (May 16) on »Bavaria — History, art and modern life« and a post congress tour of the cultural and scenic highlights of Bavaria (May 19 & 20).

**Deadlines:** Papers and posters, Dec. 31, 1989; registration, March 1, 1990.

**Fees** (tentative): Postgraduate course: DM 250; Congress: Non-Members — regular DM 400 / reduced (students and trainees) DM 250; members of the ESPR — regular DM 350 / reduced DM 200.

**Information:** Dr. H. Fendel, Univ.-Kinderklinik, Röntgenabteilung, Lindwurmstr. 4, D-8000 München 2, Federal Republic of Germany, Fax. (89) 5160-5388, Tel. (89) 5160-3161.