

ONKOLOŠKI INŠTITUT, LJUBLJANA

S-100 PROTEIN IN SYNOVIAL SARCOMA

Golouh R, Bračko M, Vuzevski V, Van der Heul RO

We read with great interest the study on pathologic distinction between glandular peripheral nerve sheath tumor (GPNST) and biphasic synovial sarcoma with glands (BSSWG) by Drs. Christensen, Strong, Bains and Woodruff (1). Because both, GPNST and BSSWG, showed an admixture of spindle cells and epithelium - like cells that are in gland-like arrangement they may be mistaken for each other histologically. In this paper specific histological and immunohistochemical differences between both sarcomas were identified. Major immunohistochemical features included neuroendocrine differentiation and reactivity for S-100 protein and CEA seen in nerve sheath tumors, and the positivity for EMA of spindle cells of the biphasic synovial sarcomas.

Because S-100 protein reactivity seems to be one of key factors in differential diagnosis between both lesions, we would like to add an interesting observation showing an exception of that general rule.

We have recently studied the frequency and distribution pattern of immunohistochemical reactivity in a series of 36 cases of synovial sarcoma. Immunohistochemical studies performed on representative paraffin blocks from all cases disclosed reactivity for S-100 protein in one case of BSSWG. The patient was a 24-year-old female, who presented with a lump in soft tissue of her back of 3 months duration. After excision, a biphasic synovial sarcoma was diagnosed. The tumor showed 50% glandularity, relatively low mitotic rate (3 mitoses/10 HPF) and less than 10% necrosis. Postoperatively, the patient received radiotherapy (5000 cGy) and PlatinoI intravenously. After 11 months she developed lung metastases and was treated by radiotherapy again. Twenty-three months after surgery she is alive and without symptoms.

Staining for S-100 protein (Z311, polyclonal, DAKOPATTS) on primary tumor was positive in glandular elements only, without any evidence of reactivity in the spindle cell component (Fig. 1). The staining was intense and diffuse, decorating cytoplasm as well as nuclei. Other studies performed on this tumor showed glandular elements and plump spindle cells to be immunoreactive for keratin (Z622, polyclonal, DAKOPATTS) and EMA (M613 monoclonal, DAKOPATTS). None of epithelial or spindle cells demonstrated CEA (Parlam VI, monoclonal, Organon Technicon) positivity. In contrast, staining

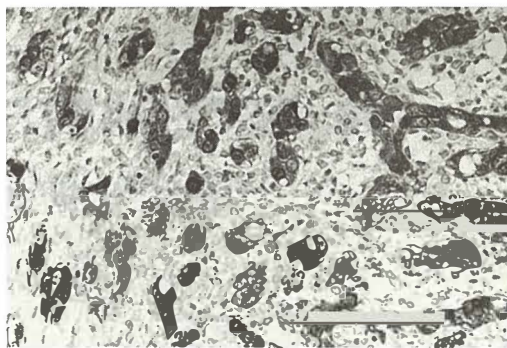


Fig. 1 — Biphasic synovial sarcoma, showing glandular cells staining with polyclonal antibody to S-100 protein.

for vimentin (DPC, monoclonal, Laboratorium Service Benelux) was present in spindle and some glandular cells.

In contrast with GPNST, where S-100 protein positivity is restricted to the spindle cell component, in our case the positivity was present in glandular component only, thus ruling out the possibility of missed diagnosis of a malignant schwannoma. If the cross reactivity to the epitopes, not related to S-100 protein, could be ruled out, this would be the first case of synovial sarcoma cosynthesizing keratin, EMA and S-100 protein in its »epithelial« cells. This would not be an unexpected finding considering recent immunohistochemical surveys that have revealed widespread distribution of S-100 protein in different normal and neoplastic epithelial tissues including sweat glands of the skin, salivary gland neoplasms (2), breast epithelium and breast carcinomas (3).

Our findings indicate that biphasic synovial sarcoma should be included in the list of tumors displaying S-100 protein positivity and that the discriminatory value of this marker in diagnostic immunohistochemistry needs to be continuously reappraised.

References

1. Christensen WN, Strong EW, Bains MS, Woodruff JM. Neuroendocrine differentiation in the glandular peripheral nerve sheath tumor. Pathologic distinction from biphasic synovial sarcoma with glands. *Am J Surg Pathol* 1988; 12: 417—26.
2. Crocker J, Jenkins R, Campbell J, Fuggle WJ, Shah VM. Immunohistochemical demonstration of S-100 protein in salivary gland neoplasms. *J Pathol* 1985; 146: 115—21.
3. Dwarakanath S, Lee AKC, Delellis RA, Silverman ML, Frasca L, Wolfe HJ. S-100 protein positivity in breast carcinomas: a potential pitfall in diagnostic immunohistochemistry. *Hum Pathol* 1987; 18:1144—8.

Author's address: prof. R. Golouh, M. D., dr. sci., The institute of Oncology, Zaloška 2, 61000 Ljubljana, Yugoslavia.