

ADENOCARCINOMA OF THE COLON FOLLOWING URETEROSIGMOIDOSTOMY REPORT OF A NEW CASE WITH AUTOPSY FINDINGS

Lamovec J.

Abstract — A new case of an autopsied 40-year old patient with adenocarcinoma arising at the site of ureterosigmoidostomy performed 26 years earlier for bladder extrophy is reported. It was also associated with a benign polyp of the rectum distally to the uninvolved right ureteric outlet. The possible mechanisms including the recent findings of abnormal mucin secretion in the colonic mucosa in the regions of urine diversion are briefly discussed.

UDC: 616.348-006.66

Key words: colonic neoplasms, adenocarcinoma, ureterosigmoidostomy

Case report

Radiol lugosl 1989; 23: 59—62.

Introduction — Ureterosigmoidostomy used to be the procedure of choice for urinary diversion. It has been largely substituted by ileal conduit introduced by Bricker (5) and its well known complications, i.e. hyperchloremic acidosis, chronic renal infections and urinary calculi were thus avoided or reduced although the long-term results of this operation are far from ideal (21), and other operative procedures, e.g. colon conduit without reflux are gaining increased popularity (2). However, one serious and very late sequel may still appear in patients who had ureterosigmoidostomy performed many years previously when the procedure was popular, namely neoplastic growth at the site of anastomosis.

The first to describe the occurrence of colonic neoplasm was Hammer in 1929 (10). Since then over 50 such cases were described in English literature, most of them being carcinomas and benign polyps in the minority of cases (1, 3, 4, 7, 8, 11, 12, 14—20, 22—24).

This is a new report of an adenocarcinoma arising in the colonic mucosa at the site of ureterosigmoidostomy performed for extrophy of the urinary bladder 27 years before.

Case report — A 40-year-old man was referred to our institution from another hospital where

he had a palliative transversosigmoidostomy performed because of inoperable tumor in the upper part of sigmoid colon involving the right retroperitoneum and bilateral paraaortic lymph nodes. His main complaints for the last two years were inappetence, periodic obstipation and colics in the left lower abdomen. When he was 14 years old he had had a ureterosigmoidostomy done because of bladder extrophy. Since then he was in good health until for the past two years, except for the bout of acute alcoholic hepatitis 4 years ago and acute appendicitis 15 years ago.

On physical examination, no mass was palpated in his abdomen, however, palpation was painful in the region of the left mesogastrium along the postoperative scar. No other abnormalities were found except for the still persistent epispadia and poorly corrected bladder extrophy with vesico-cutaneous fistula. Digital rectal examination was negative. On rectoscopy a 0.7 cm sessile polyp was found on the anterior rectal wall 17 cm above the anus, few centimeters distally to the right ureteric outlet. Barium enema examination showed oval filling defect in the region of the implanted left ureter in the proximal sigmoid colon with enema barely passing stenotic area but freely filling transverse colon through transversosigmoidostomy. Ultra-

sound of the abdomen showed dilated calices, pelvis and ureter of the left kidney with shortening of the latter. Chest X-ray and liver scan failed to show any evidence of metastases. Renography showed afunctional left kidney.

The patient was palliatively irradiated to the left meso- and hypogastric region (total dose 4000 cGy); his condition improved and abdominal pains completely ceased. However, he was readmitted two months later with bilateral upper abdominal pain, was irradiated again, this time to bilateral paraaortic lymph nodes (total dose 2700 cGy) but his condition deteriorated, and he died 5 months after first admission to our institution.

At autopsy, the patient appeared cachectic. The distal part of the descending colon and the proximal part of the sigmoid colon were »buried« in the dense fibrous tissue in the left retroperitoneum. The lumen of the intestine in this area was replaced by an irregular cavity without identifiable muscular wall, its wall consisted of dense fibrous tissue and necrotic white-yellow neoplastic tissue on the luminal surface. A 7 cm long markedly dilated left ureter was implanted into this wall with complete obstruction of the outlet and extreme dilatation of the excretory system of the left kidney with compressive atrophy of its parenchyma. The outlets of the described cavity were narrowed by fibrotic and/or neoplastic tissue and led into slightly dilated descending and sigmoid colon on the opposite sides. The obstruction was by-passed by sigmoido-transversoanastomosis. The right ureter which was implanted into the sigmoid colon distally to the left one was slightly dilated with widely patent outlet (Fig. 1). No metastatic colic

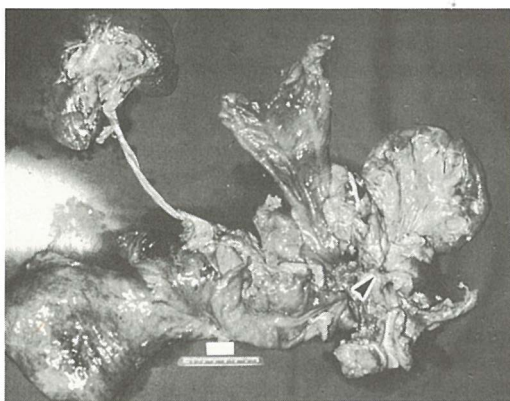


Fig. 1 — Gross specimen showing contracted and dilated left ureter with neoplastic infiltration and fibrosis at the site of ureterosigmoidostomy.

lymph nodes were found. Paraaortic tissue was markedly fibrotic with no identifiable lymph nodes. No distant metastases were seen. Other pertinent autopsy findings included bilateral bronchopneumonia, pulmonary congestion and edema. The cause of death appeared to be a complex one: cachexia, dehydration, bronchopneumonia, and possible action of multiple pain-killing drugs on patient's CNS may have contributed to it.

Histology of the site of the left ureterosigmoidostomy showed infiltrating moderately differentiated adenocarcinoma of the colonic type involving the superficial portion of the fibrosed intestinal wall (Fig. 2). Dense hyalinized fibrous tissue

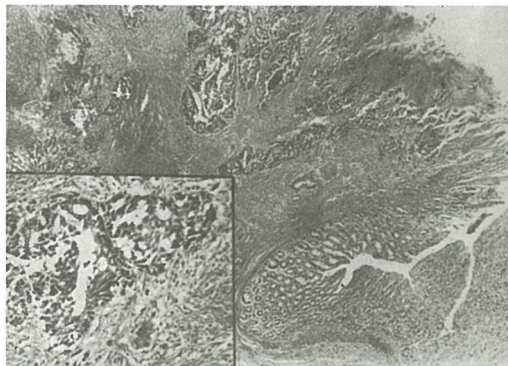


Fig. 2 — Adenocarcinoma infiltrating the ureterosigmoidostomy with uninvolved colonic mucosa in the right lower corner of the picture (HE \times 10). Inset shows moderately differentiated adenocarcinoma (HE \times 40).

of the deeper part of the wall which also massively involved the left retroperitoneum showed no microscopic foci of carcinoma. Mucosal lining of the ureteral part of the anastomosis was necrotic, deeper layers fibrotic, with no carcinomatous growth. The right ureterosigmoidostomy was microscopically unremarkable. The fibrotic paraaortic tissue had only few completely hyalinized microscopic lymph nodes without metastases.

Other relevant histologic findings included chronic pyelonephritis with nephrosclerosis on the left side and chronic pyelonephritis on the right side.

In summary, the patient had a residual infiltrating adenocarcinoma of the colon at the site of left ureterosigmoidostomy without lymph node metastases and severe postirradiative retroperitoneal fibrosis.

Discussion — The occurrence of large bowel neoplasia following ureterosigmoidostomy has

been reported on several occasions (1, 3, 4, 7, 8, 10—12, 14—20, 22—24). The neoplasms arising in this location were either benign polyps or carcinomas, predominantly adenocarcinomas. There were over 30 cases of carcinoma reported to date (1, 15). Most of them were seen in patients who were operated upon for nonmalignant condition, minority of these patients had the ureterosigmoidostomy performed after cystectomy for bladder carcinoma (22). The median age at the outset of the colonic carcinoma in the former group was 33 years and in the latter group 63 years respectively (20, 22). The latent period from ureterosigmoidostomy and the development of colonic neoplasm ranged from 7 to 46 years in patients operated upon for nonmalignant condition but was substantially shorter in the bladder carcinoma group (22).

It is thought that the association of colonic neoplasm and ureterosigmoidostomy is unlikely to be fortuitous (9, 24). The carcinoma of the colon occurring before the age of 40 is rare (25, 26), while most cases of carcinomas at ureterosigmoidostomy site occurred before this age (14, 15, 20, 22—24). It was calculated that the incidence of colonic neoplasia in patients with ureterosigmoidostomy to be 500 times greater than normally expected for this age group (24). However, this number was estimated to be much lower by other authors and put into the range of 80—100 (23). The etiology of the neoplasms arising at ureterosigmoidostomy site is as yet unknown. The fact that most of the tumors are colonic adenocarcinomas speaks in favor of causative agent acting upon colonic mucosa. The experimental data suggest that a fecal stream is necessary for carcinogenesis, and that local activation of fecal carcinogens by diverted urine, or of urinary carcinogens by fecal bacteria may be the cause of cancer after ureterosigmoidostomy (9). On the other hand, there was a report of adenocarcinoma complicating colon conduit 26 years after the diversion which contradicts the above hypothesis, since there had never been any mixture of urine and feces in the conduit in the reported case (6). It has been recently reported that the pattern of mucin secretion in colonic mucosa is definitely abnormal in patients who have undergone urinary diversion (13). If this is an indicator of preneoplasia remains to be established.

It is of interest to note that the present case showed also a benign polyp of the rectum in association with colonic carcinoma. They may or may have not been etiologically related. The mucosal proliferation in this polyp was only slight but unusual presence of smooth muscle

bundles was not unlike to the case described by Ali et coworkers (1), (Fig. 3).

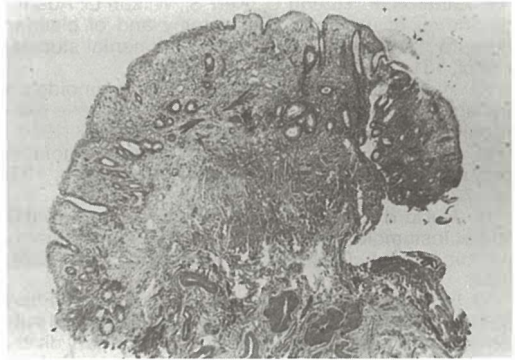

Fig. 3 — A benign polyp of the rectum. Slightly hyperplastic mucosa with proliferation of smooth muscle bundles is seen (HE \times 13).

Conclusion — This case once again shows that patients who have had ureterosigmoidostomy should be followed for the rest of their lives to discover the earliest neoplastic change in their colonic mucosa which may appear many years after the operation.

Povzetek

V članku poročam o novem obdukcijem primeru adenokarcinoma na ureterosigmoidostomi pri štiridesetletnem bolniku. Operacija je bila napravljena pred 26 leti zaradi ekstrofije sečnega mehurja. Bolnik je bil obsevan na Onkološkem Inštitutu, kjer je umrl v kaheksiji. Poleg karcinoma na ureterosigmoidostomi je bil v rektumu še manjši benigni polip. V diskusiji razpravljam o možnih mehanizmih za nastanek karcinoma na ureterosigmoidostomi, vključno o novejših odkritjih abnormalne mucinske sekrecije v črevesni sluznici na mestih urinske preusmeritve.

References

1. Ali M. H., Satti M. B., Al-Nafussi A.: Multiple benign colonic polypi at the site of ureterosigmoidostomy. *Cancer* 53: 1006—1010, 1984.
2. Althausen A. F., Hagen-Cook K., Hendren W. H. III: Nonrefluxing colon conduit: experience with 70 cases. *J. Urol.* 120: 35—40, 1978.
3. Amar A. D.: Neoplastic obstruction of the ureterosigmoid anastomosis. *J. Urol.* 86: 334—335, 1961.
4. Ansell I. D., Vellacott K. D.: Colonic polyps complicating ureterosigmoidostomy. *Histopathology* 4: 429—436, 1980.
5. Bricker E. M.: Bladder substitution after pelvic evisceration. *Surg. Clin. North Am.* 30: 1511—1521, 1950.
6. Chiang M. S., Minton J. P., Clausen K., Clatworthy H. W., Wise H. A. II: Carcinoma in a colon conduit urinary diversion. *J. Urol.* 127: 1185—1188, 1982.
7. Dunn M., Roberts J. B. M., Smith P. J. B.: Benign tumors developing at the site of ureterosigmoidostomy. *Br. J. Urol.* 51: 260—263, 1979.

8. Gillman J. C.: Adenomatous polyp of bowel following ureterocolic anastomosis. *Br. J. Urol.* 36: 264—270, 1964.
9. Gittes R. F., Ruegg C., Kerr S., Wilson L.: Adenocarcinoma of ureterosigmoidostomy and of bladder extrophy: pathophysiology and experimental studies. *J. Urol.* 131: 278 A, 1984.
10. Hammer Em. M.: Cancer du colon sigmoïde dix ans après implantation des ureters d'une vessie exstrophée. *J. Urol. Nephrol. (Paris)* 28: 260—263, 1929.
11. Haney M. J., McGarity, W. C.: Ureterosigmoidostomy and neoplasms of the colon. *Arch. Surg.* 103: 69—72, 1971.
12. Harford F. J., Fazio V. W., Epstein L. M., Hewitt C. B.: Rectosigmoid carcinoma occurring after ureterosigmoidostomy. *Dis. Colon Rectum* 27: 321—324, 1984.
13. Iannoni C., Marcheggiano A., Pallone F., Frieri G., Gallucci M., DiSilverio F., Caprilli R.: Abnormal patterns of colorectal mucin secretion after urinary diversion of different types: histochemical and lectin binding studies. *Hum. Pathol.* 17: 834—840, 1986.
14. Lasser A., Acosta A. E.: Colonic neoplasms complicating ureterosigmoidostomy. *Cancer* 35: 1218—1222, 1975.
15. Leadbetter G. W. Jr., Zickerman P., Pierce E.: Ureterosigmoidostomy and carcinoma of the colon. *J. Urol.* 121: 732—736, 1979.
16. Macgregor A. M. C.: Mucous secreting adenomatous polyp at the site of ureterosigmoidostomy. A case report and review of the literature. *Br. J. Surg.* 55: 591—594, 1968.
17. Mogg R. A.: Neoplasms at the site of ureterocolic anastomosis. *Br. J. Surg.* 64: 758—761, 1977.
18. Narayana A. S., Kelly D. G., Duff F. A.: Benign polypi at the site of uretero-rectal anastomosis. *Postgrad. Med. J.* 54: 348—350, 1978.
19. Recht K. A., Belis J. A., Kandzari S. J., Milam D. F.: Ureterosigmoidostomy followed by carcinoma of the colon. *Cancer* 44: 1538—1542, 1979.
20. Rivard J. Y., Bedard A., Dionne L.: Colonic neoplasms following ureterosigmoidostomy. *J. Urol.* 113: 781—787, 1975.
21. Schmidt J. D., Hawtrey C. E., Flocks R. H., Culp D. A.: Complications, results and problems of ileal conduit diversion. *J. Urol.* 109: 210—217, 1973.
22. Soorijaarachi G. H., Johnson R. O., Carbone P. P.: Neoplasms of the large bowel following ureterosigmoidostomy. *Arch. Surg.* 112: 1174—1177, 1977.
23. Stewart M., Macrae F. A., Williams C. B.: Neoplasia and ureterosigmoidostomy: a colonoscopic survey. *Br. J. Surg.* 69: 414—416, 1982.
24. Urdaneta L. F., Duffell D., Creevy C. D., Aust J. B.: Late development of primary carcinoma of the colon following ureterosigmoidostomy: report of three cases and literature review. *Ann. Surg.* 164: 503—513, 1966.
25. Winawer S. J.: Screening for colorectal cancer: an overview. *Cancer* 45: 1093—1098, 1980.
26. Winawer S. J., Sherlock P.: Surveillance for colorectal cancer in average-risk patients, familial high-risk groups, and patients with adenomas. *Cancer* 50: 2609—2614, 1982.

Author's address: Janez Lamovec. M. D., The Institute of Oncology, 61000 Ljubljana

○ knjigotisk ○ ofset ○ knjigoveznica

kočevski tisk
kočevje